

## Ansa pancreatica. Review of the literature

Kympouris Sotirios\*, Filippou Dimitrios, Skandalakis Panagiotis

Department of Anatomy and Surgical Anatomy, Medical School, National and Kapodestrian University of Athens, Athens, Greece

### Abstract

Ansa pancreatica is a reversed S-shaped pancreatic duct arising from the main pancreatic duct of Wirsung and ending at or near the minor duodenal papilla. Described for the first time in 1961, it is a rare anatomic variant of the pancreatic ducts system and is characterized by the absence of the accessory duct of Santorini. It probably serves as a counter measure after the accessory duct obliteration, in order to maintain sufficient pancreatic juice drainage. The literature concerning ansa pancreatica seems to be rather poor, compared to other anatomic variants and congenital anomalies of the pancreatic ducts. We tried to define the ansa pancreatica incidence among general population and highlight the possible differences between different populations, and to define its possible correlation with pancreatitis. The existing data correlate ansa pancreatica with recurrent acute pancreatitis and pancreatitis in alcoholics. Despite the lack of extended data, ansa pancreatica is a rare anatomic variant, proven to play an important role in certain clinical conditions.

### Key words

Ansa pancreatica, pancreatitis, pancreas, anatomy of pancreas, pancreatic ducts.

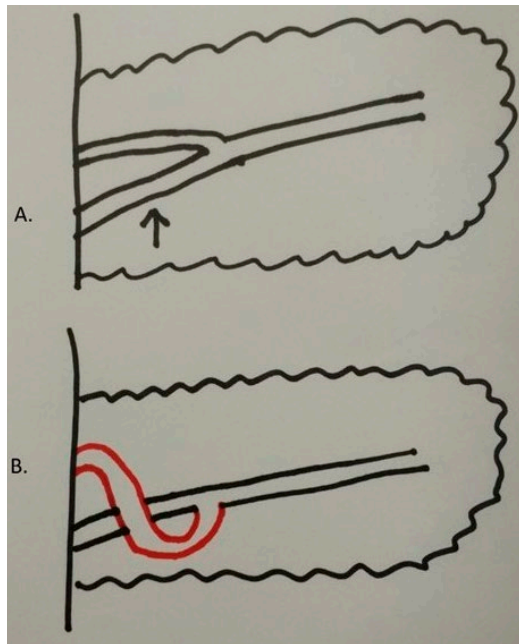
### Introduction

Various congenital anomalies and anatomic variants of the pancreas and the pancreatic duct patterns have been described in the literature (Lehman, 2000; Türkvtan et al., 2013). These conditions have been highlighted and studied, especially since magnetic resonance cholangiopancreatography (MRCP) and endoscopic retrograde cholangiopancreatography (ERCP) play a substantial role in the diagnosis, treatment and follow up of pancreaticobiliary diseases.

Developmental malformations and anatomic variants of the pancreas and the pancreatic ducts include: variations in the course of the main pancreatic duct (sigmoid, descending, loop etc.), variations of the configuration, duplication anomalies, anomalous pancreaticobiliary ductal junction, pancreas divisum (fusion related), annular pancreas (migration related), ectopic pancreatic tissue, pancreatic agenesis or hypoplasia of the dorsal pancreas or accessory pancreatic lobe (Türkvtan et al., 2013).

Ansa pancreatica (Fig. 1) is a very rare fusion related pancreatic duct variation, in which the duct of Santorini forms a reversed S shape and connects with a side branch of the duct of Wirsung (Mortele et al., 2006). It was first described by Dawson and Langman (1961) in an anatomical and radiological study of cadaveric subjects. This condition has been proposed as a potential cause of pancreatitis, especially in alcoholics (Tanaka et al., 1991, 1992).

\* Corresponding author. E-mail: sotiriskympouris@hotmail.com



**Figure 1.** (A) Common pancreatic ductal anatomy with dominant Wirsung duct (black arrow) (B) Ansa pancreatica (red duct) arising from and passing in front of the main pancreatic duct

The aim of this paper is to review the literature about the prevalence of ansa pancreatica and put emphasis on the potential clinical implications of such a rare pancreatic duct anatomic variation.

## Materials and methods

Pubmed and journals outside Pubmed were searched in the internet using ansa pancreatica as a search term. The literature found was rather poor and heterogenous, so no exclusion criteria were set, as it was tried to include as much information as possible concerning ansa pancreatica. Approximately twenty papers were found on the whole.

## Results

There are a few anatomic, radiologic and clinical studies in the literature concentrating on the pancreatic ductal patterns but only a recent one, to the author's knowledge, focuses on ansa pancreatica (Hayashi et al., 2016). The studies are based either on anatomic-cadaveric examination or MRCP-ERCP reports. In the study of Dawson and Langman (1961), where ansa pancreatica was originally described, this duct

**Table 1.** Studies reporting ansa pancreatica incidence.

Authors/Date	Subjects examined	Methods of examination	Country	Incidence of ansa pancreatica
Langman and Dawson (1961)	120	Cadaveric and radiologic	Canada	17%
Kamisawa et al. (1998)	213	ERCP	Japan	13.6%
Adibelli et al.(2016)	1158	MRCP	Turkey	1.2%
Hayashi et al. (2016)	660	MRCP	Japan	1.2%
Narayanan and Shabna C. (2017)	50	Cadaveric	India	2%
Liessi et al. (2010)	300	MRCP after secretin injection	Italy	1%

ERCP: endoscopic retrograde cholangiopacreatography  
 MRCP: magnetic resonance cholangiopacreatography

variation was found in 17% of the subjects (21/120 cases). It was an anatomic study based on fresh specimens, enhanced by the injection of a contrast medium and radiographic imaging. In 66% of the cases with ansa pancreatica, this duct was obliterated at its junction with the duodenum, despite a visible minor papilla.

Using dye injection during ERCP and interpreting dynamic images, Kamisawa et al. (1998) reported an incidence of 13.6% in 213 patients with diagnosed or suspected pancreaticobiliary disease. The incidence of an impervious minor papilla in these cases was almost 80%, even higher than reported Dawson and Langman (1961).

These reported high values of incidence of ansa pancreatica are in dispute with studies based on MRCP imaging (Table 1).

In a Turkish population based, retrospective study of 1158 MRCPs of people with suspected biliary or pancreatic disease, the ansa pancreatica incidence was found to be 1.2% (Adibelli et al., 2016). This study tried to establish the connection between pancreatic ducts variations and the modified for MRCP Cambridge classification system of chronic pancreatitis (Choueiri et al, 2010). In the results, ansa pancreatica was associated with higher score and thus, might be considered a relevant factor to the onset of chronic pancreatitis (Adibelli et al., 2016).

Another retrospective, Italian population study based on the interpretation of 300 dynamic MRCPs (before and after secretin administration) of patients with suspected or known pancreatic disease, resulted in an incidence of 1% for ansa pancreatica (3/300) (Liessi et al., 2010). A cadaveric study of the pancreatic ductal system of 50 subjects in an Indian population in 2017 revealed a 2% incidence rate of ansa pancreatica (Narayanan and Shabna, 2017).

Ansa pancreatica has also been associated, in case reports, with idiopathic acute pancreatitis (Bhasin et al., 2006), acute pancreatitis (Jarrar et al., 2013) and pancreatitis complicated with walled off pancreatic necrosis (Jagielski et al., 2017). According to Ishii et al., (1998) approximately 7% of patients with ansa pancreatica present with at least an episode of acute pancreatitis.

In 2016, the first attempt to determine the non-biased prevalence of ansa pancreatica and its correlation with pancreatitis was made, with a retrospective study based on a Japanese population (Hayashi et al., 2016). 663 community based subjects and 85 subjects with episode of acute pancreatitis (of which 18 with recurrent pancreatitis) underwent medical examination, blood tests and examination by magnetic resonance imaging-MRCP. The accessory pancreatic duct was clearly visualized in 587 case in the community group and in 73 cases in the pancreatitis group (not statistically significant difference). The ansa pancreatica incidence was 0.85% in community group subjects, 1.81% (1/55) in patients with single episode of pancreatitis and 11.1% (2/18) in patients with recurrent acute pancreatitis. In this study, a statistically significant correlation between ansa pancreatica and the onset of acute recurrent pancreatitis was established. Ansa pancreatica was also found to be more prevalent in patients with alcoholic pancreatitis, but no exact and significant correlation could be achieved.

Among all the studies found, either based on cadaveric examination, radiographic evaluation (ERCP-MRCP) or a combination of methods, no statistically significant connection was detected between ansa pancreatica and the demographic characteristics of the subjects examined.

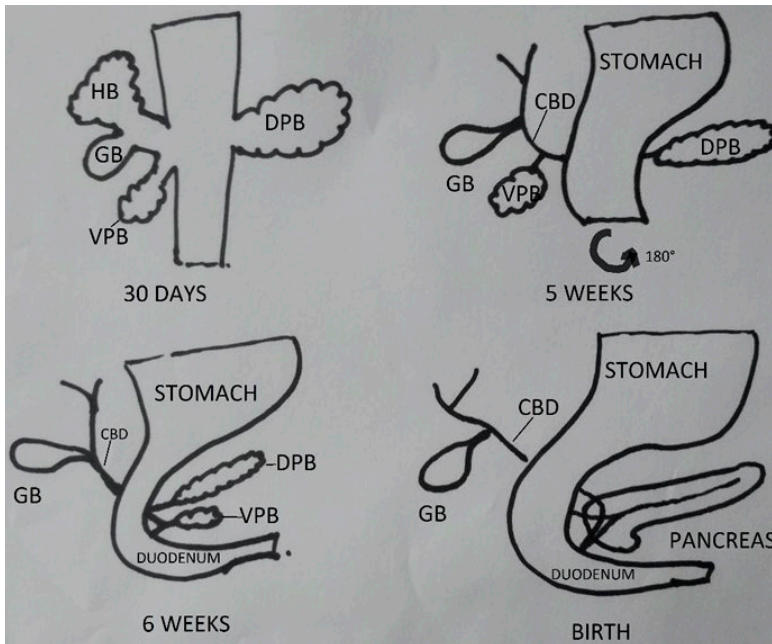
## Discussion

During fetal life, the two pancreatic buds (ventral and dorsal) along with their respective ductal systems, fuse in order to form the adult pancreas. This happens by asymmetric rotation of the duodenum and a 180 degree counterclockwise rotation of the ventral pancreatic bud. The ventral duct will fuse with the dorsal duct in the cephalic portion of the pancreas and give birth to the main pancreatic duct of Wirsung that drains at the major duodenal papilla. The majority of the pancreatic juice drainage will happen through this duct. The dorsal duct system will form the accessory pancreatic duct of Santorini, which drains into the duodenum through the minor papilla (Fig. 2) (Flati and Andrén-Sandberg, 2002).

Kamisawa et al. (1997) reported a 59% of healthy subjects with an impervious minor papilla, while Dawson and Langman (1961) reported a very high proportion (80-90%) of patent accessory ducts in fetuses and infants. Taking these data into account might lead to the conclusion that minor papilla obliteration happens later in adult life.

Ansa pancreatica is an anatomic variant of the pancreatic ductal system, characterized by a blocked minor papilla in the majority of cases (Dawson and Langman, 1961; Kamisawa et al., 1998), along with obliteration of the accessory duct at the extremity near its junction with the main pancreatic duct. The accessory duct is replaced by a hook shaped duct which serves as a communication between ventral and dorsal duct systems. This duct is formed by the proximal part of the dorsal duct, the lower branch of the ventral duct and the lower branch of the dorsal duct (Fig. 3). It ends at or near the minor papilla. It is merely a hypothesis that this procedure serves as a counterweight to the accessory duct or minor papilla obliteration, in order not to disturb pancreatic drainage.

The verification of the actual anatomy of the pancreatic ducts has been made possible since ERCP has entered everyday medical practice. MRCP serves as an equally

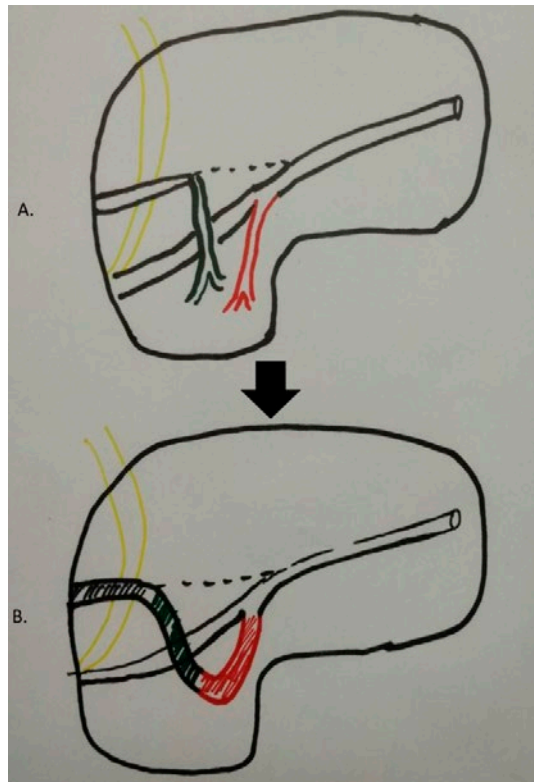


**Figure 2.** Embryologic development of the pancreas and the pancreatic ducts. HB: hepatic bud; GB: gallbladder; VPB: ventral pancreatic bud; DPB: dorsal pancreatic bud; CBD: common bile duct.

accurate tool (Bret et al., 1996; Bülow et al., 2014), with the advantage of not being invasive. However, in MRCP, ansa pancreatica is often depicted as a faint duct, compared to ERCP. This can be probably explained because of the absence of an injected radiologic agent that results into higher intraductal pressure (Tamura et al., 2006). The magnetic resonance imaging before and after the administration of secretin and the design and conduction of retrospective studies might be a good idea in order to inspect and perhaps increase MRCP's sensitivity in detecting pancreatic ductal variations, such as ansa pancreatica.

The studies found in the literature describing the incidence of ansa pancreatica are few and equivocal (Table 1). More and larger studies are needed, even in healthy individuals, in order to accurately determine ansa pancreatica incidence. Interestingly, no difference was found between men and women, however race might be important. A remarkable deviance in results was noticed between studies based on different national groups.

Throughout the literature, several case reports and studies have proposed the connection between ansa pancreatica and pancreatitis. Only recently, solid statistically significant evidence has been provided to support this correlation (Hayashi et al., 2016). Not only this, but also a relationship between alcohol, ansa pancreatica and pancreatitis has been highlighted. This study might be a great motive for new, anatomic based studies of alcoholic pancreatitis. It is also a big question, whether all individuals with pancreatitis should undergo pancreatic ductal anatomy examination



**Figure 3.** (A) Formation of ansa pancreatica, dashed line: obliterated accessory duct, (B) Ansa pancreatica formed, red component: lower branch of ventral duct, green component: lower branch of dorsal duct, black component: proximal accessory duct, yellow duct: common bile duct

with either ERCP or MRCP, as anatomic variants of pancreatic ducts are in the majority of cases asymptomatic and undiagnosed (Lehman, 2000).

It is indisputable that further studies of randomized nature are needed, in order to more precisely define the exact risk of pancreaticobiliary disease occurrence, in patients with this rare pancreatic duct anatomic variant. Physicians and especially surgeons often come across with anatomic variations that either are asymptomatic or cause pathology. Ansa pancreatica is a bold example of how aberrant anatomy could predispose to certain pathologic conditions. Firm knowledge of common and variant anatomy is a formidable tool in the hands of physicians, irrespectively to their specialty or expertise.

### Aknowledgments

The author would like to declare no conflict of interest and also thank Tzigkou-naki Aikaterini for her valuable help.

## References

- Adibelli Z.H., Adatepe M., Imamoglu C., Esen O.S., Erkan N., Yildirim M. (2016) Anatomic variations of the pancreatic duct and their relevance with the Cambridge classification system: MRCP findings of 1158 consecutive patients. *Radiol. Oncol.* 50: 370-377.
- Bhasin D.K., Rana S.S., Nanda M., Gupta R., Nagi B., Wig J.D. (2006) Ansa pancreatica type of ductal anatomy in a patient with idiopathic acute pancreatitis. *J. Pancreas (JOP)* 7: 315-320.
- Bret P.M., Reinhold C., Taourel P., Guillaud L., Atri M., Barkun A.N. (1996) Pancreas divisum: evaluation with MR cholangiopancreatography. *Radiology* 199: 99-103.
- Bülow R., Simon P., Thiel R., Thamm P., Messner P., Lerch M.M., Mayerle J., Völzke H., Hosten N., Kühn J.P. (2014) Anatomic variants of the pancreatic duct and their clinical relevance: an MR-guided study in the general population. *Eur. Radiol.* 24: 3142-3149.
- Choueiri N.E., Balci N.C., Alkaade S., Burton F.R. (2010) Advanced imaging of chronic pancreatitis. *Curr. Gastroenterol. Rep.* 12: 114-120.
- Dawson W., Langman J. (1961) An anatomical-radiological study on the pancreatic duct pattern in man. *Anat. Rec.* 139: 59-68.
- Flati G., Andrén-Sandberg A. (2002) Wirsung and Santorini: The men behind the ducts. *Pancreatology* 2: 4-11
- Hayashi T.Y., Gonoï W., Yoshikawa T., Hayashi N., Ohtomo K. (2016) Ansa pancreatica as a predisposing factor for recurrent acute pancreatitis. *World J. Gastroenterol.* 22: 8940-8948.
- Ishii H., Arai K., Fukushima M., Maruoka Y., Hoshino M., Nakamura A., Koike Y., Sakamoto N., Hanada H., Kusano M., Okamatsu, T. (1998) Fusion variations of pancreatic ducts in patients with anomalous arrangement of pancreaticobiliary ductal system. *J. Hepatobiliary Pancreat. Surg.* 5: 327-332.
- Jagielski M., Smoczyński M., Drelich-Górczna B., Adrych K. (2017) Transduodenal drainage of symptomatic walled-off pancreatic necrosis in a patient with ansapancreatica anatomic variation. *Arch. Med. Sci.* 13: 267-269.
- Jarrar M.S., Khenissi A., Ghrissi R., Hamila F., Letaief R. (2013) Ansa pancreatica: an anatomic variation and a rare cause of acute pancreatitis. *Surg. Radiol. Anat.* 35: 745-748.
- Kamisawa T., Tabata I., Tajima T., Tsushima K., Yoshida Y. (1997) Patency of the human accessory pancreatic duct as determined by dye-injection endoscopic retrograde pancreatography. *Digestion* 58: 78-82.
- Kamisawa T., Yuyang T., Egawa N., Ishiwata J., Okamoto A. (1998) Patency of the accessory pancreatic duct in relation to its course and shape: a dye-injection endoscopic retrograde pancreatography study. *Am. J. Gastroenterol.* 93: 2135-2140.
- Lehman G.A. (2000) Congenital anomalies of the pancreas. In: Sivak M.V.Jr. *Gastroenterologic Endoscopy*. 2<sup>nd</sup> ed. W.B. Saunders Company, Philadelphia. Pp. 1084-1097.
- Liessi F., Manfredi R., Liessi G., Pozzi-Mucelli R (2010) Anatomical variants of the pancreatic ducts. *Proc. European Congress of Radiology: C-0174* (12 pages); doi: 10.1594/ecr2010/C-0174.
- Mortele K.J., Rocha T.C., Streeter J.L., Taylor A.J. (2006) Multimodality imaging of pancreatic and biliary congenital anomalies. *Radiographics* 26: 715-731.

- Narayanan G., Shabna C. (2017) Variations in the duct system of the pancreas: a cadaveric study. *Int. J. Anat. Res.* 5: 4136-4143.
- Türkvatan A., Erden A., Türkoğlu M.A., Yener Ö. (2013) Congenital variants and anomalies of the pancreas and pancreatic duct: Imaging by magnetic resonance cholangiopancreatography and multidetector computed tomography. *Korean J. Radiol.* 14: 905-913.
- Tamura R., Ishibashi T., Takahashi S. (2006) Chronic pancreatitis: MRCP versus ERCP for quantitative caliber measurement and qualitative evaluation. *Radiology* 238: 920-928.
- Tanaka T., Ichiba Y., Miura Y., Itoh H., Dohi K. (1991) Variations of the pancreatic ducts as a cause of chronic alcoholic pancreatitis. *Am. J. Gastroenterol.* 86: 792-793.
- Tanaka T., Ichiba Y., Miura Y., Itoh H., Dohi K. (1992) Variations of the pancreatic ducts as a cause of chronic alcoholic pancreatitis; ansa pancreatica. *Am. J. Gastroenterol.* 87: 806.