

## Osteologic topography of the trochlear spine and fovea as landmarks to locate the superior oblique trochlea

Margherita Agliano<sup>1,\*</sup>, Daniela Franci<sup>1</sup>, Nila Volpi<sup>1</sup>, Davide Orsini<sup>2</sup>, Maddalena Messina<sup>1</sup>, Paola Lorenzoni<sup>1</sup>

<sup>1</sup> Department of Medicine, Surgery and Neurosciences, University of Siena, Italy

<sup>2</sup> University Museum System of Siena (S.I.M.U.S.), Italy

### Abstract

The position of the superior oblique tendon, attached to the orbital roof by a cartilaginous trochlea, is marked by osteologic landmarks like the trochlear spine and/or fovea, approximately located at the superomedial angle of the orbit. Aim of the study is to place the trochlea within the orbit with a series of measurements to give the surgeon detailed references of the trochlea location. For this purpose, we undertook the study of a collection of dry skulls of known sex and age to investigate bony landmarks. Measurements were taken to assess the position of the trochlear spine/fovea on a frontal plane employing a system of vertical and horizontal lines passing through known bony reference points. Measurements were also recorded between the trochlear spine/fovea and the orbital opening on one side and the anterior rim of the optic canal on the other side. The distances of the trochlear spine/fovea from the lines passing along the supraorbital notch and the frontozygomatic suture were respectively  $8.5 \pm 2.3$  mm and  $5.7 \pm 1.5$  mm. The distances of the trochlear fovea/spine from the anterior orbital opening and from the anterior rim of the optic foramen were respectively  $4.2 \pm 0.11$  and  $37.5 \pm 3.1$  mm. Only the distance from the optic canal showed sex-related differences. In conclusion, to avoid unwanted injuries of the trochlea of the superior oblique in surgery of the superomedial angle of the orbit, the surgeon should be aware of its precise position.

### Key words

Orbit, trochlear spine, trochlear fovea, superior oblique tendon, frontal sinus surgery.

### Introduction

Eye movements are generated by six striated muscles. Each muscle applies its own specific force vector to the eyeball. Four recti muscles are arranged roughly in an anteroposterior direction and originate from the orbital apex via the common tendinous ring: the medial rectus is oriented along a sagittal axis; the lateral rectus is parallel to the lateral wall of the orbit, forming a  $45^\circ$  angle with the sagittal plane; the inferior and superior recti roughly follow the orbital axis forming a  $22\text{--}23^\circ$  angle with the lateral and medial walls of the orbit (Bron et al., 2001). In contrast, the two oblique muscles insert into the sclera after approaching the eyeball in a mediolateral and front to backward direction. Whereas the inferior oblique arises from the orbital floor close to nasolacrimal canal and has a straight course, the superior oblique originates from the lesser

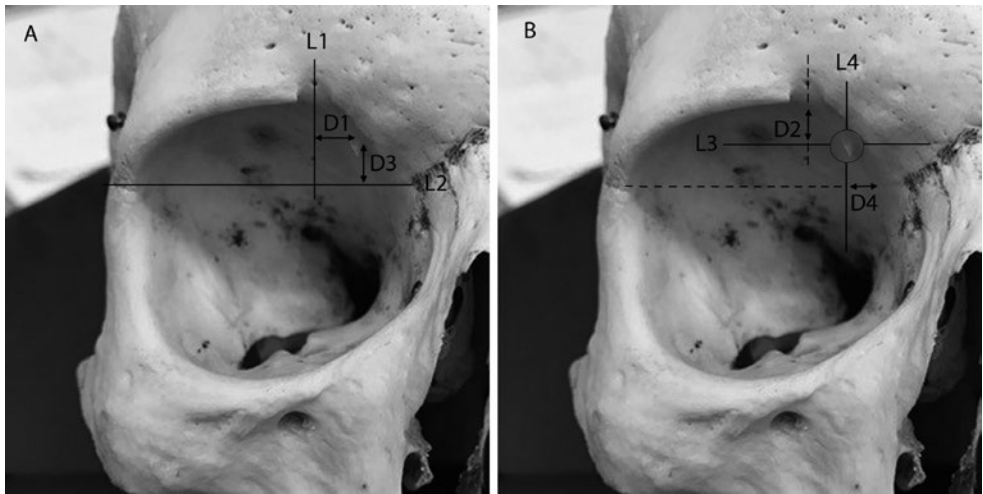
\* Corresponding author. E-mail: margherita.agliano@unisi.it

wing of the sphenoid, superomedial to the optic canal, and has a tendon with an angulated course which is necessary to reach the eyeball from the appropriate direction. The brisk change in direction of the tendon, referred to as trochlear angle, is achieved by the presence of a cartilaginous pulley which is secured to the frontal bone by two short fibrous ligaments (Bron et al., 2001). The position of the pulley is marked on the frontal bone by a three to five mm-large shallow depression referred to as the trochlear fovea (Lang, 2012). Sometimes, a bony spicula, the trochlear spine, arises from the fovea. Trochlear fovea and spine are usually described as anatomical features of the anteromedial part of the orbital roof. They are located about at the superomedial angle of the orbit, four to five millimetres behind the orbital opening (Lang, 2012). Knowledge of the precise location of the trochlear fovea/spine is important as injury of the pulley and diplopia are possible complications in frontal sinus surgery (Graham, 2016; Bartley et al., 2012). In addition, the pulley of the superior oblique is encountered, and should be properly handled, in the superior lid crease approach to the anterior skull base (Gassner et al., 2016). Unfortunately, morphometric investigations studying the exact topography of the trochlear fovea/spine are lacking. In spite of their importance, in fact, trochlear fovea and spine are frequently overlooked in studies concerning orbital osteology (McQueen et al., 1995). With the purpose of providing the otolaryngologist and the orbital surgeon with some useful reference measurements, this report is aimed to fill a gap of knowledge as far as the anatomic incidence and topography of the trochlear fovea/spine are concerned. For this purpose, we analysed a collection of dry skulls in order to measure their distance from reliable bony landmarks as well as to ascertain their anatomical frequency, sex- and age-related prevalence.

## Materials and methods

We examined 64 dry adult human skulls of known age and sex housed at the Anatomical Museum of the University of Siena. Skulls were collected at the end of the 19th century and came from the Tuscany countryside in a historical time when immigration was an exceptional event. It is therefore a reasonable assumption to consider the skulls a collections of samples of the same ethnic derivation. On the whole we could analyze 125 orbits as three orbits were spoiled and could not be used for our purposes.

Skulls were examined to seek for the trochlear fovea/spine. In order to define their exact topography a series of horizontal and vertical lines were drawn: L1 was a vertical line passing through the center of the supraorbital notch, L2 a horizontal line passing through the frontozygomatic suture, L3 and L4 were respectively a transverse and a vertical line passing through the base/center of the trochlear fovea/spine. Taking advantage of these lines, several measurements were taken to place the trochlear fovea/spine on a frontal plane only when they were evident (Fig. 1): D1 and D3 were the distances measured along L3 and L4 between the base of the spine/center of the fovea and L1 and L2 respectively, D2 was the distance between L3 and the orbital roof measured along L1, D4 was the distance between L4 and the medial wall of the orbit measured along L2. In order to place the trochlear fovea/spine also on a sagittal plane two additional measurements were taken: D5, from the base/center of the trochlear spine/fovea and the anterior orbital opening (i.e. the medial border of the



**Figure 1.** Distances measured to define the position of the trochlea on a frontal plane. **A)** Two lines were drawn passing through two well-known anatomic landmarks. A vertical line passed through the supraorbital notch (L1); a horizontal line was at the level of the frontozygomatic suture (L2). D1 is the distance of the trochlear fovea/spine from L1; D3 is the distance of the trochlear fovea/spine from L2. **B)** A second set of measures was taken. This time two orthogonal lines (L3 and L4) intercepted the trochlear fovea/spine. D2 is the distance between L3 and the orbital roof measured along L1; D4 is the distance between L4 and the medial wall of the orbit measured along L2.

anterior orbital opening assumed as the line that joins the superior rim of the opening and the posterior lacrimal crest), and D6, from the base/center of the trochlear spine/fovea and the anterior rim of the optic canal. Whereas D6 was measured with a flexible wire, D1-D5 were taken employing a divider caliper. All measures were taken in millimeters and fractions of millimeters shorter than 0.5 mm were not taken into considerations.

Statistical analysis (Student's *t*-test) was carried out to verify if the presence of the trochlear fovea/spine could be referred to a population with an average age significantly different from the average age of the skull population. Student's *t*-test was also employed to verify if the position of the trochlear fovea/spine differed between females and males. Z-test was used to check if there were significant differences between the incidence of the trochlear fovea/spine in male and female skulls. Statistical tests were considered significant with  $p < 0.05$ .

## Results

### Anatomical frequency of the trochlear fovea and spine

A distinct bony landmark (either trochlear spine or fovea) signalling the position of the cartilaginous pulley was visible in 97 orbits out of 124 (78.2% of cases). The trochlear fovea could be observed in 91 orbits out of 124 (73.39% of cases). A troch-

lear spine was visible in 19 orbits (15.32% of cases). Overall at least one spine was detectable in 12 skulls (18.75% of all skulls). It was bilateral in 7 skulls (10.93%) and unilateral in 5 (7.81% of all skulls). In the latter case spines were right-sided in 4 cases and left-sided in just one orbit. In 13 cases out of 19 the trochlear spine raised from a visible fovea. The presence of the trochlear spine did not show any sex-related preference as its anatomic frequency was 14.54% in female orbits (8 cases out of 55 orbits) and 15.94% in male orbits (11 cases out of 69 orbits), with no detectable statistically significant difference. The same consideration applied to the trochlear fovea whose anatomic incidence did not show any statistically significant difference between sexes (69.1% in female orbits and 66.67% in male orbits). To verify if the presence of the trochlear spine could be age-related we compared the average age of orbits with or without the trochlear spine. Orbits provided with the trochlear spine were on average  $57.6 \pm 15.8$  years old whereas those without were  $51.7 \pm 20.6$  years old. Such difference was not statistically significant. No statistically significant difference could be observed also when comparing the average age of orbits showing the trochlear fovea and those without it (respectively  $53 \pm 14.14$  and  $52.68 \pm 24.75$  years).

#### Topography of trochlear spine and fovea

The position of the trochlear spine/fovea on a frontal plane was determined as detailed in materials and methods. D1 and D3 are the distance between the trochlear fovea or the base of the trochlear spine and two perpendicular lines passing through the supraorbital notch (L1) and the frontozygomatic suture (L2) respectively (Fig. 1a). D1 and D3 mean values were respectively  $8.5 \pm 2.3$  mm and  $5.7 \pm 1.5$  mm. D1 and D3 did not show any statistically significant differences between sexes (D1 =  $8.8$  mm  $\pm$  2.5 in male orbits and  $8.1$  mm  $\pm$  2.0 in female orbits; D3 =  $5.3$  mm  $\pm$  1.6 in male orbits and  $5.6$  mm  $\pm$  1.5 in female orbits).

We also checked the distance D2, at the level of the supraorbital notch, between a horizontal line (L3) passing through the trochlear fovea/spine and the orbital roof, and the distance D4, at the level of the frontozygomatic suture, between a vertical line (L4) passing through the trochlear fovea/spine and the medial wall of the orbit (Fig. 1b). D2 measured on average  $5.1 \pm 1.3$  mm and D4  $0.9 \pm 0.4$  mm. Student's *t*-test did not demonstrate any sex-related difference (D2 =  $5.3 \pm 1.4$  mm in male orbits and  $4.8 \pm 1.2$  mm; D4 =  $0.9 \pm 0.4$  mm in male orbits and  $0.9 \pm 0.3$  in female orbits).

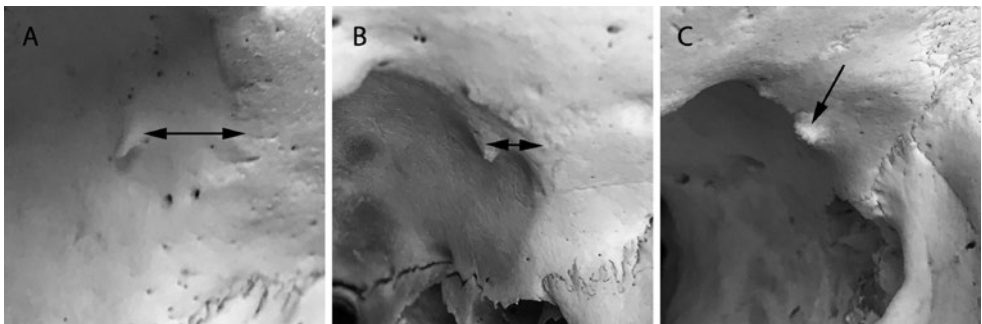
The distances of the trochlear fovea/spine from the anterior orbital opening (D5) and from the anterior rim of the optic foramen (D6) were also recorded as a mean to place the fovea/spine along an antero-posterior axis. Overall, D5 was  $4.2 \pm 0.11$  (range from 0.5 to 8 mm) whereas D6 was  $37.5 \pm 3.1$  mm (range from 30 to 44 mm). Whereas D5 was almost exactly the same in both sexes ( $4.2 \pm 1.2$  mm in male orbits and  $4.2 \pm 0.9$  in female orbits), D6 differed significantly ( $38.5 \pm 2.3$  mm in male orbits and  $36.2 \pm 3.5$  mm in female orbits;  $p < 0.05$ ).

## Discussion

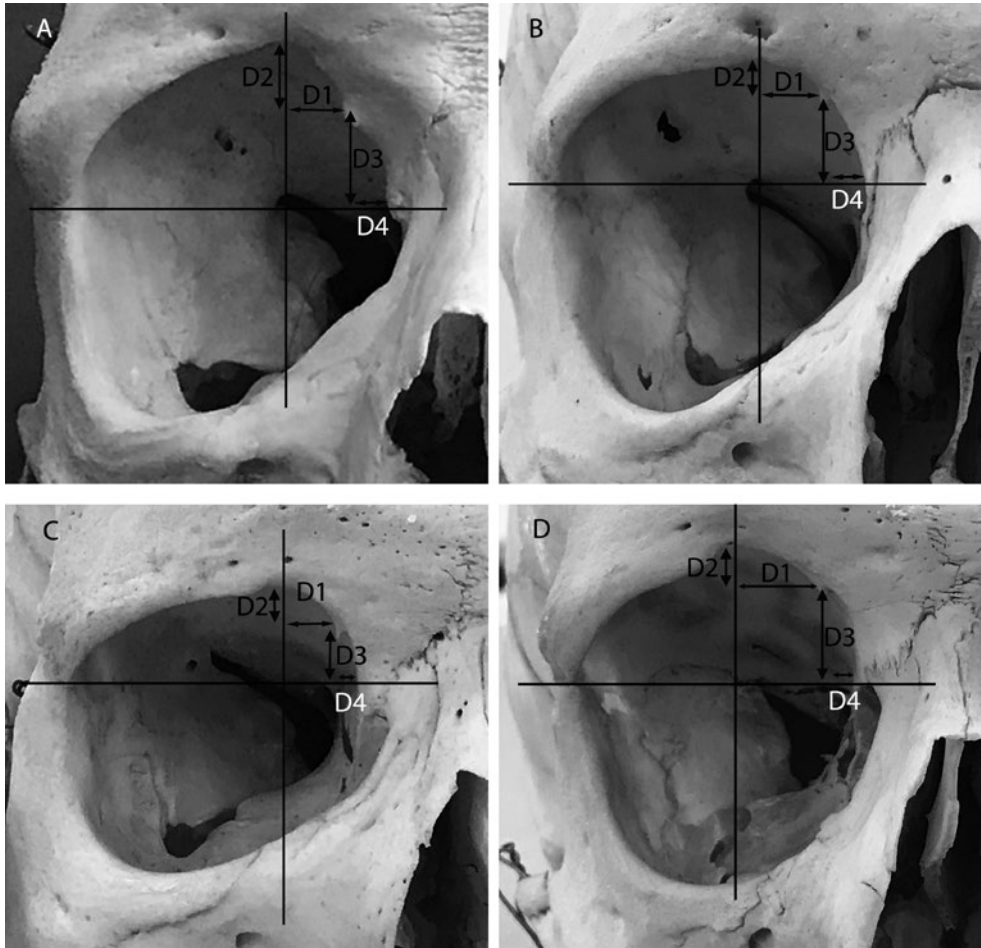
When frontal sinus surgery is carried out via external (i.e. non-endoscopic) approaches, the cartilaginous pulley of the superior oblique muscle can be encoun-

tered and injured. In particular, this can occur in frontal sinus trephination (Bartley et al., 2012) and external fronto-ethmoidectomy (Graham, 2016). However, any surgical procedure concerning manipulations of the superomedial angle of the orbit is likely to involve the trochlea (Haug et al., 2000; Tabatabaie et al., 2011; Gassner et al., 2014; Ji et al 2015; Ding et al., 2015; Ulivieri et al., 2015). Knowledge of the exact topography of the cartilaginous pulley is therefore essential to avoid unwanted injuries and possible post-operative complications. The main result of this report is the definition of the area where the trochlea is expected to be found. In particular, assuming that the cartilaginous pulley is located at the centre of the trochlear fovea, the trochlea should be found about  $4.2 \pm 0.11$  mm behind the orbital rim. The narrow standard deviation indicates that the trochlea is almost always at the same depth behind the orbital opening. However, the surgeon should be aware that occasionally the trochlea can be found in any point between 0.5 and 8 mm behind the rim (Fig. 2). The position of the trochlea has been also defined taking advantage of two orthogonal lines passing through two well-known bony landmarks. These lines (one vertical through the supraorbital notch, the other horizontal through the frontozygomatic suture) realize a Cartesian coordinate system (Fig. 1a) that can be employed to specify the point where the trochlear fovea/spine (and therefore the cartilaginous pulley) can be projected on a frontal plane. Based on this principle, we observed that the trochlea can be projected to a point located  $8.5 \pm 2.3$  mm medial to the vertical line and  $5.7 \pm 1.5$  mm above the horizontal line. These values offer a valid help for the operator who, however, should remember that they represent means. The distance from the vertical line, in fact, ranges between 4 and 14 mm whereas the distance from the horizontal line is comprised between 2 and 9 mm (Fig. 3). This variability is likely the result of variations in orbital shape.

All taken measures do not differ between sexes with the exception of D6 (the distance between the trochlear fovea/spine) and the anterior rim of the optic foramen. In this case the distance in male orbits is significantly greater than in female orbits. This difference had to be expected as the average size of male and female orbits differ substantially (Bron et al., 2001). The different length of male and female orbits was confirmed in our series where they measured respectively  $42.5 \pm 2.6$  and  $40.8$

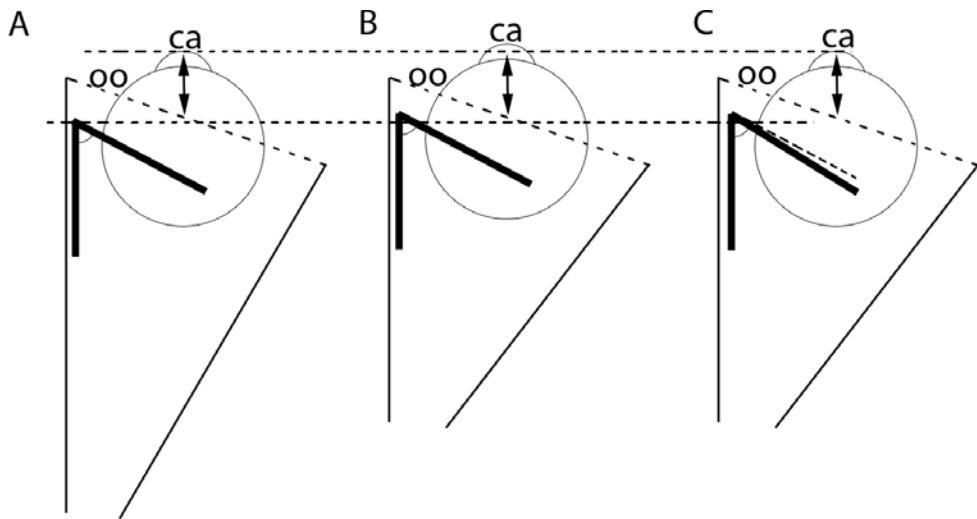


**Figure 2.** Distance variability between the trochlear spine and the anterior orbital opening. The spine can be located well behind the orbital opening (about 6 mm) as in **A**; in most cases the spine is about 4 mm behind the opening as in **B**; it can also be almost coinciding with the orbital opening as in **C**.



**Figure 3.** D1-D4 variability. Four orbits (A-D) show the broad variability of D1-D4 parameters. The difference is likely the result of orbital shape variation.

$\pm 3.7$  mm. If the position of the trochlear fovea/spine along the superomedial angle of the orbit were the same in both sexes, the distances from both the optic canal and the orbital rim should be proportionally lower in female orbits. In contrast, the distance between the orbital rim and the trochlear fovea/spine (D5) is the same regardless of sex. In other words, D5 does not change in spite of the greater length of male orbits. This finding is in accordance with the notion that eye proptosis is similar in both sexes (Karti et al., 2015), and that the trochlear angle, about  $55^\circ$ , is also the same in male and female orbits (Lang, 2012). Actually, if the trochlear spines in female orbits were closer to the orbital rim than in male orbits, either the eye should be also more bulging from the orbital opening or the trochlear angle should be narrower (Fig. 4).



**Figure 4.** The superior oblique pulley in male and females orbits is not located in the same position along the superomedial angle, though the distance between the trochlea and the orbital rim is the same in both sexes. A consequence of having the same distance between the pulley and the orbital opening is that there is no difference in eye proptosis and trochlear angle between sexes. In contrast, if the trochlear position were the same in males (**A**) and females (**B, C**), the distance between the pulley and the anterior orbital opening should change according to the length of the orbit and, as a consequence, eye proptosis in female orbits (which are shorter) should be more pronounced (**B**) or the trochlear angle should be narrower (**C**). For example, the orbits shown in **B** and **C** have been drawn 1/5 shorter than that in **A** to represent a female (**B, C**) and a male orbit (**C**). As a result, the distance of the pulleys (the corner in the thick line, which represents the superior oblique muscle) from the orbital rim and the orbital apex is reduced accordingly (1/5 than in **A**); the pulleys in **B** and **C** are therefore 1 mm closer to the orbital rim. Comparing **A** with **B**, where the trochlear angle is the same, the distance between the corneal (*ca*) apex and the orbital opening (*oo*) is 1 mm longer in **B** and the eyeball is also 1 mm more proptotic. Comparing **A** with **C**, where the distance between the corneal (*ca*) apex and the orbital opening (*oo*) is the same, the trochlear angle must necessarily be narrower. Otherwise, if eye proptosis and trochlear angles were the same the tendon should insert into the eyeball 1 mm ahead the usual site of insertion (dotted line). The lower dotted horizontal ruler helps to compare the position of the trochlea position in **A, B** and **C**. The superior dotted horizontal ruler, in contrast, helps to compare eye proptosis between **A, B** and **C**.

On a dry skull, the anatomical landmarks marking the position of the cartilaginous pulley of the superior oblique muscle are the trochlear fovea and/or the trochlear spine. One or both these osteologic features are present with a high frequency (78.2% of orbits). In most cases it is the trochlear fovea that indicate the position of the pulley. The trochlear fovea is a shallow depression that can also be undetectable. Indeed, we ascertained that it can be observed in 73.4% of orbits, an anatomic incidence that cannot be compared with other studies since, to our knowledge, it had never been previously assessed. In 15% of orbits a more or less developed trochlear spine is visible. This anatomical frequency closely matches previous reports (Lang, 2012). In a surgical setting, for instance in frontal sinus trephination (Bartley et al., 2012), the operator usually performs a subperiosteal dissection elevating the trochlea together with the superior oblique tendon. This manoeuvre, however, can result more

difficult in the presence of a trochlear spine. Interestingly, our results show that the presence of the trochlear spine does not appear to be an age-dependent phenomenon. It is indeed debated if the trochlear spine is due to the calcification of one of the ligaments suspending the trochlea to the orbital roof or if it is just an anatomic variation. Our results support the latter hypothesis which is also sustained by the detection of sutures at its base and by the observation that it seems to develop from its own chondral ossification centre (Lang, 2012). In summary, though the position of the superior oblique trochlea appears on average quite fixed, our study provides evidence that some important variations may exist. The orbital surgeon should be aware of them in order to avoid complications due to injury of the cartilaginous pulley and/or superior oblique tendon.

## References

- Bartley J., Eagleton N., Rosser P., Al-Ali S. (2012) Superior oblique palsy after frontal sinus mini-trephine. *Am. J. Otolaryngol.* 33: 181-183.
- Bron A.J., Tripathi R.C., Tripathi B.J. (2001) The extraocular muscles and ocular movements. In: Bron A.J., Tripathi R.C., Tripathi B.J., editors. *Wolff's Anatomy of the Eye and Orbit*. 8th edn. London, Arnold. Pp. 107-177.
- Ding J., Zhao H., Lin J. (2015) Surgical excision of orbital cysticercosis lodged in the superior oblique muscle: clinical case report. *Medicine* 94: e1026.
- Gassner H.G., Schwan F., Schebesch K.-M. (2016) Minimally invasive surgery of the anterior skull base: transorbital approaches. *GSM Curr. Top. Otorhinolaryngol. Head. Neck Surg.* 14: Doc03.
- Graham S.M. (2016) Complication of frontal sinus surgery. In: Kountakis S.E., Senior B.A., Draf W., editors. *The Frontal Sinus*. 2nd edn. Berlin-Heidelberg, Springer-Verlag. Pp. 419-430.
- Haug R.H. (2000) Management of the trochlea of the superior oblique muscle in the repair of the orbital roof trauma. *J. Oral Maxillofac. Surg.* 58: 602-606.
- Ji S.Y., Yoo J.H., Ha W.H., Lee J.W., Yang W.S. (2015) Three cases of acquired simulated brown syndrome after blowout fracture operations. *Arch. Plast. Surg.* 42: 346-350.
- Karti O., Selver O.B., Karahan E., Zengin M.O., Uyar M. (2015) The effect of age, gender, refractive status and axial length on the measurements of Hertel exophthalmometry. *Open Ophthalmol. J.* 9: 113-115.
- Lang J. (2012) *Clinical Anatomy of the Head*. Berlin, Heidelberg, New York, Springer-Verlag.
- McQueen C.T., DiRuggiero D.C., Campbell J.P., Shockley W.W. (1995) Orbital osteology: a study of the surgical landmarks. *Laryngoscope* 105: 783-788.
- Tabatabaie S.Z., Rajabi M.T., Tari A.S., Rajabi M.B. (2011) Multiple orbital dermoid cysts located within the superior oblique muscle. *Iran J. Ophthalmol.* 23: 65-68.
- Ulivieri S., Galluzzi P., Giorgio A., Lio R., Tacchini D., Fruschelli M. (2014) Epithelial cyst of the superior oblique muscle trochlea. *Orbit* 33: 1-3.