

Research Article - Histology and Cell Biology

Mucus secretion and collagen fibres integrity are compromised in aspirin induced gastric lesion; protective role of *Musa paradisiaca*

 Margaret O. Alese¹, Olarinde S. Adewole², Omamuyovwi M. Ijomone³, David A. Ofusori², Oluwole O. Alese⁴
¹Department of Anatomy, College of Medicine, Ekiti State University, Ado Ekiti, Nigeria

²Department of Anatomy, College of Health Sciences, Obafemi Awolowo University, Ile Ife, Nigeria

³Department of Anatomical Sciences, School of Health and Health Technology, Federal University of Technology, Akure, Nigeria

⁴Department of Physiology, College of Medicine, Ekiti State University, Ado Ekiti, Nigeria

Abstract

The study investigated the healing effects of flavonoid-rich fraction of *Musa paradisiaca* fruit on the gastric corpus of Wistar rats following aspirin induced-gastric lesion. Ninety adult male Wistar rats were assigned to 6 groups. Gastric lesion was induced in groups B, C, D, E and F rats by administration of 400 mg/kg aspirin. After 24 hours, the extract of *M. paradisiaca* was administered to groups C, D and E at graded doses for 21 days. Group F rats received omeprazole at 1.8 mg/kg daily for 21 days. The rats were sacrificed on days 14, 21 and 28. Gastric tissues were fixed in neutral buffered formalin and processed by paraffin wax embedding. Sections were stained with haematoxylin and eosin, Masson's trichrome and periodic acid-Schiff's. There was a gradual restoration of the damaged epithelia in the treatment groups. Histomorphometric studies revealed a significant increase in the total thickness of mucosal layers in the treatment groups when compared with aspirin only group. There was a dose-dependent improvement in staining for mucins in the treatment groups. Also, the treatment groups displayed a progressively positive stain for deposition of collagen. It is concluded that *M. paradisiaca* significantly attenuated the damaging effects of aspirin on the gastric mucosa, probably via a mechanism involving increase in mucin secretion.

Key words

Gastric lesion, mucins, acetylsalicylic acid, collagen, flavonoids.

Introduction

Gastric ulcer is a sore that forms in the lining of the stomach. It results from an imbalance between some endogenous aggressive factors - such as hydrochloric acid, pepsin, refluxing bile, leukotrienes and reactive oxygen species (ROS) - and cytoprotective factors which include the function of the mucus-bicarbonate barrier, surface active phospholipids, prostaglandins, mucosal blood flow, cell renewal and migration, non-enzymatic and enzymatic antioxidants and some growth factors (Bhattacharjee et al., 2002).

The pathogenesis of ulcer is multifactorial and includes stressful lifestyle, alcohol consumption, use of steroidal and non-steroidal anti-inflammatory drugs (NSAIDs)

* Corresponding author. E-mail: margaret.alese@eksu.edu.ng

and drugs which stimulate gastric acid and pepsin secretion, *Helicobacter pylori* infections, trauma, shock, smoking, low socio-economic status and family history (Bandyopadhyay et al., 2001).

Aspirin is a potent NSAID that is associated with gastrointestinal effects of variable severity ranging from mild dyspepsia to severe fatal gastric bleeding. It leads to inhibition in the gastric mucosal protective factors and at the same time increases the aggressive factors (mainly acid and pepsin) to which the mucosa of the stomach is exposed (Beers and Berkow, 2006).

The pathogenesis of NSAIDs-induced gastric ulceration includes the block of cyclooxygenase (COX) activity that leads to lowered mucus secretion, decreased mucosal blood flow, neutrophil infiltration, increased production of ROS, alteration of microvascular structures and increase of acid and pepsinogen secretion among others (Jainu et al., 2006).

The major therapeutic approach for gastric ulcer is the control of gastric acid secretion and reinforcement of gastric mucosal production using antacids, H₂-receptor blockers, proton pump inhibitors, anticholinergics and cytoprotective agents (Rao et al., 2004), besides eradication of *H. pylori* infection if present. The prevention or cure of peptic ulcer is a challenging problem in medicine because most therapies face drawbacks such as high recurrence rates. Additionally, most of the drugs are often associated with side effects ranging from diarrhoea, itching and dizziness to arrhythmia, impotence, gynecomastia and hematopoietic changes (Akhtar et al., 1992, Bandyopadhyay et al., 2002, Chan and Leung, 2002). Also, various therapeutic agents developed for the treatment of gastric ulcer can lead to a decrease in prostaglandin concentrations, which are vital to mucosa integrity maintenance and gastric ulcer healing (Berenguer et al., 2002; Brunton et al., 2007). These drawbacks contribute to recurrence rates and incomplete efficacy of drugs, hence the need for more efficacious therapy (Jones et al., 1999).

In recent times, there has been a paradigm shift in the use of alternative therapies and natural products especially those derived from plants, since medicinal plants are among the most attractive sources of drugs and have been shown to produce promising results in the treatment of various diseases including gastric ulcer (Mouhsen, 2013). Also, the role of mucosal factors in gastric ulcer has received much attention, so it is well established that gastric ulcer can not only be prevented but also be cured by strengthening the defensive mechanisms of gastric mucosa. The antiulcerogenic activity of many natural products of plants and herbs is reported as due to an increase in mucosal defensive factors rather than decrease in the offensive factors (Amani et al., 2013).

Musa paradisiaca, a tropical plant, is a cultivar group of the plantains which has been consumed since centuries by humans and animals as a nutritious food. It is characterized as False Horn Plantain AAB and has to be cooked to be edible (Jones, 2000). It is an herbaceous plant (up to 9 m high) with oblong and fleshy fruits; 5-7 cm long in wild form and longer in the cultivated varieties. In traditional folk medicine, different parts of this plant including the root, leaf, fruit, stem and flowers are used for numerous purposes. It is known to have medicinal properties which include anti-diarrheal, antiulcerogenic, antimicrobial, hypoglycemic, hypocholesterolemic, antihypertensive and diuretic, anti-tumour, broncho-dilatory, expectorant, and wound healing effects (Imam and Akter, 2011). Studies have shown that the extract of unripe *M.*

paradisiaca have high antioxidant activity which are attributed to the presence of phenols and phytochemicals which are potent antioxidants with free radical scavenging activities (Eleazu et al., 2011). Previous research has shown the value of *M. paradisiaca* in the management of gastric ulcer (Dunjić et al., 1993; Goel and Sairam, 2000). The medicinal properties of plants used in the treatment of gastric ulcers are attributed mainly to the presence of flavonoids and are influenced by other organic and inorganic compounds such as coumarins, alkaloids, terpenoids, tannins, phenolic acids and antioxidant micronutrients (Czinner et al., 2001). Phytochemical analyses of *M. paradisiaca* showed the presence of carbohydrates (Anhwange, 2008), catecholamines, pectin, flavonoids and related compounds (Lewis et al., 1999; Lewis and Shaw, 2001).

The present study therefore investigates the ameliorative effects of *M. paradisiaca* extract on the microanatomy of the stomach in aspirin induced gastric damage.

Materials and methods

Collection and authentication of plant materials

Mature, unripe fruits of *M. paradisiaca* Linn (Musaceae) were obtained from a farmland and identified by a taxonomist at the Department of Plant Science and Forestry, Ekiti State University, Ado Ekiti, Nigeria. A voucher specimen (reference number UHAE 2014/84) was deposited at the Herbarium of the Department.

Preparation of sample and extract

The fruits were washed, peeled, cut into pieces, air dried and pulverized using an electric grinder. The powdered sample was extracted three times with 70% methanol (20% w/v) with continuous stirring using an orbital shaker at room temperature for 48 hours each time. The mixture was filtered and the filtrate concentrated at 40 °C in a vacuum rotary evaporator to obtain a dark brown extract. To obtain the flavonoid-rich fraction, the crude extract was partitioned by solvent-solvent extraction according to the method of Owoyele et al. (2008). The resulting flavonoid fraction was concentrated, freeze dried in a vacuum freeze drier and stored in a desiccator until needed.

Test for flavonoids

The flavonoid fractions were subjected to phytochemical analysis using Shibata's reaction and ferric chloride test and observed for red and bluish green coloration of flavonoids respectively (Markham, 1982, Trease and Evans, 1993). The flavonoids in the preparation was also quantified by comparison with a standard curve of pure flavonoids.

Animal care and management

Ninety healthy male Wistar rats weighing between 120-150 g used for this study were obtained from the Animal House of the College of Health Sciences, Obafemi Awolowo University, Ile-Ife, Nigeria. They were acclimatized for a week and housed

in plastic cages in the Animal Holding of the Department of Anatomy and Cell Biology, Obafemi Awolowo University, Ile-Ife, Nigeria under standard laboratory conditions of natural light/dark cycle at room temperature and humidity.

The rats were fed on standard rat pellets and given tap water ad libitum. All animals were handled in accordance with the Guidelines for animal research as detailed in the NIH Guidelines for the Care and Use of Laboratory Animals (National Institutes of Health, 2011).

Ethical Approval for this work was obtained from the Health Research Ethics Committee, Institute of Public Health, Obafemi Awolowo University, Ile-Ife, Nigeria (IPHOAU/12/187).

Experimental design, induction of gastric lesion and treatment

The rats were randomly assigned to 6 groups (A, B, C, D, E and F) of 15 rats each. Group A was the unharmed control, group B the harmed group, groups C, D and E the test groups while group F was the harmed, omeprazole treated group. At the commencement of the experiment, stool samples of each animal were obtained and tested for the presence of *H. pylori* antigen using the *H. pylori* Stool Antigen Test kit (Biotech, China). This was to eliminate the possibility of prior infection with *H. pylori*.

Prior to the induction of gastric lesions, rats in the experimental groups were starved overnight so as to ensure complete gastric emptying and a steady state gastric acid secretion. The animals were allowed free access to water during this period. Gastric lesions were induced in Groups B, C, D, E and F rats by a single oral administration of 400 mg/kg reference standard aspirin (Sigma Chemicals, Co., USA) dissolved in 0.5 ml of distilled water (de Carvalho et al., 2011). Twenty-four hours later, flavonoid fraction of *M. paradisiaca* dissolved in distilled water was administered by gavage to the rats in groups C, D and E at daily doses of 100, 200 and 400 mg/kg body weight respectively, for a period of 21 days; these groups have been indicated as ASA + MP₁₀₀, ASA + MP₂₀₀ and ASA + MP₄₀₀. Group F rats received Omeprazole (Divine Essential Formulations, Lagos, Nigeria) dissolved in distilled water at 1.8 mg/kg body weight by gavage for 21 days; this group has been indicated as ASA + OMZ. The rats in group A (Control) received equivalent volumes of distilled water, vehicle for extract and drug for the same period of time.

Sacrifice of animals

Five rats from each group were sacrificed under ketamine anaesthesia at a dose of 75 mg/kg on the 14th and 21st days of treatment while the remaining rats were left untreated for 7 more days before sacrifice.

Tissue processing

Samples of gastric corpus of animals in each group were fixed in 10% neutral buffered formalin and processed by paraffin wax embedding. Sections 4-5 μ m thick produced on a rotary microtome were stained with haematoxylin and eosin for determination of ulcer index; Masson's trichrome and periodic acid-Schiff (PAS) stains were used for demonstration of collagen fibres and mucins respectively.

Using published methods (Pandit et al., 2003), microscopic ulcer index was obtained separately by two pathologists and a mean index was calculated. Upon systematic uniform random sampling, at least four fields of view per slide were observed for this analysis

Normal tissue = 0; Local damage to gastric pits cells = 1; Local damage to gastric glands = 2; Deep damage to gastric glands = 3.

Microscopic ulcer index = (number of lesion 1) + (number of lesion 2) \times 2 + (number of lesion 3) \times 3.

Photomicrography and image analysis

Photomicrographs of the tissue sections were examined and taken at various magnifications under an OMAX 40X-2000X Digital Light microscope. Image J software (National Institute of Health, USA) was used to analyse and quantify photomicrographs. Intensity of Masson's trichome and PAS staining were performed by measuring the mean gray value of pixels. The settings were such that a higher staining intensity corresponded to a lower mean gray value.

Statistical analysis

The results were expressed as mean \pm standard error of the mean (SEM). Two-way ANOVA was used for comparative analysis of the data between treated and non-treated groups, followed by Bonferroni tests for multiple comparison. GraphPad Prism version 5.00 for Windows (GraphPad Software, USA) was used for analysis. Statistical significance was set at $p < 0.05$.

Results

Tests for flavonoids in the extract

Phytochemical analysis of the ethyl acetate fraction of *M. paradisiaca* for the presence of flavonoid was positive as there was a red coloration with Shibata's reaction and bluish green with ferric chloride test respectively. The flavonoid content of the fraction was 0.35 ± 0.02 mg/g quercetin equivalent (QE).

Determination of ulcer index

There was a significant difference in the ulcer index of the gastric corpus between control and treated rats throughout the experimental period. As seen in figure 1, in the gastric corpus, administration of aspirin resulted in a significant increase in ulcer index in both the aspirin only and the aspirin plus *M. paradisiaca* extract treated groups when compared with the control. On the 14th and 21st days of the experiment there was a significant increase in ulcer index in all the treated groups when compared with the control but on the 28th day of the experiment, apart from the ASA + MP₁₀₀ group of rats, there was no significant difference in the ulcer index between

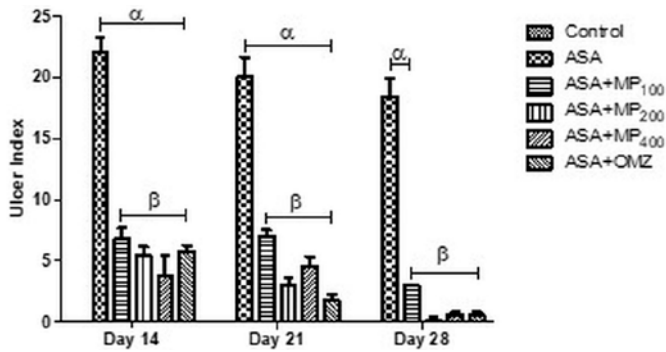


Figure 1. Ulcer index of the gastric corpus on days 14, 21 and 28. Values are mean \pm SEM. α and β = significant difference ($p < 0.05$) compared with control and ASA respectively.

the control and all the treated groups of rats (ASA + MP₂₀₀, ASA + MP₄₀₀ and ASA + OMZ). Throughout the experimental period, the ulcer index of the ASA group remained significantly higher than that of all the other treated groups (ASA + MP₁₀₀, ASA + MP₂₀₀ and ASA + MP₄₀₀ and ASA + OMZ). On the 14th day of the experiment, there was no significant difference in ulcer index among the treated groups of rats (ASA + MP₁₀₀, ASA + MP₂₀₀, ASA + MP₄₀₀ and ASA + OMZ). At the end of the treatment period, a significantly higher ulcer index was however observed for ASA + MP₁₀₀ when compared with ASA + MP₂₀₀, ASA + MP₄₀₀ and ASA + OMZ.

Demonstration of mucins

Figure 2A represents the corpus on days 14, 21 and 28. Results from image analysis show that the PAS staining intensity of the surface mucous and mucous neck cells in the mucosa of the gastric corpus was significantly increased upon treatment, when compared with the control group, except in ASA + OMZ group on day 28. This reflected in a significantly reduced mean gray value in the treated groups when compared with the control and suggests an increase in mucin content following treatment with MP and with OMZ (Fig 2B). An increase in mucin content was observed in the other treatment groups when compared with ASA + MP₁₀₀ group of rats. Results from morphometric analysis also shows in a significant decrease in mean gray values in the other treatment groups when compared with ASA + MP₁₀₀ group throughout the experimental period. On days 14 and 21 of the experiment, there was no significant difference in the mucin content between the ASA + MP₂₀₀, ASA + MP₄₀₀ and ASA + OMZ groups. Two-way ANOVA showed that there was a significant difference in the staining intensity in the corpus among all groups of rats throughout the experimental period.

Demonstration of collagen fibres

In Fig 3A, the MP treated groups displayed positive staining of Masson's trichrome in the connective septa of the glandular tissue and around the muscularis

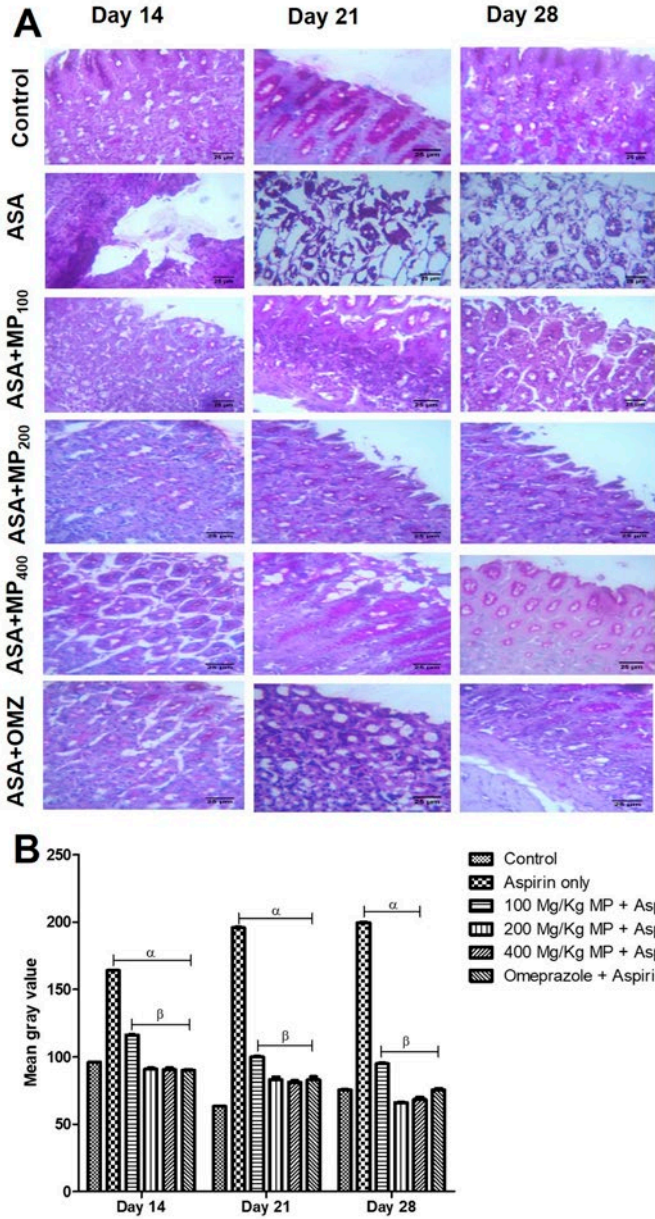


Figure 2A. Representative photomicrographs of the gastric corpus of control, ASA treated and OMZ groups on day 14, 21 and 28. PAS. Arrows show surface mucus and mucus neck cells. 2B: Weekly Image J count of PAS staining intensity of the corpus of control and treated rats. Staining intensity is quantified using mean gray values, in a scale of 0 to 255 from dark (more staining intensity) to bright (less staining intensity). $p < 0.05$, α and β – significant difference compared to control and ASA respectively. Here and in further figures, the staining intensity is quantified as mean gray value in a scale from 0 to 255 from dark (that is more intense stain) to bright (that is less intense stain).

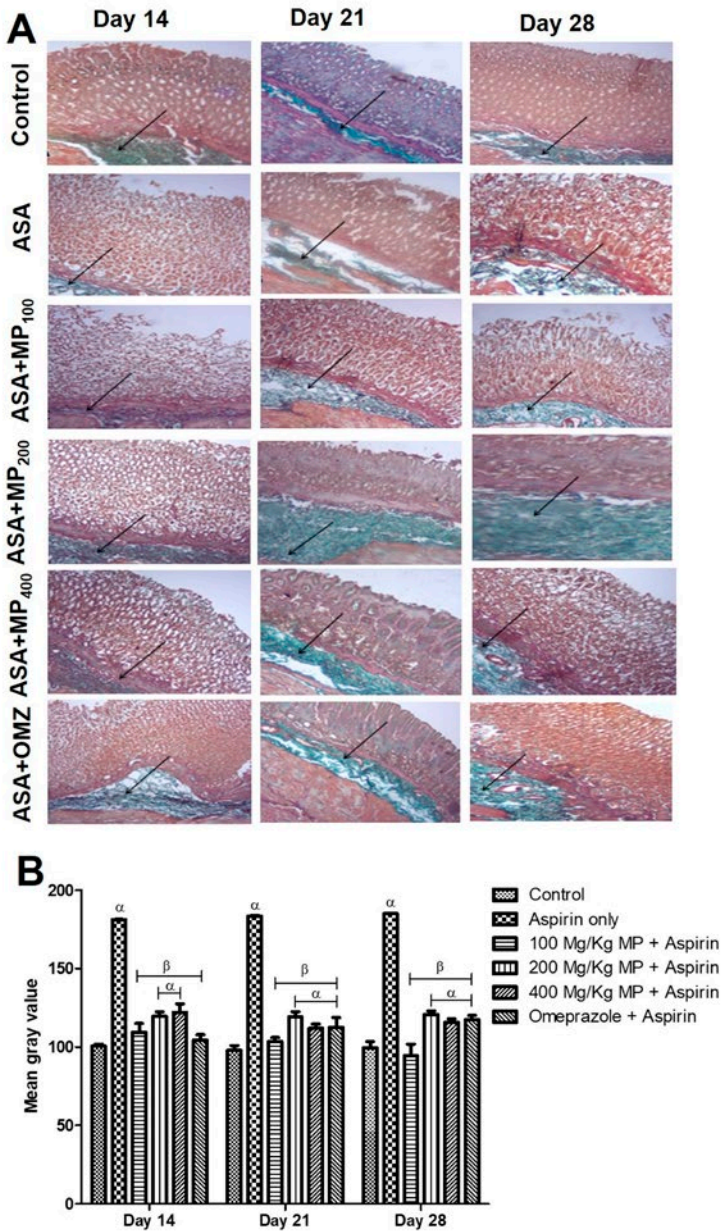


Figure 3A. Representative photomicrographs of the gastric corpus of control, ASA treated and OMZ groups on day 14, 21 and 28. Arrows indicate deposition of collagen in the submucosa and muscularis propria. Masson's trichrome. **3B:** Quantitative analysis of Masson's trichrome staining intensity in the corpus of control and treated rats. α and β = significant difference ($p < 0.05$) compared with control and ASA respectively.

mucosae over the experimental period. Distortion and reduction in the distribution of collagen fibres were also observed in the ASA group.

Results from image analysis (Fig 3B) show a significant increase in the mean gray value in the gastric corpus for the ASA group when compared with the control throughout the experimental period. This indicates a marked reduction in the deposition of collagen fibres in the ASA only group of rats when compared with the control. Throughout the experimental period, there was no significant difference in mean gray value in the ASA + MP₁₀₀ group when compared with the control. The other treated groups however showed a significant difference in mean gray value when compared with the control. Throughout the experimental period, there was a significant difference between the ASA group and all treatment groups.

Discussion

Recent research has shown that administration of aspirin results in enhancement of apoptosis rate and the gastric mucosa develops histopathological and functional alterations which result in injury (Popovic et al., 2009; Scheiman et al., 2010).

Non-steroid anti-inflammatory drugs are known to interfere with all the patterns of mucosal defence by inhibition of prostaglandin secretion (Scheiman, 1992). These patterns include mucous cell secretion of mucin and surface-active phospholipid (Sarosiek et al., 1986), and basal bicarbonate secretion from the mucosa. The defects combine to form a mucous gel poorly suited to perform its role as a barrier to acid diffusion. Also, it interferes with the mucosal proliferation critical to ulcer healing (Levi et al., 1990).

Another mechanism responsible for the topical irritant properties of NSAIDs is their ability to decrease the hydrophobicity of the mucous gel layer in the stomach which is a primary barrier to acid-induced damage in the stomach (Lichtenberger, 1995a). This hydrophobicity of the stomach's surface can be reduced by various pharmacological agents including NSAIDs which associate with the surface-active phospholipids within the mucus gel layer (Lichtenberger et al., 1995a, b).

According to Brunton et al. (2007), among the factors involved in the pathogenesis of the gastric ulcer is the decrease in the synthesis of prostaglandins which results in a decrease in mucous secretion and direct damage to the mucin layer or mucin synthesis (Slomiany et al., 1997), resulting in apoptosis of the gastric cells (Hoshino et al., 2002). Also, decrease in gastric mucus is associated with significant production of free radicals and cell damage (Reshma et al., 2000). Findings from this study indicate that aspirin results in a decrease in mucins and number of mucus secreting cells in the corpus. Also, *M. paradisiaca* and omeprazole attenuated these effects as there was increased PAS staining intensity and in the number of mucus secreting cells. *M. paradisiaca* displayed a dose-dependent effect as 200 and 400 mg/kg treated animals had significantly increased number of mucus secreting cells and mucins over both 100 mg/kg *M. paradisiaca* and omeprazole treated ones. The ulcer healing effect of *M. paradisiaca* could be due to enhancement of the release of protective factors – like mucin, prostaglandins, bicarbonate and scavenging free radicals.

Asides the protection and lubrication of the epithelium, mucins act as free radical scavenger due to their ability to bind to lipids (Prathima and Harendra-Kumar, 2012).

All cell membranes have a lipid bilayer; hence the importance of mucus secretion in maintenance of mucosal integrity cannot be over-emphasized.

The presence of flavonoids in *M. paradisiaca* has been reported; flavonoids have been implicated in wound healing, cellular regeneration and cytoprotection (Lewis et al., 1999; Kumar et al., 2013). Repair of the underlying connective tissue and formation of collagen is an essential process for ulcer healing. In our studies, although the effect was more pronounced in Omeprazole and the lower dose of *M. paradisiaca*, Masson's trichrome stained sections showed increased deposition of collagen fibers in the ulcer base of all the treated groups. The findings from this study are in agreement with results obtained by Silva et al. (2006) while evaluating effect of different phytotherapeutical formulations of cabbage extract in processes of healing of cutaneous wounds. Tarnawski et al. (1991) also reported that ample vascularization of the connective tissue is an important process during re-epithelization, thus favoring healing. When the stomach is ulcerated, myofibroblasts resident beneath the epithelium migrate toward the ulcer bed to form granulation tissue (Fornai et al., 2009). Later, they produce collagen fibrils and other extracellular matrix components and form ulcer scar. In this study, a reduction in the staining intensity for collagen was observed in the aspirin only group. This may be due to dense inflammation of gastric tissues which caused destruction of the glands and connective tissue.

In conclusion, the results from this study have shown that oral administration of flavonoid fraction of mature and unripe fruit extract of *M. paradisiaca* attenuated the damaging effects of aspirin on the gastric mucosa. The ability of *M. paradisiaca* to increase the secretion of mucins may be a major mechanism responsible for these effects.

Further researches are needed to analyse the effects of the extract at other concentrations, produce the active ingredient(s) and test the extract under other routes of administration and pharmaceutical formulations.

Acknowledgement

The authors wish to acknowledge the Tertiary Education Trust Fund (TETFUND) for sponsoring this research; and declare no conflict of interest related to this work.

The publication of this article was supported in part by the Italian Association of Anatomy and Histology.

References

- Akhtar M.S., Akhtar A.H., Khan M.A. (1992) Antiulcerogenic effect of *Ocimum Basilicum* extracts, volatile oil and flavonoids glycosides in albino rats. *Int. J. Pharmacognosy* 30: 97-104.
- Amani S.A., Reham M.E., Gamal A.S. (2013) Natural products in treatment of ulcerative colitis and peptic ulcer. *J. Saudi Chem. Soc.* 17: 101-124.
- Anhwange B.A. (2008) Chemical composition of *Musa sapientum* (banana) peels. *J. Food Technol.* 6: 263- 266.
- Bandyopadhyay D., Biswas K., Bhattacharyya M., Reiter R.J., Banerjee R.K. (2001)

- Gastric toxicity and mucosal ulceration induced by oxygen derived reactive species, protection by melatonin. *Curr. Mol. Med.* 1: 501-513.
- Bandyopadhyay D., Biswas K., Bhattacharyya M., Reiter R.J., Banerjee R.K. (2002) Involvement of reactive oxygen species in gastric ulceration, protection by melatonin. *Indian J. Exp. Biol.* 40: 693-705.
- Beers M.H., Berkow R. (2006) *The Merck Manual for Diagnosis and Therapy*. 17th ed. Merck Research Laboratory Merck and Co, Inc, Whitehouse Station, NJ. Pp. 723-748.
- Berenguer B., Alarcon de la Lastra C., Moreno F.J., Martin M.J. (2002) Chronic gastric ulcer healing in rats subjected to selective and non-selective cyclooxygenase-2 inhibitors. *Eur. J. Pharmacol.* 442: 125-135.
- Bhattacharjee M., Bhattacharjee S., Gupta A., Banerjee R.K. (2002) Critical role of an endogenous gastric peroxidase. *Biochem. Pharmacol.* 37: 271-280.
- Brunton L.L., Lazo J.S., Parker K.L. (2007) *Goodman & Gilman's The Pharmacological Basis of Therapeutics*. 11th ed. New York, McGraw Hill. P. 467.
- Chan F.K., Leung W.K. (2002) Peptic ulcer disease. *Lancet* 360: 933-941.
- Czinner E., Hagymas K., Blazovics A., Kery A., Szoke E., Lemberkovics A. (2001) The in vitro effect of Helichysiflos on microsomal lipid peroxidation. *J. Ethnopharmacol.* 77: 31-35.
- de Carvalho C.A., Fernandes K.M., Matta S.L.P., da Silva M.B., de Oliveira L.L., Fonseca C.C. (2011) Evaluation of antiulcerogenic activity of aqueous extract of *Brassica oleracea* var. *Capitata* (cabbage) on Wistar rat gastric ulceration. *Exp. Gastroenterology* 48: 276-283.
- Dunjić B.S., Svensson I., Axelson J., Adlercreutz P., Ar'Rajab A., Larsson K., Bengmark S. (1993) Green banana protection of gastric mucosa against experimentally induced injuries in rats. A multicomponent mechanism? *Scand. J. Gastroenterol.* 28: 894-598.
- Eleazu C.O., Okafor P.N., Amajor J.A., Awa E., Ikpeama A.I., Eleazu K.C. (2011) Chemical composition, antioxidant activity, functional properties and inhibitory action of unripe plantain (*M. paradisiacae*) flour. *Afr. J. Biotechnol.* 10: 16948-16952.
- Fornai M., Colucci R., Antonioli L., Ghisu N., Tuccori M., Blandizzi C., Del Tacca M. (2009) Effects of pantoprazole on ulcer healing delay associated with NSAID treatment. *Naunyn-Schmiedebergs Arch. Pharmacol.* 379: 305-313.
- Goel R.K., Sairam K. (2002). Antiulcer drugs from indigenous sources with emphasis on *Musa sapientum*, *Tamrabhasma*, *Asparagus racemosus* and *Zingiber officinale*. *Indian J. Pharmacol.* 34: 100-110.
- Hoshino T., Takano T., Tsutsumi S., Tomisato W., Tsuchiya T., Mizushima T. (2002) Effects of prostaglandin E2 on gastric irritant induced apoptosis. *Dig. Dis. Sci.* 47: 2370-2379.
- Imam M.Z., Akter S. (2011) *Musa paradisiacal* L. and *Musa sapientum* L.: A phytochemical and pharmacological review. *J. Appl. Pharmaceut. Sci.* 1: 14-20.
- Jainu M., Mohan V., Devi S. (2006) Protective effect of *Cissus quadrangularis* on neutrophil mediated tissue injury induced by aspirin in rats. *J. Ethnopharmacol.* 104: 302-305.
- Jones D.R. (2000) *Diseases of Banana, Abacá and Enset*. Wallingford, Oxon, CABI Publishing. P. 544.

- Jones N.L., Day A.S., Sherman P.M. (1999) Determinants of disease outcome following *Helicobacter pylori* infection in children. *Can. J. of Gastroenterol.* 13: 613-617.
- Kumar D., Hegde H.V., Patil P.A., Roy S., Kholkute S.D. (2013). Antiulcer activity of water soaked *Glycine Max* L. grains in aspirin induced model of gastric ulcer in Wistar rats. *J. Ayurveda Integrative Med.* 4: 134-137.
- Levi S., Goodlad R.A., Lee C.Y., Stamp G., Walport M.J., Wright N.A., Hodgson H.J. (1990) Inhibitory effect of non-steroidal anti-inflammatory drugs on mucosal cell proliferation associated with gastric ulcer healing. *Lancet* 2: 840-843.
- Lewis D.A., Shaw G.P. (2001) A natural flavonoid and synthetic analogues protect the gastric mucosa from aspirin-induced erosions. *J. Nutrition Biochem.* 12: 95-100.
- Lewis D.L., Field W.D., Shaw G.P. (1999). A natural flavonoid present in unripe plantain pulp (*Musa sapientum* L. var. *paradisiaca*) protects the gastric mucosa from aspirin-induced erosions. *J. Ethnopharmacol.* 65: 283-288.
- Lichtenberger L.M., Wang Z.M., Romero J.J., Ulloa C., Perez J.C., Giraud M.N., Barreto J.C. (1995a) Non-steroidal anti-inflammatory drugs (NSAIDs) associated with zwitterionic phospholipids: insight into the mechanism and reversal of NSAID-induced gastrointestinal injury. *Nat. Med.* 1: 154-158.
- Lichtenberger L.M., Wang Z.M., Giraud M.N., Romero J.J., Barretto J.C. (1995b) Effect of naproxen on gastric mucosal hydrophobicity. *Gastroenterology* 108: A149.
- Markham K.R. (1982) *Techniques of Flavonoids Identification*. New York, Academic Press. Pp. 111-113.
- Mouhssen L. (2013) The success of natural products in drug discovery. *Pharmacol. Pharmacy* 4: 17-31.
- National Institutes of Health. (2011) *Guide for the Care and Use of Laboratory Animals*. 8th edn. Washington, National Academies Press.
- Owoyele B.V., Oguntoye S.O., Dare K., Ogunbiyi B.A., Aruboloula E.A., Soladoye A.O. (2008) Analgesic, anti-inflammatory and antipyretic activities from flavonoid fractions of *Chromolaena odorata*. *J. Med. Plants Research* 2: 219-225.
- Pandit S., Sur T.K., Jana U., Bhattacharyya D., Debnath P.K. (2000) Anti-ulcer effect of Shankha bhasma in rats: A preliminary study. *Indian J. Pharmacol.* 32: 378-380.
- Popovic M., Janicijevic-Hudomal S., Kaurinovic B., Rasic J., Trivic S. (2009) Antioxidant effects of some drugs on ethanol-induced ulcers. *Molecules* 14: 816-826.
- Prathima S., Harendra-Kumar M.L. (2012) Mucin profile of upper gastrointestinal tract lesions. *J. Clin. Biomed. Sci.* 2: 13.
- Rao C.H., Ojha S.K., Radhakrishnan K., Govndarajan R., Rastogi S., Mehrotra S. (2004) Antilcer activity of *Utleria salicifolia* rhizome extract. *J. Ethnopharmacol.* 91: 243-249.
- Reshma S., Vijay K.K., Naidu M.U.R., Ratnacar K.S. (2000) Effects of Gingko biloba extract on ethanol-induced gastric mucosal lesions in rats. *Indian J. Pharmacol.* 32: 313-317.
- Sarosiek J., Mizuta K., Slomiany A., Slomiany B.L. (1986) Effects of acetylsalicylic acid on gastric mucin viscosity, permeability to hydrogen ion, and susceptibility to pepsin. *Biochem. Pharmacol.* 35: 4291-4295.
- Scheiman J.M. (1992) Pathogenesis of gastroduodenal injury due to non-steroidal anti-inflammatory drugs: implications for prevention and therapy. *Semin. Arthritis Rheum.* 21: 20-25.
- Scheiman J., Herlitz J., Devereaux P., Naucler E., Erik L. (2010) Low-dose acetyl-

- salicylic acid-associated peptic ulcers and dyspeptic symptoms are reduced by esomeprazole 20 mg and 40 mg once daily. *Am. Coll. Cardiol.* 1: 55.
- Sharma P.C., Yelne M.B., Dennis J.J., Kadali I.N. (2002) *Data Base on Medical Plants Used in Ayurveda and Siddha*. New Delhi, Public Printing. 11th ed. New York: McGraw Hill Pp. 467.
- Silva M.B., Silva C.A., Malaquias L.C.C., Sarandy M.M., Freire M.C.M., Antunes F.R., Costa A.V.S. (2006) Comparative effect of a phytotherapeutic product from *Brassica* ssp as cicatrizing agent. *Rev. Bras. Plantas Med.* 8: 136-138.
- Slomiany A., Morita M., Sano S., Piotrowski J., Skrodzka D., Slomiany B.L. (1997) Effect of ethanol on gastric mucus glycoprotein synthesis, translocation, transport, glycosylation and secretion. *Alcohol Clin. Exp. Res.* 21: 417-423.
- Trease G.E., Evans W.C. (1989) *A Textbook of Pharmacognosy*. 13th ed. London, Bailliere-Tindall.