

Letter - Human Anatomy Case Report

# Superficial brachial artery traversing a median nerve loop in the arm associated with other vascular and muscular anomalies: case report and clinical implications

George Paraskevas<sup>1</sup>, Nikolaos Lazaridis<sup>1,\*</sup>, Maria Piagkou<sup>2</sup>, Konstantinos Natsis<sup>1</sup><sup>1</sup> Department of Anatomy, School of Medicine, Faculty of Health Sciences, Aristotle University of Thessaloniki, Greece<sup>2</sup> Department of Anatomy, School of Medicine, National and Kapodistrian University of Athens, Greece

## Abstract

Knowledge of the various morphological patterns of the brachial artery and median nerve in the upper limb area is of considerable clinical and surgical importance to physicians intervening with these areas. In the current study, in the right upper limb of a male cadaver a rare variation of a superficial brachial artery associated with a median nerve loop in the upper arm is presented. The artery gave off a deep brachial artery in the arm and normally bifurcated in the cubital fossa. Additionally, a muscular bundle from the brachialis muscle was also present, overlapping the median nerve along with the deep brachial artery above the elbow. To the best of our knowledge such a combination of arterial, neural and muscular anatomical variations is extremely rare. Since brachial plexus and brachial artery variations are more prone to injury, their surgical, diagnostic and interventional importance are valuable to radiologists in interpreting images and to vascular surgeons, neurosurgeons and orthopedic surgeons involved in compressive peripheral neuropathy treatment. The relevant clinical and surgical implications are discussed as well.

## Key words

Superficial brachial artery, nerve loop, median nerve, superficial ulnar artery, accessory brachial muscle.

## Introduction

Apart from the usual formation of the median nerve (MN) from its lateral and medial roots, it has been demonstrated that this nerve can be also formed by three or four roots (Satyanaraya et al., 2009) or even five roots (Natsis et al., 2016). Formation of a MN's loop at the axilla and upper arm region constituting by accessory roots of MN is a condition not so commonly detected. Paraskevas et al. (2015) observed a case of MN's loop at the upper arm traversed by a superficial brachial artery continuing as radial artery. Such a MN's loop has been detected and in other regions such as the forearm penetrated by a persistent median artery (Srivastava and Pande, 1990). As superficial brachial artery is defined a brachial arterial stem that directs superficial

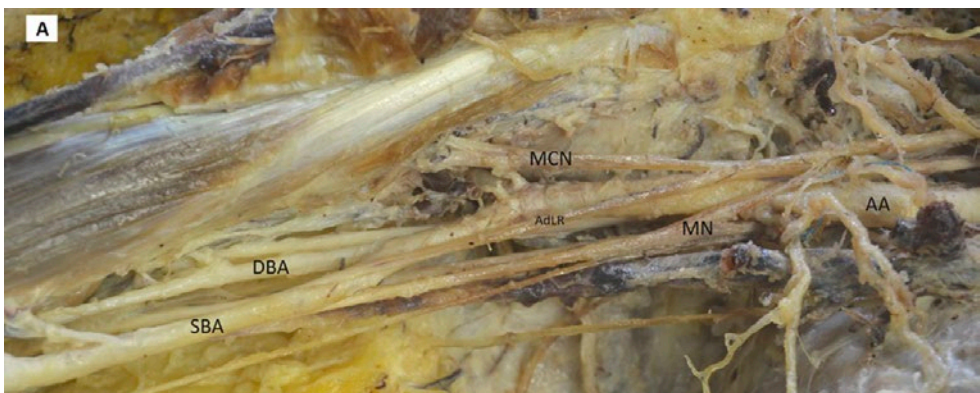
\* Corresponding author. E-mail: lazaridisnikos@auth.gr

to MN and appears with a frequency of 13-22% (Bergman et al., 1988; Lippert and Pabst, 1985). Rarely, such a superficial brachial artery or the brachial artery itself or a branch of them may course superficial to the forearm flexor muscles as superficial ulnar artery (Natsis et al., 2006). Because of the complex nature and developmental process of the brachial plexus and the adjacent vessels, many anatomical anomalies may ensue (Singhal et al., 2007)

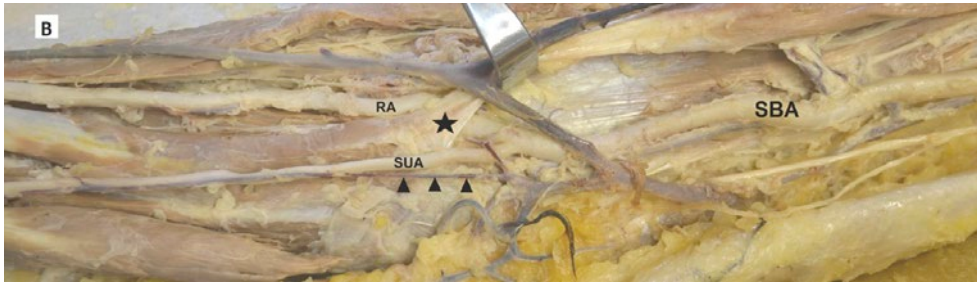
In the current study a very uncommon association of vascular, neural and muscular variants of the upper limb is displayed, which to the best of our knowledge has not been documented previously in the literature. In particular, a MN's loop at the upper arm traversed by a superficial brachial artery that was giving off a radial and superficial ulnar artery, along with an accessory slip of the brachial muscle entrapping the MN and deep brachial artery are presented. We consider that detailed awareness of the brachial plexus and brachial artery variations and their relationships with the neighboring muscular elements is a fundamental prerequisite for successful vascular and reconstructive procedures in the upper limb.

### Case report

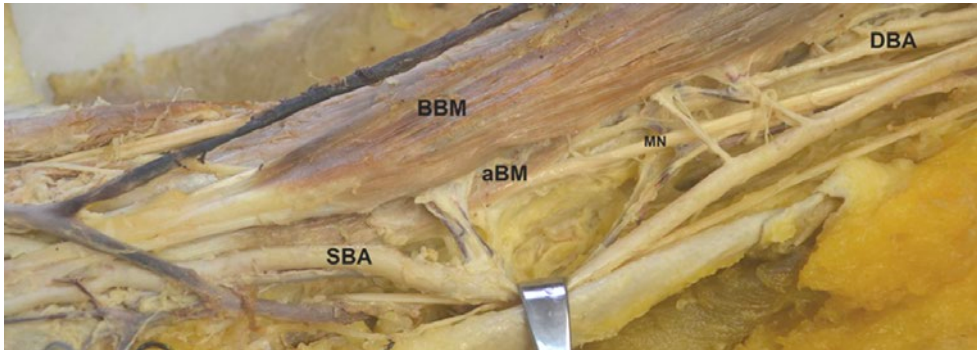
During the routine dissection course for teaching and research purposes, on the right arm of a formalin-alcohol fixed and embalmed 72-year-old Greek male cadaver we came across an unusual formation of the MN with an additional root, associated with the presence of a superficial brachial artery. Specifically, we observed an additional lateral root of the MN originating from the lateral cord of the brachial plexus, thus forming a fusiform neural loop in which the superficial brachial artery was included. In our case the MN was formed by the fusion of three roots, two of them originating from the lateral cord and one from the medial cord. The additional lateral root was coming from the lateral cord of the brachial plexus 1.5 cm distal to the first



**Figure 1A.** At the right upper arm of a male cadaver a median nerve (MN) loop is demonstrated formed by an additional lateral root (AdLR) of the lateral cord of the brachial plexus and traversed by a superficial brachial artery (SBA) (AA: axillary artery, DBA: deep brachial artery, MCN: musculocutaneous nerve).



**Figure 1B.** The superficial brachial artery (SBA) is shown subdivided at the usual site into a sizeable radial artery (RA) and a slender superficial ulnar artery (SUA) overlying the flexor muscles of the forearm and accompanied closely by the median vein of the forearm (arrowheads) (asterisk: bicipital aponeurosis).



**Figure 2.** The median nerve (MN) and the deep brachial artery (DBA) are shown entrapped by an accessory brachii muscle (aBM) at the region of the medial bicipital sulcus of the right arm (SBA: superficial brachial artery, BBM: biceps brachii muscle).

lateral root to join the MN in the proximal arm. The origin and course of the ipsilateral ulnar nerve was normal. In particular, the brachial artery just at its initial portion was divided into a superficial brachial artery and a deep brachial artery; the former should be distinguished from the arteria profunda brachii that accompanies the radial nerve within the spiral groove of the humerus. The superficial brachial artery traversed the aforementioned MN's loop coursing in the medial bicipital sulcus superficial to the MN (Figure 1A). The superficial brachial artery supplied the muscles of the anterior compartment of the arm with numerable muscular branches and at the usual site of the neck of the radius was subdivided into the radial and ulnar artery. The radial artery that was sizeable directed to the groove between the brachioradial and radial flexor muscle of the wrist as normally does, whereas the ulnar artery was slender coursing abnormally superficial to the flexor muscles of the forearm to reach the ulnar nerve just proximal to the ipsilateral wrist area. That superficial ulnar artery was accompanied closely by the median antebrachial vein (Figure 1B). The initial part of deep brachial artery was in close proximity to the radial nerve and after giving off the profunda brachial artery was directed to the medial bicipital sulcus lateral to the

MN. In the distal half of the arm the deep brachial artery along with the MN were bridged by an accessory muscular slip of the brachial muscle that was inserted to the medial intermuscular septum of the arm. The deep brachial artery terminated within the so-formed fibromuscular tunnel, whereas MN coursed distally without displaying any further variations (Figure 2). Both MN and brachial artery on the left side were normal. The cause of death was unrelated to the current study. We did not notice any other concomitant anatomic variations and no evidence of previous surgical interventions in the area existed. Repeated photographs were taken for documentation of this rare finding.

## Discussion

As it is widely known, the MN is formed by the fusion of two roots, the lateral and the medial, arising from the lateral and medial cords of the brachial plexus, respectively. Both roots join together at the level of the third part of the axillary artery usually embracing the vessel, anterior or lateral to it, thus forming the MN (Standring, 2005). A MN's loop including a superficial brachial artery has been described previously (Paraskevas et al., 2015), whereas a loop formed by accessory lateral roots of the MN involving the axillary artery has been described by Bhat et al. (2009), as well. Furthermore, MN's penetration by other arteries, such as an axillary artery's branch in a frequency of 1.46% has been mentioned as well (Miller, 1939).

Pandey and Shukla (2007), in their study reported that the MN had an abnormal formation and course in up to 7% of the cadavers, while Miller (1939) reported abnormal relationship between axillary artery and brachial plexus in 8%. Furthermore, MN formation by three or four roots has been also reported by other authors (Satyanaraya et al., 2009). Interestingly, a case of a five roots pattern of MN's formation has been prescribed in the relevant literature (Natsis et al., 2016). The extremely interesting case of a missing MN obtained by needle examination, has been also mentioned, where the MN terminated in the forearm and the ulnar nerve innervated all hand muscles (O'Neil et al., 1990).

A superficial brachial artery constitutes a vessel that displays a course anterior to that of the MN and occurs with an incidence of 13% (Bergman et al., 1988) or 22% (Lippert and Pabst, 1985). The superficial brachial artery can replace the normal brachial artery or occur in addition to it (Lippert and Pabst, 1985). The superficial brachial artery continued as the radial artery twice as frequently as it continued as the ulnar artery; less frequently it continued as both arteries (Bergman et al., 1988). Two main brachial arterial stems have been detected in 13%. In particular, the case in which the one stem runs in front of the MN is documented in 8% of the studied specimens (Lippert and Pabst, 1985). A similar case is the specimen of the current study, where the initial portion of the superficial brachial artery passed through the MN's loop coursing anterior to the MN, whereas the deep brachial artery directed alongside the medial border of the biceps brachial muscle providing the *arteria profunda brachii* as well as muscular branches for the biceps brachial muscle. In our case report, it is interesting that the superficial brachial artery divided into a large radial artery and a slender superficial ulnar artery accompanied by the median antebrachial vein and lying ventral to the flexor muscles of the forearm. Such, an arterial pattern

as the abovementioned is detected in 3% of the cases (Lippert and Pabst, 1985). In human embryos of 5 millimeters, it is the subclavian-axillary artery that becomes the sole arterial stem. Later on, the superficial brachial artery is formed, giving rise to the radial artery, whilst its proximal part that is connected to the brachial artery disappears. When the superficial brachial artery's proximal part remains, then a persistent superficial brachial artery occurs (Arey, 1960).

Our specimen displayed a combination of anatomical variants that to the best of our knowledge has never been detected in the literature, since a MN's loop was traversed by a very rare superficial brachial artery's morphological pattern associated with muscular bridging of the deep brachial artery and MN by an accessory brachial muscle's band. Paraskevas et al. (2008) observed aberrant fascicles of the muscles of the flexor compartment of the arm in an incidence of 2.68% entrapping nerves and vessels. In specific, these authors noticed the presence of an abnormal muscle arising from the medial border of the brachial muscle and, after bridging the MN, brachial artery and vein, inserting into the medial intermuscular septum of the arm. Similarly, Loukas et al. (2006) mentioned an accessory brachial muscle originating from the midshaft of the humerus and the medial intermuscular septum of the arm and after crossing the MN and brachial artery inserting into the brachialis tendon and the common tendon of the muscles of the anterior compartment of the forearm. The aforementioned accessory muscles or muscular slips could potentially induce symptoms from entrapment of the underlying nerves or/and vessels. Such a condition takes place usually in cases of significant hypertrophy of these muscles (Gessini et al., 1983).

The clinical impact-value of our case report is multiple. It has been stated that the presence of brachial plexus variations coexisting with arterial aberrancies makes these structures more vulnerable and prone to injury (Gacek, 1990). In particular, the superficial brachial artery could under certain circumstances such as aneurysm or thrombosis compress the MN leading to symptom of MN's neuropathy. Furthermore, the superficial location of the ulnar artery in our specimen can be mistaken for a subcutaneous vein. In such a case an "intravenous" injection could lead to arterial contraction, stenosis and subsequently to ischemia of the hand. Apart from the previous clinical implications the accessory brachial muscle's slip could lead to motor disability and disturbances in sensitivity due to MN's compression, as well as ischemic symptoms from a potential brachial artery's entrapment. It should be emphasized that from the medical history of our case there was no report of vascular or/and neural disturbances of the ipsilateral upper limb, since the data obtained were inadequate.

Conclusively, the surgeon of the region should bear in mind the fact that in case of an abnormal artery of the upper limb, an additional variation of the related neural structures may exist. Moreover, the physician should be suspicious in cases of upper limb nerves' neuropathies, attributing them to a potential presence of an aberrant muscle entrapping a nerve.

## References

- Arey L.B. (1960) *Developmental Anatomy. A Textbook and Laboratory Manual of Embryology*, 6<sup>th</sup> edn. W.B. Saunders Co., Philadelphia. Pp. 375-376.

- Bergman R.A., Thomson S.A., Afifi A.K., Saadeh F.A. (1988) *Compendium of Human Anatomic Variation: Text, Atlas and World Literature*. Urban und Schwarzenberg, Munich. Pp.73-74.
- Bhat K.M.R., Gowda S., Potu B.K. (2009) Nerve loop around the axillary vessels by the roots of the median nerve, a rare variation in a south Indian male cadaver: a case report. *Cases J.* 2: 179.
- Gacek R.R. (1990) Neck dissection injury of a brachial plexus anatomical variant. *Arch. Otolaryngol. Head Neck Surg.* 116: 356-358.
- Gessini L., Jandolo B., Pietrangeli A. (1983) Entrapment neuropathies of the median nerve at and above the elbow. *Surg. Neurol.* 19: 112-116.
- Lippert H., Pabst R. (1985) *Arterial Variations in Man. Classification and Frequency*, J.F. Bergmann Verlag, Munchen. Pp.68-72.
- Loukas M., Louis R.G. Jr, South G., Alsheik E., Christopherson C. (2006) A case of an accessory brachialis muscle. *Clin. Anat.* 19: 550-553.
- Miller R.A. (1939) Observations upon the arrangement of the axillary artery and brachial plexus. *Am. J. Anat.* 64: 143-163.
- Natsis K., Papadopoulou A., Paraskevas G., Totlis T., Tsikaras P. (2006) High origin of a superficial ulnar artery arising from the axillary artery: anatomy, embryology, clinical significance and review of the literature. *Folia Morphol.* 65: 189-94.
- Natsis K., Paraskevas G., Tzika M. (2016) Five roots pattern of median nerve formation. *Acta Med.* 59: 26-28.
- O.Neil T., Giancarlo T., Spitzer A.R. (1990) The case of the missing median nerve. *Muscle Nerve* 13: 882-883.
- Pandey S.K., Shukla V.K. (2007) Anatomical variations of the cords of brachial plexus and the median nerve. *Clin. Anat.* 20: 150-156.
- Paraskevas G., Natsis K., Ioannidis O., Papaziogas B., Kitsoulis P., Spanidou S. (2008) Accessory muscles in the lower part of the anterior compartment of the arm that may entrap neurovascular elements. *Clin. Anat.* 21: 246-251.
- Paraskevas G.K., Varnalidis I., Koutsouflianiotis K. (2015) Median nerve's loop in the arm penetrated by a superficial brachial artery: case report and neurosurgical considerations. *Int. J. Res. Med. Sci.* 3: 2123-2125.
- Satyanarayana N., Vishvakarma N., Kumar G.P., Guha R., Datta A.K., Sunitha P. (2009) Rare variations in the formation of median nerve-embryological basis. *Nepal Med. Col. J.* 11: 287-290.
- Singhal S., Rao V.V., Ravindranath R. (2007) Variations in brachial plexus and the relationship of median nerve with the axillary artery: a case report. *J. Brachial Plex. Peripher. Nerve Inj.* 3: 21.
- Srivastava S.K., Pande B.S. (1990) Anomalous pattern of median artery in the forearm of Indians. *Acta Anat.* 138: 193-194.
- Standring S. (2005) *Gray's Anatomy*, 39<sup>th</sup> edn. Elsevier/Churchill Livingstone, Edinburgh. Pp. 846-848.