

Research Article - Basic and Applied Anatomy

Comparative morphology of the visual and auditory reflex centres in the African grasscutter (*Thryonomys swinderianus* – Temminck, 1827)

Chikera S. Ibe*, Ekele Ikpegbu, Uchenna C. Nlebedum

Department of Veterinary Anatomy, Michael Okpara University of Agriculture, Umudike, Nigeria

Abstract

The African grasscutter is a nocturnal rodent, currently bred as a minilivestock, and research model. The present study was aimed at describing the structure of the auditory and visual reflex centres, with a view to understanding the nocturnal behaviour of the rodent. The rostral and caudal colliculi of the mesencephalic tectum were harvested from neonate, juvenile and adult African grasscutters and subjected to basic neuro-anatomical techniques. On each postnatal period, the corpora quadrigemina was bound rostrally by the 3rd ventricle and caudally by the 4th ventricle, and the caudal colliculus was grossly bigger than the rostral colliculus. The heights of the rostral and caudal colliculi in the neonates were 6.38 ± 0.28 mm and 8.78 ± 0.08 mm, respectively, and the difference was significant ($P < 0.05$). The values in the juveniles were 5.94 ± 0.21 mm and 11.45 ± 0.17 mm, respectively, and the difference was significant ($P < 0.05$). The values in the adults were 8.08 ± 0.35 mm and 16.16 ± 0.30 mm, respectively, and the difference was also significant ($P < 0.05$). The relative weight of rostral colliculus in the adult was significantly ($P < 0.05$) higher than that of the neonates, but not the juveniles. The relative weight of the caudal colliculus in the adults was significantly ($P < 0.05$) higher than that of the juveniles. In conclusion, the relatively bigger caudal colliculi, than the rostral colliculi, observed at all postnatal periods studied, suggests a more acute auditory than visual ability in the African grasscutter.

Key words

Rostral colliculus, caudal colliculus, mesencephalic tectum, African grasscutter.

Introduction

Rodents, with about 2,277 species, constitute the largest number of mammalian order (Aydin et al., 2008). They occupy a wide range of niches and vary in their behavioural orientation such as daily pattern, which is either diurnal or nocturnal. The African grasscutters live above ground and are considered to be nocturnal; however, during the rainy season when sufficient security, shade and moisture are available, they are sometimes active during the day (Williams et al., 2011). Opara (2010) opined that the visual powers of the African grasscutter are relatively poor, making communication to be based mainly on hearing and well-developed sense of smell. Despite these behavioural evidences, there is paucity of information on the neural substrates responsible for the suspected better acoustic than visual ability in the rodent.

* Corresponding author. E-mail: writtechikera@yahoo.com

The mesencephalic tectum forms the dorsal surface of the adult midbrain. It is composed of a pair of rostral colliculi and a pair of caudal colliculi, collectively known as the corpora quadrigemina. The rostral colliculus in mammals (or optic lobe in birds) is present in all vertebrates, but exceptionally large in birds which have large eyes and rely on visual stimuli for much information about their environment (Bhatnagar and Bansal, 2008). It has been established that the rostral colliculus is the visual reflex centre, concerned with the coordination of reflexive movements of the head, neck and eyes, as well as focussing of the lens and visual tracking of objects (Mensah-Brown and Garey, 2006; Walton et al., 2007). The caudal colliculus is the acoustic reflex centre. It is the largest subcortical acoustic centre and the principal midbrain nucleus of the acoustic pathway (Safi and Dechmann, 2005). It receives acoustic impulse from the cochlear nuclei through the lateral lemniscus as well as motor impulse from the auditory cortex (Loftus et al., 2008). It then projects such acoustic impulse to its ipsilateral medial geniculate nucleus via the brachium of caudal colliculus. Thus, the caudal colliculus serves as an integrative station and as a switchboard, controlling the nucleus of the lower auditory pathway and motor-auditory reflex production (Tan et al., 2007). The size of the caudal colliculus has been related to the sensitivity of auditory system (Gabriele et al., 2000). Iwaniuk et al. (2006) reported that the caudal colliculus is enlarged in species using echolocation.

The rostral colliculus is bigger than the caudal colliculus in the dog and ruminant (Dellman and McClure, 1975), brown rat (Wingerd, 1988), rabbit (Bensley, 2009), camel (Mensah-Brown and Garey, 2006), calf (Schmidt et al., 2009) and donkey (Oto and Haziroğlu, 2009), while the caudal colliculus is bigger than the rostral colliculus in the pig (Getty, 1975), cetaceans (Marino et al., 2003) and African giant pouched rat (Ibe et al., 2014). The main aim of the present study was to compare the structure and size of the rostral and caudal colliculi of neonate, juvenile and adult African grasscutters, postulate a morpho-functional paradigm and compare the findings with those of other mammals.

Materials and Methods

Experimental Animals and Management

Twenty seven captive-bred African grasscutters purchased from a commercial grasscutter farm in Elele, Rivers state, Nigeria were used for the study. This comprised 9 neonates (6 days old), 9 juveniles (72 days old) and 9 adults (450 days old). They were transported by road to the Veterinary Histology Laboratory of the Michael Okpara University of Agriculture, Umudike, Abia State, Nigeria, in locally made wooden cages, with adequate ventilation, measuring 1.5 m x 1.5 m x 1.5 m. In the laboratory the grasscutters were transferred to standard laboratory animal cages and acclimated for 1 month before the experiment. They were physically examined under careful restraint. Apparently healthy ones were utilized for the study. They were fed twice daily, at 8.00 am and 6.00 pm, with fresh guinea grass (*Panicum maximum*), fresh cane grass (*Eragrostis infecunda*) and commercial rodent-pelleted concentrates. Drinking water was provided ad libitum. The feeding troughs and drinkers were sterilized daily using Milton®.

Brain Extraction and Study

The bodyweight of each animal was measured using a digital electronic balance (Citizen Scales (1) PVT Ltd. South Patel Nagar, New Delhi, sensitivity: 0.01 g). Thereafter, each animal was placed in dorsal recumbency on the dissection table and perfused, via the left ventricle, with 4% paraformaldehyde fixative, using the method of Gage et al. (2012). Immediately after the perfusion fixation, the head was separated from the rest of the body at the atlanto-axial joint, using a pair of scissors and knife. Thereafter, each skull containing the brain was obtained by skinning and stripping off all the cranial and facial muscles. Then, craniotomy preceded brain extraction. Specifically, brain extraction was performed in a caudo-rostral and dorso-ventral direction, using scalpel blades, thumb forceps and a pair of scissors. The meninges and underlying blood vessels were gently removed to expose the intact brain.

In order to obtain the mesencephalic tectum; the cerebrum was firstly separated from the rest of the brain. This was achieved by pulling the two cerebral halves at the occipital pole to expose the corpus callosum. The entire corpus callosum together with the septum pellucidum and the body and rostral commissure of the fornix were severed in the midline. This completely separated the cerebrum from the brainstem and cerebellum. To separate the mesencephalic tectum from the rest of the brainstem, an incision at the dorso-ventral mid-portion of the midbrain was made with a scalpel blade, thus separating the mesencephalic tectum from the rest of the brainstem. The structural characteristics of the corpora quadrigemina were examined with the naked eyes and with the aid of a hand lens. Photographs were taken with a digital camera (Eastman Kodak® Model 14650, Rochester, New York, U. S. A.: 12.5 megapixels). *Nomina Anatomica Veterinaria* (International Committee on Veterinary Gross Anatomical Nomenclature, 2005) were used for nomenclature.

Weights of the whole brain and the corpora quadrigemina were obtained using a Mettler balance P 1261 (Mettler instrument AG., Greifensee, Switzerland, sensitivity: 0.01 g). Dimensions of the corpora quadrigemina were obtained using a vernier caliper MG6001DC (General Tools and Instruments Co., New York, sensitivity: 0.01 cm), and converted to millimeter. The relative weight of the rostral and caudal colliculi was calculated by dividing the absolute weight of each of the colliculi by the absolute brain weight, expressed in percentage.

Statistical Analysis

Data were expressed as mean \pm standard error of the mean (SEM) and presented in tables and graphs. The values were subjected to one-way analysis of variance, followed by Tukey's post-hoc test to determine significance of the mean. The association between the values of brain weight with the weight of the rostral and caudal colliculi was determined using Pearson's coefficient of correlation, at 95% confidence interval. Values of $P < 0.05$ were considered significant. GraphPad Prism version 4 (GraphPad Software Inc., San Diego, California) for Windows 8 was used for the statistical analysis.

Results

Neonate

The mesencephalic tectum maintained its position as the roof of the midbrain. The corpora quadrigemina were bound rostrally by the 3rd ventricle and caudally by the 4th ventricle. The rostral colliculi were separated from each other by a longitudinal fissure and from the caudal colliculi by a transverse fissure. The rostral colliculus was conical in shape, but the caudal colliculus assumed a cylindrical shape. The dorsal half of the two caudal colliculi was connected by white matter tracts between the two sides, while the ventral half was separated by a fissure. The corpora quadrigemina were partly occluded by the cerebral cortex. However, the dorsal surface of the rostral colliculi and almost the entire caudal colliculi were visible from a dorsal view of the intact brain, indicative of their large sizes. Furthermore, the caudal colliculus was grossly bigger than the rostral colliculus. The geniculate bodies were visible. The lateral geniculate body was grossly bigger than the medial geniculate body. The optic nerve and tract were observed.

Juveniles

As observed in neonatal brain samples, the mesencephalic tectum still maintained its position as the roof of the mid-brain, bound rostrally by the 3rd ventricle and caudally by the 4th ventricle. The rostral and caudal colliculi also maintained their oval and cylindrical shapes, respectively. However, unlike in the neonatal brains, the rostral colliculi were not visible on the dorsal view of the intact brain as they were beneath the occipital lobe. The caudal colliculi were displaced more caudally and laterally, so that the corpora quadrigemina were observed as four distinct bodies without any fissure separating them. The white substance that connected the dorsal half of the caudal colliculi in the neonatal brain was not present at this period. The caudal colliculus was grossly bigger than the rostral colliculus, similar to the observation made from the lateral view of the midbrain in the neonates. The geniculate bodies, optic nerve and tract were also grossly visible, as observed in the neonates.

Adult

The mesencephalic tectum still maintained its position as the roof of the midbrain, bound rostrally by the 3rd ventricle and caudally by the 4th ventricle. The rostral and caudal colliculi also maintained their oval and cylindrical shapes, respectively. However, unlike in the juvenile brains, and like the neonatal brains, the rostral colliculi were visible on the dorsal view of the intact brain. Like the juvenile samples, the caudal colliculi were displaced more caudally and laterally. The caudal colliculus was grossly bigger than the rostral colliculus, similar to the observation on the lateral view of the midbrain in neonates (Figure 1: F; G). The geniculate bodies and optic nerves were also grossly visible.

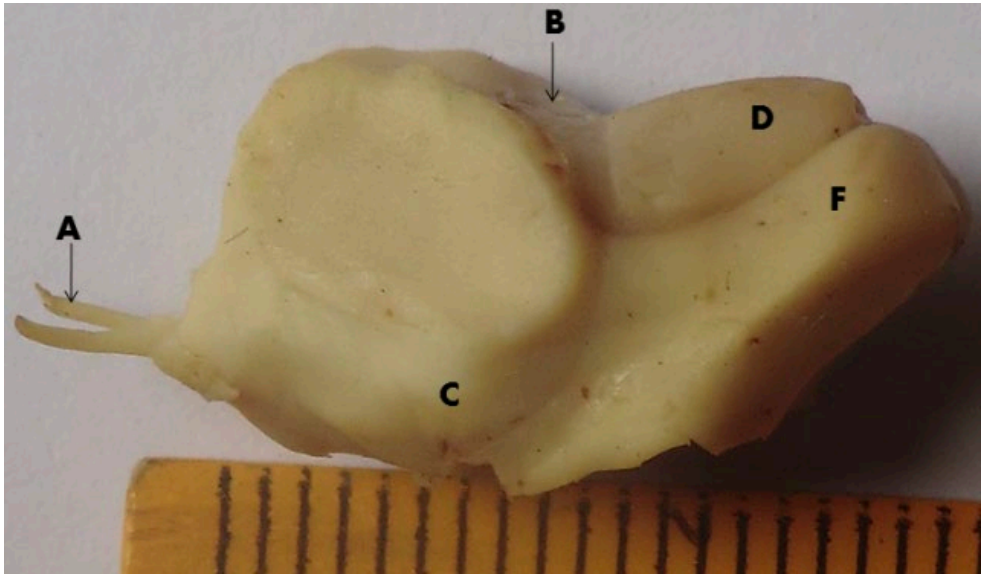


Figure 1. Lateral view of the midbrain of the adult African grasscuter. A: optic nerve; B: 3rd ventricle; C: medial geniculate body; D: rostral colliculus; E: caudal colliculus Magnification: x 4.2.

Morphometry

The mean (\pm SEM) values of the weight of the whole brain, as well as the weight and dimensions of the rostral and caudal colliculi in the neonate, juvenile and adult African grasscuter is represented in Table 1.

The absolute values of the diameter and height of the colliculi were used to compare the structures in each postnatal period (Figure 2). The differences between the diameter of the rostral and caudal colliculi as well as between the height of the rostral and caudal colliculi were significant in the neonate ($P < 0.01$), juvenile ($P < 0.001$) and adult ($P < 0.001$).

Table 1. Morphometric values (mean \pm SEM) of the whole brain and colliculi in the African grasscuter; for each column n = 9.

	Neonate	Juvenile	Adult
Whole brain weight (g)	5.21 \pm 0.15	6.77 \pm 0.04	12.22 \pm 0.23
Rostral colliculus weight (g)	0.05 \pm 0.02	0.08 \pm 0.02	0.14 \pm 0.03
Rostral colliculus diameter (mm)	2.90 \pm 0.11	3.59 \pm 0.04	4.51 \pm 0.25
Rostral colliculus height (mm)	6.38 \pm 0.28	5.94 \pm 0.21	8.08 \pm 0.35
Caudal colliculus weight (g)	0.11 \pm 0.01	0.17 \pm 0.01	0.38 \pm 0.01
Caudal colliculus diameter (mm)	3.27 \pm 0.03	4.97 \pm 0.01	6.34 \pm 0.23
Caudal colliculus height (mm)	8.78 \pm 0.08	11.45 \pm 0.17	16.16 \pm 0.30

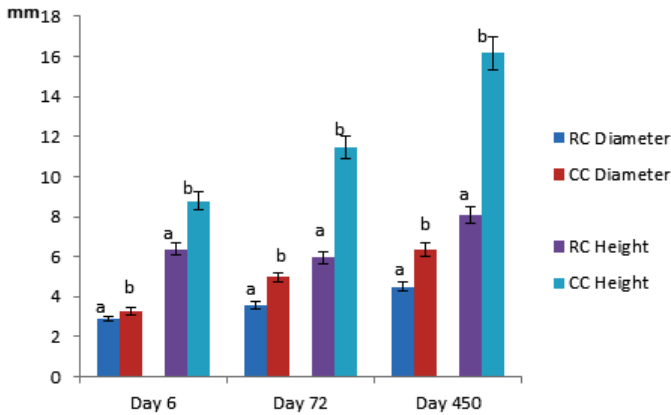


Figure 2. Diameter and height of rostral and caudal colliculi of the African grasscutter at different postnatal periods (bars indicate the standard error of the mean; n = 9 for each column). RC: rostral colliculus; CC: caudal colliculus. Columns of the same index in each period with different letters (a vs. b) are significantly ($P < 0.05$) different from each other.

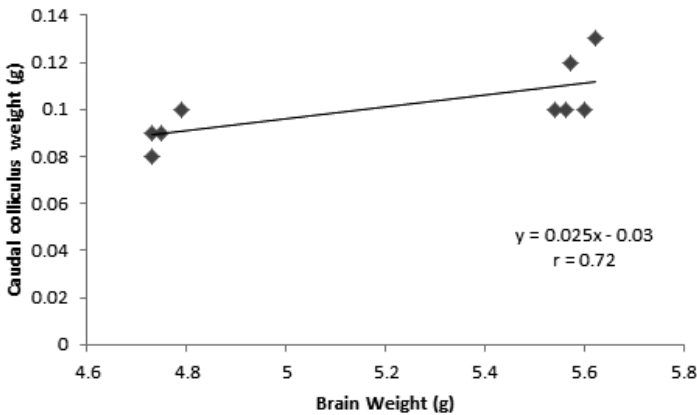


Figure 3. Positive linear relationship between brain weight and caudal colliculus weight of the African grasscutter neonate (n = 9).

There was a significant positive correlation between brain weight and weight of the caudal colliculus ($r = 0.72$; $P < 0.05$) in the neonate. This was subjected to regression analysis, and a regression formula was deduced where y represents the caudal colliculus weight and x represents the known brain weight. The graph is represented in Figure 3. Also, there was a negative correlation between the brain weight and the weight of the rostral colliculus ($r = -0.82$; $P < 0.01$) in the adult. Thus, the rostral colliculus decreased in size with an increase in the brain size. The negative correlation result was subjected to regression analysis, and a regression formula was deduced where y represents the rostral colliculus weight and x represents the known brain weight. The graph is represented in Figure 4.

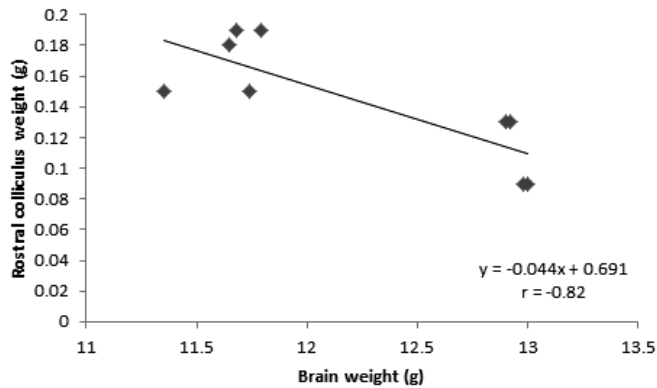


Figure 4. Negative linear relationship between brain and rostral colliculus weights of the adult African grasscutter (n = 9).

The relative weight of the rostral colliculus to the whole brain in the neonate was $0.98 \pm 0.05\%$. The value in the juvenile was $1.20 \pm 0.09\%$, which was not significantly higher than the value recorded in the neonate. The relative weight of rostral colliculus in the adult was $1.20 \pm 0.12\%$, and was not significantly higher than that of the neonates ($P < 0.05$), but not the juveniles. The relative weight of the caudal colliculus in the neonates was $2.66 \pm 0.11\%$. The value in the juvenile was $2.44 \pm 0.10\%$, while that in the adults was $3.11 \pm 0.11\%$. The decrease in the relative weight from neonate to juvenile was not significant, but the increase from juvenile to adult was significant ($P < 0.05$).

Discussion

The neural base for the relative acuity of the visual and auditory ability in the African grasscutter was tested in the present study. Gross observation and morphometric data showed that the caudal colliculus was grossly bigger and higher than the rostral colliculus at all the postnatal periods. The findings depict a better acoustic than visual ability in the African grasscutter. This is because the rostral and caudal colliculi are involved in the integration of visual and auditory impulses, respectively (Walton et al., 2007; Loftus et al., 2008; Ibe et al., 2010). Baron et al. (1996) reported that the size of the caudal colliculus reflects the hearing capacity of species better than any other brain structure.

Large caudal colliculi, relative to the rostral colliculi, have been reported in another nocturnal rodent, the African giant pouched rat (Ibe et al., 2010), and in a nocturnal aquatic mammal, the dwarf sperm whale (Marino et al., 2003). These nocturnal animals are more active at night most probably due to their poor visual capacity and better auditory capacity.

The nocturnal rodents are active at night because most of their predators are diurnal and there is less noise at night, thus they can discern the slightest movement around

them. Animals with better visual than auditory capacity are presented with bigger rostral colliculi. For example, the good eyesight of the one-humped camel has been reported by Mensah-Brown and Garey (2006), who observed that the rostral colliculi are well developed, thus inferring a better visual than acoustic ability in the animal.

The positive correlation obtained in the study implies that the size of the caudal colliculus increased at approximately the same rate as the brain size in the neonatal African grasscutter which were 6 days old. The regression formula generated can be used to estimate the weight of the caudal colliculus of the African grasscutter neonate of known brain weight. Furthermore, the negative correlation obtained implies that in the adult rodent the rostral colliculus decreased in size with an increase in the brain size. Thus, for an adult African grasscutter whose brain weight is known, the approximate weight of the rostral colliculus can be deduced from the obtained regression formula.

There are other neural substrates of the visual and auditory system, which were not subject of the present study. Some of the visual neural substrates are the ocular sensory photo-receptors, optic nerve, optic chiasma, optic tracts, lateral geniculate nucleus, oculomotor nerve nucleus, trochlear nerve nucleus and abducens nerve nucleus, while some of the auditory neural substrates are the cochlear nuclei, medial geniculate nucleus, superior olivary complex and medial trapezoid nuclei. The cyto-architecture of these nuclei and other relevant neuronal substrates needs to be investigated to further buttress the variation in the visual and auditory capacity of the African grasscutter.

In conclusion, the present research has exposed a neural base for the assumed better acoustic than visual capacity in the African grasscutter, which partly explains the nocturnal behaviour of the rodent. The study has also generated regression formulae for estimating the weight of the caudal and rostral colliculi of neonate and adult African grasscutters, respectively. It is recommended that measures to reduce noise in and around the African grasscutter pen should be adopted by farmers, as the animals may have a more acute acoustic than visual ability, thus very sensitive to noise.

Acknowledgements

The authors are grateful to the contributions of Professors S. A. Ojo (Department of Veterinary Anatomy, Ahmadu Bello University, Zaria, Nigeria), J. O. Ayo (Department of Veterinary Physiology, Ahmadu Bello University, Zaria, Nigeria) and S. O. Salami (Department of Veterinary Anatomy, University of Ilorin, Nigeria), for their leading contributions.

References

- Aydin A., Yilmaz S., Ozkan Z.E., Ilgun R. (2008) Morphological investigations on the circulus arteriosus cerebri in mole-rats (*Spalax leucodon*). *Anat. Histol. Embryol.* 37: 219-222.
- Baron G., Stephan H., Frahm H.D. (1996) *Comparative Neurobiology in Chiroptera*. Birkhauser, Basel, Switzerland. Pp. 340-355.

- Bensley B.A. (2009) Practical anatomy of the rabbit: an elementary laboratory textbook in mammalian anatomy. Accessed online from <http://bibloline.com/open-source>, 23.04.2012 06:12:46 GMT.
- Bhatnagar M.C., Bansal G. (2008) Chordata. *Columba livia*. Krishna Prakashan Media (P) Ltd., India. Pp. 327-380.
- Dellman, H. D., McClure, R. C. (1975). Ruminant nervous system. In: Sisson S., Grossmann J. D (Eds.). *The Anatomy of Domestic Animals*. W. B. Saunders Company Philadelphia. Pp. 1065-1080.
- Getty R. (1975) Sisson and Grossman's Anatomy of the Domestic Animals: 5th edn. Saunders, W. B. and Company, Philadelphia, London, Toronto.
- Gabriele M.L., Brunso-Bechtold J.K., Henkel C.K. (2000) Plasticity in the development of afferent patterns in the caudal colliculi of the rat after unilateral cochlear ablation. *J. Neurosci.* 20: 6939-6949.
- Gage G.J., Kipke D.R., Shain W. (2012) Whole animal perfusion fixation for rodents. *J. Vis. Eexp.* 65: e3564.
- Ibe C.S., Onyeanusi B.I., Ayo J.O., Salami S.O., Ajayi I.E. (2010) Preliminary neuroanatomical study of the visual and auditory senses in the African giant pouched rat (*Cricetomys gambianus* Waterhouse-1840). In: Babayemi O. J., Abu O. A., Ewuola E. O. (Eds.). *Proc. 35th Annual Conference Nigeria Society for Animal Production*. Ibadan, Oyo, Nigeria. Pp. 134-137.
- Ibe C.S., Onyeanusi B.I., Hambolu J.O. (2014) Functional morphology of the brain of the African giant pouched rat (*Cricetomys gambianus*, Waterhouse, 1840). *Onderstepoort J. Vet. Res.* 81: Art. #644.
- Iwaniuk A.N., Clayton D.H., Wylie R.W. (2006) Echolocation, vocal learning, auditory localisation and the relative size of the avian auditory midbrain nucleus (MLd). *Behav. Brain Res.* 167: 305-317.
- Loftus W.C., Malmierca M.S., Deborah C., Bishop D.C., Olive D.L. (2008) The cytoarchitecture of the caudal colliculus revisited: a common organization of the lateral cortex in rat and cat. *Neuroscience* 154: 196-205.
- Marino L., Sudheimer K., Pabst D.A., McLellan W.A., Johnson J.I. (2003) Magnetic resonance images of the brain of a dwarf sperm whale (*Kogia simus*). *J. Anat.* 203: 57-76.
- Mensah-Brown E.P.K., Garey L.J. (2006) The superior colliculus of the camel: a neuronal-specific nuclear protein (NeuN) and neuropeptide study. *J. Anat.* 208: 239-250.
- International Committee on Veterinary Gross Anatomical Nomenclature (2005) *Nomina Anatomica Veterinaria*. 5th Edition. Hannover, Columbia.
- Opara M.N. (2010) Grasscutter I: a livestock of tomorrow. *Res. J. For.* 4: 119-135.
- Oto C., Hazirolu R.M. (2009) Macro-anatomical investigation of encephalon in donkey. *Ankara Üniv. Vet. Fak. Derg.* 56: 159-164.
- Safi K., Dechmann D.K.N. (2005) Adaptation of brain regions to habitat complexity: a comparative analysis in bats (*Chiroptera* sp). *Proc. R. Soc. London* 272: 179-186.
- Schmidt M.J., Pilatus U., Wigger A., Kramer M., Oelschläger H.A. (2009) Neuroanatomy of the calf brain as revealed by high-resolution magnetic resonance imaging. *J. Morphol.* 270: 745-758.
- Tan M.L., Theeuwes H.P., Feenstra L., Borst, J.G.G. (2007) Membrane properties and firing patterns of caudal colliculus neurones: An in-vivo patch-clamp study in rodents. *J. Neurophysiol.* 98: 443-453.

- Walton M.M.G., Bechara B., Gandhi N.J. (2007) Role of primate superior colliculus in the control of head movements. *J. Neurophysiol.* 98: 2022-2037.
- Williams O.S., Ola S.I., Boladuro B.A., Badmus R.T. (2011) Diurnal variation in ambient temperature and humidity in a pit pen grass-cutter (*Thryonomys swinderianus*) house in Ile- Ife. *Proc. 36th Annual Conference Nigerian Society for Animal Production, Abuja, Nigeria.* Pp. 111-113.
- Wingerd B.D. (1988) *Rat Dissection Manual.* John Hopkins University Press, Baltimore, London.