

Research article - Human anatomy case report

## **Double inferior vena cava with variant hemiazygos vein – a case report**

Sumathilatha Sakthi Velavan\*, Bedia Castellanos, Sushama Rich, Robert Goldberg

Department of Anatomy, Touro College of Osteopathic Medicine, Harlem, New York, NY – 10027

### Abstract

The duplication of the inferior vena cava is a rare variation resulting from an alteration in the embryogenesis of the cardinal venous system. Although there are various types of double inferior vena cava and is prevalent in 2-3% of the population, the continuation of left inferior vena cava as hemiazygos vein is a very unusual variant and hence this case is reported for its rarity and clinical significance. During dissection of an eighty-seven-year-old female cadaver, the presence of the double inferior vena cava was noted. A detailed dissection was done of the major veins of the abdomen and traced till their drainage into the thorax. The right and left inferior vena cava were connected by a venous bridge which coursed deep to the abdominal aorta. The right inferior vena cava followed its usual course and drained into the right atrium, while the left inferior vena cava entered the thoracic cavity as the hemiazygos vein and drained into the azygos vein. Anatomical knowledge of the rare variant prevents misdiagnosis and aids in the proper interpretation of radiological images. Also, awareness of this vascular anomaly guides the surgeons during retroperitoneal procedures when encountering intraoperative difficulties.

### Key words

Duplication, inferior vena cava, double IVC, azygos vein, hemiazygos vein.

### Introduction

The duplication of the inferior vena cava (IVC) has been reported to occur in 2 to 3% of the population (Spentzouris et al., 2014). The inferior vena cava is usually the single largest vein draining the blood from the lower part of the body and is on the right side. The complexity of the development of inferior vena cava explains the multiple variations associated with the venous system (Chuang VP et al., 1974; Bass et al., 2000). These variations are usually asymptomatic, although they have significant clinical implications in certain radiological and surgical settings (Nishibe et al., 2004; Ang et al., 2013). The failure of regression of the left supracardinal vein results in the formation of the double IVC. In most cases of double IVC, the left IVC crosses over to the right side and drains into the right IVC (Bass et al., 2000). This case is a very rare variant of the double IVC, and it deserves embryological reasoning and clinical correlation.

\* Corresponding author. E-mail: sumathilatha.sakthi-velavan@touro.edu

## Materials and methods

During the posterior abdominal wall dissection of an eighty-seven-year-old female cadaver, an abnormal vein (left IVC) was found to the left of the abdominal aorta. The vein was traced proximally and distally. The common iliac veins were dissected out and the formation of the right and left IVC were noted. The diaphragm was dissected, and the right IVC was traced to its termination in the right atrium. The azygos vein and the hemiazygos vein were dissected up to their termination. The veins and arteries were painted with acrylic tube paints (Trade name - Reeves) in ultramarine blue and crimson red colors and photographed.

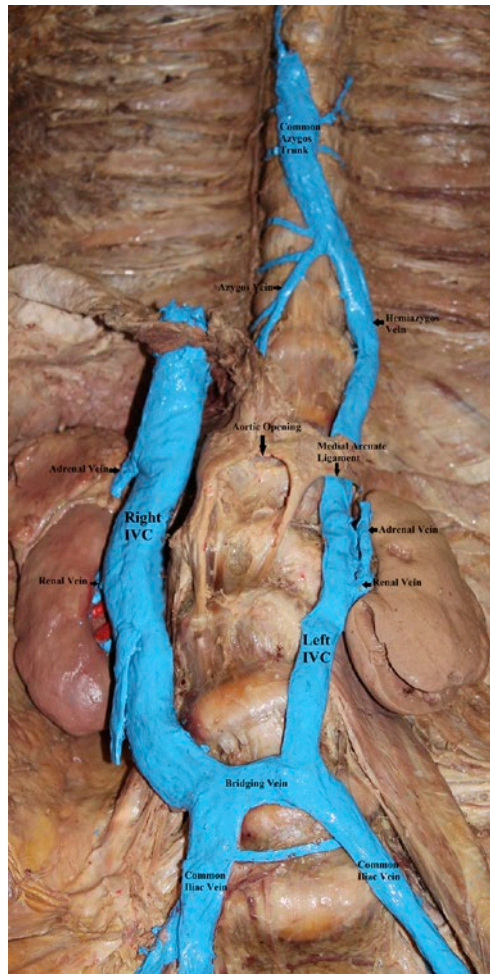
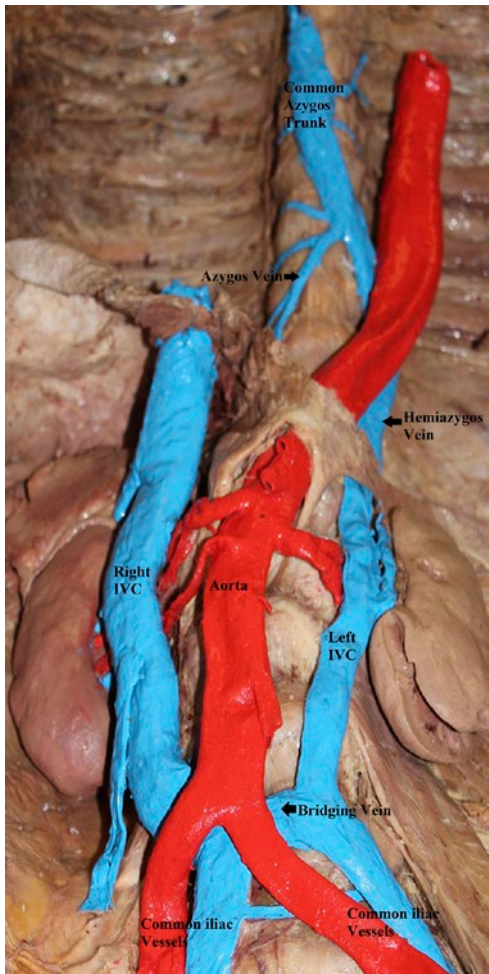
## Results

The right IVC was in line with the right common iliac vein, and the left IVC was in continuity with the left common iliac vein. The right IVC was larger than the left. There was a bridging vein at the level of L4 (fourth lumbar vertebra) that coursed posterior to the abdominal aorta (Figures 1, 2). There was another small vein at the level of L5 bridging the two common iliac veins. The right renal, gonadal and the suprarenal veins drained into the right IVC. The right IVC entered the diaphragm through the normal IVC opening in the central tendon and opened into the right atrium. The left IVC ascended to the left of the abdominal aorta and continued as the hemiazygos vein. The left renal vein was shorter since it drained into the left IVC. The left gonadal and the left suprarenal veins drained into the left renal vein. The hemiazygos vein passed posterior to the medial arcuate ligament of the diaphragm and entered the thoracic cavity.

The azygos vein was smaller than the hemiazygos vein. At the level of T8 (Eighth thoracic vertebra), the hemiazygos vein united with the azygos vein to form the common azygos trunk. The common azygos trunk drained into the superior vena cava at the level of T3. There was no accessory hemiazygos vein. The 5th, 6th, and 7th left posterior intercostal veins (PICV), the right superior intercostal vein, and the 5th to 8th right PICVs drained into the common azygos trunk. The 8th to 11th left PICVs and the left subcostal vein drained into the hemiazygos vein. The 9th to 11th right PICVs and the right subcostal vein drained into the azygos vein. The 1st to 4th posterior intercostal veins followed the normal course and termination on both the sides.

## Discussion

The embryogenesis of IVC involves the development, anastomosis, and regression of three pairs of the complex system of veins from the sixth week to the tenth week of intra-uterine life. They are posterior cardinal, supracardinal and subcardinal veins (Figure 3). The common iliac veins and the anastomosis between the common iliac veins develop from the posterior cardinal veins. The infrarenal segment of the IVC develops from the right supracardinal vein. The renal segment develops from the supra-subcardinal anastomosis. The suprarenal segment develops from the right subcardinal vein. The hepatic segment develops from the vitelline vein. The intersubar-

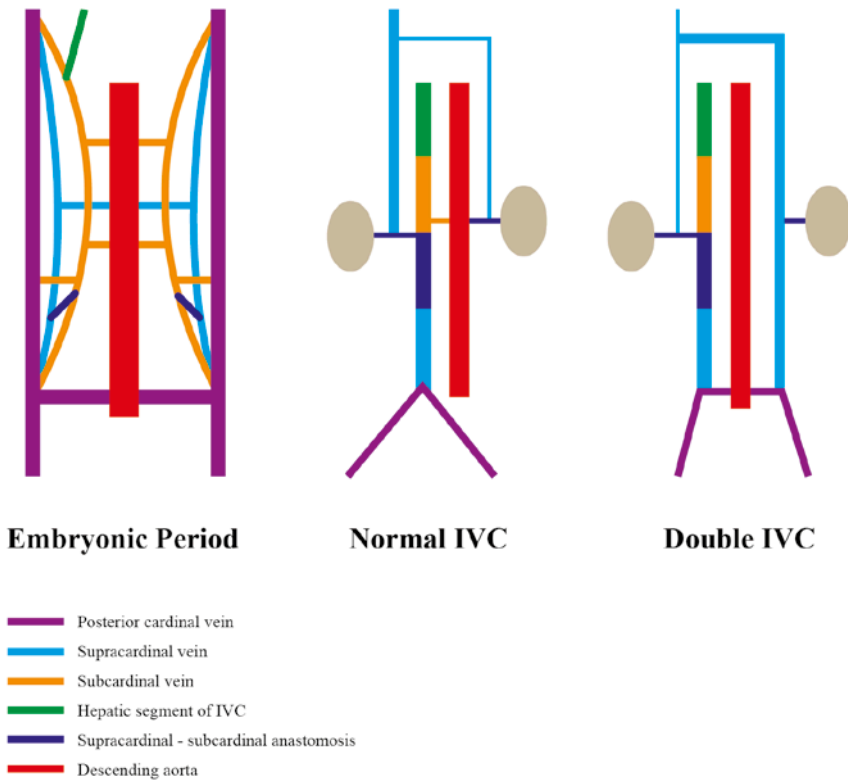


**Figure 1** – The image shows the duplication of IVC and the relationship between the veins and the abdominal aorta.

**Figure 2** – The image shows the large veins, their course, and tributaries after the removal of the abdominal aorta.

dinal anastomosis and the left supra-subcardinal anastomosis remain as the left renal vein. The suprarenal portion of the supracardinal veins on both the sides gets disconnected from the infrarenal part and continues as the azygos and the hemiazygos veins. All the other parts of this venous system disappear (Chuang et al., 1974).

The variations of IVC have been classified into four types based on its development: Anomalies of the posterior cardinal veins, subcardinal veins, supracardinal veins and renal segment (Chuang et al., 1974). The present case resulted from the abnormal persistence of the entire extent of left supracardinal vein (Figure 3). The infrarenal segment of the left supracardinal vein was represented by the left IVC, and the suprarenal portion of the left supracardinal vein was represented by the hemiazy-



**Figure 3** – The image is a schematic representation of the development of inferior vena cava and the embryological reasoning of the variation noted in this case.

gos vein. Various abnormalities have been reported in associated with the double IVC some of them being, congenital heart disease, congenital absence of right kidney, rectal ectopia, right retrocaval ureter and transcaval ureter (Spentzouris et al., 2014) but none of those variations were noted in the present case.

Duplication of the IVC may be asymmetric (in part) or symmetric (in total) (Spentzouris et al., 2014). The most common variant is the union of the left IVC with the left renal vein and its drainage into the right IVC (Peter et al., 2009). Usually, it joins the right IVC in front or behind the aorta at the level of or just above the left renal vein and occasionally at a lower level (Mayo et al., 1983). The present case showed an extremely rare variant of the left IVC continuing as the hemiazygos vein in the presence of a normal right IVC.

The larger of the two vessels of double IVC is called as the dominant vein. In many instances as this case, the right vena cava is dominant (Mathews et al., 1999). A case closely similar to this had a non-dominant right IVC, and the hemiazygos vein drained into a persistent left-sided superior vena cava (Brochert and Reynolds, 2001). While the present case showed a normal course and drainage of the right IVC, variations have been noted in the past. Two case reports showed azygos continua-

tion of the right IVC (Mayo et al., 1983; Soltes et al., 1992) and another had a right IVC drained by the retro-aortic right renal vein that opened into left IVC (Bass et al., 2000). The absence of accessory hemiazygos vein noted in this case was reported in 15% of the cases (Silveira et al., 2012).

Pelvic venous variations of double IVC are classified into five types. Although the most common type is a double IVC with no interiliac communication (about 40%) (Yagi et al., 2014), in this case, the connection was present. Abnormal veins can be dilated and tortuous, and therefore blood flow can be altered. This increases the chances of thromboembolic events (Eldefrawy et al., 2011). The success of IVC filter is affected by this variation since it still provides a pathway for recurrent pulmonary emboli from the lower extremity (Yagi et al., 2014). Hence separate filters are needed for both IVCs.

Radiologically, double IVC can be mistaken as a pathological lesion such as retroperitoneal lymphadenopathy or left pyelo-ureteric dilation (Ng and Ng, 2009). The abnormally large hemiazygos vein was misdiagnosed as mediastinal mass, and percutaneous biopsy had been attempted in the past (Eldefrawy et al., 2011).

Preoperative diagnosis of the anomalies would reduce the complication rate of the abdominal aortic operations. In donor nephrectomy, the left renal vein is usually preferred because it is long. However, the short left renal vein associated with this variant may lead to serious technical difficulties (Yagi et al., 2014). Besides, misidentifying a double IVC as a large tributary of the renal vein could be dangerous for the donor, if it were to be ligated (Peter et al., 2009). At times, a double IVC has been mistaken for an abnormal form of a gonadal vessel and ligated (Gupta et al., 2002). The venous variation noted may pose technical difficulties during retroperitoneal surgeries by complicating dissection and increasing the risk of hemorrhage (Aljabri et al., 2001, Ang et al., 2013).

The double IVC with the hemiazygos continuation of the left IVC is an uncommon and clinically significant variation that may be incidentally diagnosed during imaging procedures. The knowledge of this variation will aid in the preoperative diagnosis and will enable appropriate surgical planning. It will also avoid misinterpretation such as mediastinal lymphadenopathy or para-aortic mass and the hence dangerous biopsy could be prevented. This case is brought into light to report a rare variation and to add knowledge to the atypical clinical presentations.

## Acknowledgement

The authors thank their colleagues Carlos Quinteros and Ramona Baez for their support and also thank Nicholas Vanterpool and Ali Khan from the Department of Anatomy, Touro College of Osteopathic Medicine for their technical assistance.

## References

- Aljabri B., MacDonald P.S., Satin R., Stein L.S., Obrand D.I., Steinmetz O.K. (2001) Incidence of major venous and renal anomalies relevant to aortoiliac surgery as demonstrated by computed tomography. *Ann. Vasc. Surg.* 15: 615–618.

- Ang W.C., Doyle T., Stringer M.D. (2013) Left-sided and duplicate inferior vena cava: A case series and review. *Clin. Anat.* 26: 990–1001.
- Bass J.E., Redwine M.D., Kramer L.A., Huynh P.T., Harris J.H. (2000) Spectrum of congenital anomalies of the inferior vena cava: Cross-sectional imaging findings. *Radiographics.* 20: 639-651.
- Brochert A., Reynolds T. (2001) Unusual duplication anomaly of the inferior vena cava with normal drainage of the right IVC and hemiazygous continuation of the left IVC. *J. Vasc. Interv. Radiol.* 12: 1453-1455.
- Chuang V.P., Mena C.E., Hoskins P.A. (1974) Congenital anomalies of the inferior vena cava. Review of embryogenesis and presentation of a simplified classification. *Br. J. Radiol.* 47: 206-213.
- Eldefrawy A., Ariyanayagam M., Kanagarajah P., Acosta K., Manoharan M. (2011) Anomalies of the inferior vena cava and renal veins and implications for renal surgery. *Central European Journal of Urology.* 64: 4-8.
- Gupta R.S., uz Zamman W., Srivastava A., Kumar A. (2002) Duplication of the inferior vena cava: Clinical implication during live donor nephrectomy and the role of preoperative CT angiography. *Indian J. Urol.* 18: 164–166.
- Mathews R., Smith P.A., Fishman E.K., Marshall F.F. (1999) Anomalies of the inferior vena cava and renal veins: Embryologic and surgical considerations. *Urology.* 53: 873–880.
- Mayo J., Gray R., St. Louis E., Grosman H., McLoughlin M., Wise D. (1983) Anomalies of the inferior vena cava. *A.J.R.* 140: 339-345.
- Ng W.T., Ng S.S.M. (2009) Double inferior vena cava: a report of three cases. *Singapore md. J.* 50: 211-213.
- Nishibe T., Sato M., Kondo Y., Kaneko K., Muto A., Hoshino R., Kobayashi Y., Yamashita M., Ando M. (2004) Abdominal aortic aneurysm with left-sided inferior vena cava. Report of a case. *Int. Angiol.* 23: 400–402.
- Peter T.K., Saidi R.F., Markmann J.F., Ko D.S.C., Kawai T., Yeh H. (2009) Duplicated inferior vena cava – something to consider in the evaluation of a living donor renal transplant. *Dialysis and Transplantation* 38: 420-422.
- Silveira D., Sousa L.M., Siqueira S.L., Oliveira B.V.M., Silva A.T., Costas J.P., Araujo D.C., Costa G.A.R., Araujo B.A. (2012) Anatomic variation of thorax drainage: Absence of accessory hemiazygos vein. *J. Morphol. Sci.* 29: 94-95.
- Soltes G.D., Fisher R.G., Whigham C.J. (1992) Placement of dual birds nest filters in an unusual case of duplicated inferior vena cava. *J.V.I.R.* 3: 709-711.
- Spentzouris, G., Zandian, A., Cesmebasi, A., Kinsella, C. R., Muhleman, M., Mirzayan, N., Shirak, M., Tubbs, R. S., Shaffer, K. and Loukas, M. (2014) The clinical anatomy of the inferior vena cava: A review of common congenital anomalies and considerations for clinicians. *Clin. Anat.* 27: 1234–1243.
- Yagi S., Oba K., Koyama K., Fukushita T., Fujisawa H., Kushihashi T., Ito H., Sako M., JP Y., JP K., JP K. (2014) A case-based review of the inferior vena cava anomalies: what radiologists should know. URL: [http://postereng.netkey.at/esr/viewing/index.php?module=viewing\\_poster&task=&pi=121617](http://postereng.netkey.at/esr/viewing/index.php?module=viewing_poster&task=&pi=121617) [Accessed March 2015].