

Letter - Basic and applied anatomy

## Association between hepatic surface grooves and diaphragmatic slips

 Shamir O. Cawich<sup>1\*</sup>, Michael T. Gardner<sup>2</sup>, Neil W. Pearce<sup>3</sup>, Ramanand Shetty<sup>2</sup>, Vijay Naraynsingh<sup>1</sup>

<sup>1</sup>Department of Clinical Surgical Sciences, University of the West Indies, St. Augustine Campus, St. Augustine, Trinidad & Tobago; <sup>2</sup>Section of Anatomy, Basic Medical Sciences, University of the West Indies, Mona Campus, Kingston 7, Jamaica; <sup>3</sup>University Surgical Unit, Southampton General Hospital, Southampton, United Kingdom

### Key words

Liver, diaphragm, laparoscopy.

Dear Sir,

We recently reported on the features of hepatic surface grooves (HSG) during a series of cadaveric dissections (Gardner et al., 2015). When we examined the relationships of the HSGs in situ, we noted that the corresponding diaphragmatic surfaces appeared normal in all cases. None of the specimens had associated areas of muscular thickening, scarring, fibrotic bands or slips in the diaphragm. The coronary, triangular and falciform ligaments were normal in all cases. Therefore, we concluded that *“these data did not support [indentation from diaphragmatic slips as] the prevailing theory to explain HSG formation”* as proposed Macchi et al (2003).

However, as clinicians, we have had the opportunity to treat patients with HSGs for a variety of clinical diseases. The increasing popularity of laparoscopic surgery in our setting has allowed an unimpeded view of the relationships of the liver and diaphragm in vivo. In living patients, we have often observed the presence of projections arising from the diaphragm that correspond to HSGs, when present.

Recently we treated a patient in whom there were projections on the surface of the diaphragm that bore a clear spatial relationship to the direction, length and number of corresponding HSGs. The relationship was detectable on plain radiographs (Figure 1) and was correlated with laparoscopic surgery (Figure 2). This was our first opportunity to correlate the radiologic and operative findings in a living person with HSGs. To the best of our knowledge this is also the first time that intra-operative pictures were captured in a person with diaphragmatic projections and corresponding HSGs.

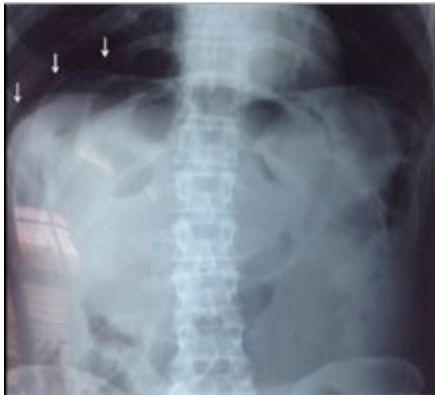While we agree that this finding alone cannot validate the theory, at the very minimum it forces us to re-think the diaphragmatic slip theory. Macchi et al (2003) proposed that there were weak areas on Glisson’s capsule that offered little resistance to external pressure. Diaphragmatic slips were proposed as one source of external pressure that could create HSGs (Macchi et al., 2003; Macchi et al., 2005; Joshi et al., 2009). However, in our series of dissections in unselected cadavers we did not observe any diaphragmatic projections (Gardner et al., 2015).

\* Corresponding author. E-mail: socawich@hotmail.com

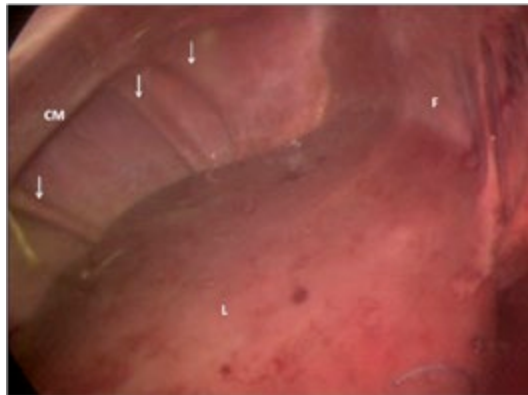
Yet, in living patients from the same Caribbean population, these projections were often observed. Initially, we postulated that the projections could be due to dynamic effects of diaphragmatic contraction that would not be seen post-mortem. However, we admit that this theory could be challenged by the fact that neuro-muscular blockers are routinely administered during laparoscopic surgery to induce skeletal muscle paralysis in order to provide space to operate. This should prevent contraction of the diaphragmatic fibres during laparoscopy. This theory, therefore, would only be plausible if there was incomplete neuromuscular relaxation during laparoscopic surgery. In the event of incomplete neuromuscular blockade, there would be high pneumoperitoneum pressures and high ventilator pressures. Additionally, we would have expected to visualize changes in the projections during contraction-relaxation cycles as the patient attempted to breathe. Unfortunately, these three parameters were not recorded intra-operatively. Therefore, we were not able to accurately correlate the adequacy of relaxation and the presence of projections in the diaphragm. But, these parameters can be used in future clinical studies as a proxy of complete neuromuscular relaxation.

Some authors have suggested that HSGs are post-mortem changes due to continuous compression from the chest wall (Auh et al., 1984; Newell and Morgan-Jones, 1993; Ono et al., 2000). They suggest that the increased frequency of HSGs in cadaveric studies supports the post-mortem compression theory (Muktyaz et al., 2013; Ono et al., 2000; Auh et al., 1984; Newell and Morgan-Jones, 1993). However, we observed the opposite relationship in our clinical experience.

The projections were oriented vertically, emanating radially from the central tendon to the costal margin. This is clearly demonstrated in the plain radiographs and the intra-operative pictures presented (Figures 1 and 2). We believe that this finding challenges the theory that HSGs are due to external compression by ribs (Newell and Morgan-Jones, 1993; Muktyaz et al., 2013; Ono et al., 2000) because the ribs are in a transverse orientation over the hepatic surface area.



**Figure 1** – Plain abdominal radiograph demonstrating vertically oriented radio-opaque shadows (arrows) within the right hemi-diaphragm. These areas corresponded to the projections observed at laparoscopic surgery.



**Figure 2** – Intra-operative view at laparoscopic surgery. The liver (L), falciform ligament (F) and costal margin (CM) can be used to orient the views. The white arrows demonstrate the projections in the diaphragm that are visible on plain radiographs.

In summary, we were unable to find a satisfactory explanation for the discordance between cadaveric dissections and our observations in living patients in the same Caribbean population. There is a possibility that these may be due to dynamic effects of diaphragmatic contraction, but this requires further investigation. We wish to stimulate discussion and encourage larger, well-designed clinical studies that could take into account the effect of neuromuscular blockers on diaphragmatic projections in living patients with HSGs.

## References

- Auh Y.H., Rubenstein W.A., Zirinsky K., Kneeland J.B., Pardes J.C., Engel I.A., Whalen J.P., Kazam E. (1984) Accessory scissures of the liver: CT and sonographic appearance. *Am. J. Roentgenol.* 3: 565-572.
- Gardner MT, Cawich SO, Shetty R, Pearce NW, Naraynsingh V. (2015) Hepatic surface grooves in an Afro-Caribbean population: a cadaver study. *Ital. J. Anat. Embryol.* 120:117-126.
- Joshi S.D., Joshi S.S., Athavale S.A. (2009) Some interesting observations on the surface features of the liver and their clinical implications. *Singapore Med. J.* 50: 715-719.
- Macchi V., Feltrin G., Parenti A., De Caro R. (2003) Diaphragmatic sulci and portal fissures. *J. Anat.* 202: 303-308.
- Macchi V., Porzionato A., Parenti A., Macchi C., Newel R., DeCaro R. (2005) Main accessory sulcus of the liver. *Clin. Anat.* 18: 39-45.
- Muktyaz H., Nema U., Suniti M.R., Mahboobul H. (2013) Anatomical study of accessory sulci of liver and its clinical significance in North Indian population. *Int. J. Med. Health Sci.* 2: 222-229.
- Newell R.L.M., Morgan-Jones R. (1993) Grooves in the superior surface of the liver. *Clin. Anat.* 6: 333-336.
- Ono M.L., Murakami G., Sato T.J., Sawada K. (2000) Hepatic grooves and portal segmentation. *Kaibogaku Zasshi.* 75: 517-523.