

Research article - Human anatomy case report

An anatomic variant causing a previously unreported complication of transcutaneous treatment of trigeminal neuralgia

R. Shane Tubbs^{1*}, Kimberly P. Kicielski², Joel Curé³, Benjamin J. Ditty², Barton L. Guithrie²

¹Seattle Science Foundation, Seattle, WA and Departments of ²Neurosurgery and ³Neuroradiology, University of Alabama, Birmingham, AL

Abstract

This case report describes a patient with an anatomic variant of the foramen ovale that was encountered during an attempted glycerol rhizolysis for trigeminal neuralgia. Various complications have been reported during transcutaneous trigeminal neuralgia treatment. We report an adult female on whom transcutaneous cannulation of the foramen ovale was not possible. Subsequent imaging revealed a causative elongation of the spine of the sphenoid that distorted the foramen ovale and effectively blocked it. Variations in bony anatomy may complicate transcutaneous approaches to the foramen ovale for the treatment of trigeminal neuralgia.

Key words

Skull base, trigeminal nerve, pain syndromes, neurosurgery, foramen ovale, spine of sphenoid, anatomy

Introduction

Trigeminal neuralgia can be a life altering problem and probably has several etiologies. Transcutaneous methods for accurately identifying the foramen ovale (Fig. 1) for the placement of needles (for injection of various neurotoxic substances), radiofrequency thermocoagulation probes and compressive balloons into the trigeminal cistern have been used for the treatment of trigeminal neuralgia, including stereotactic frames, CT-guided techniques, image-guided fluoroscopy, and plain radiographs (Browsher, 1997; Taha and Tew, 1997). In general, complications from such procedures include dysesthesia, transient bradycardia, corneal ulceration, and recalcitrant facial pain (Taha and Tew, 1997). Herein, we report a very unusual complication from an enlarged spine of the sphenoid bone that resulted in abandoning a transcutaneous procedure for the treatment of trigeminal neuralgia.

Case report

A 41-year-old African American female presented with the acute onset of severe, lancinating left jaw pain while chewing in January of 2011. The pain was exacerbated

* Corresponding author. E-mail: shane.tubbs@childrensal.org

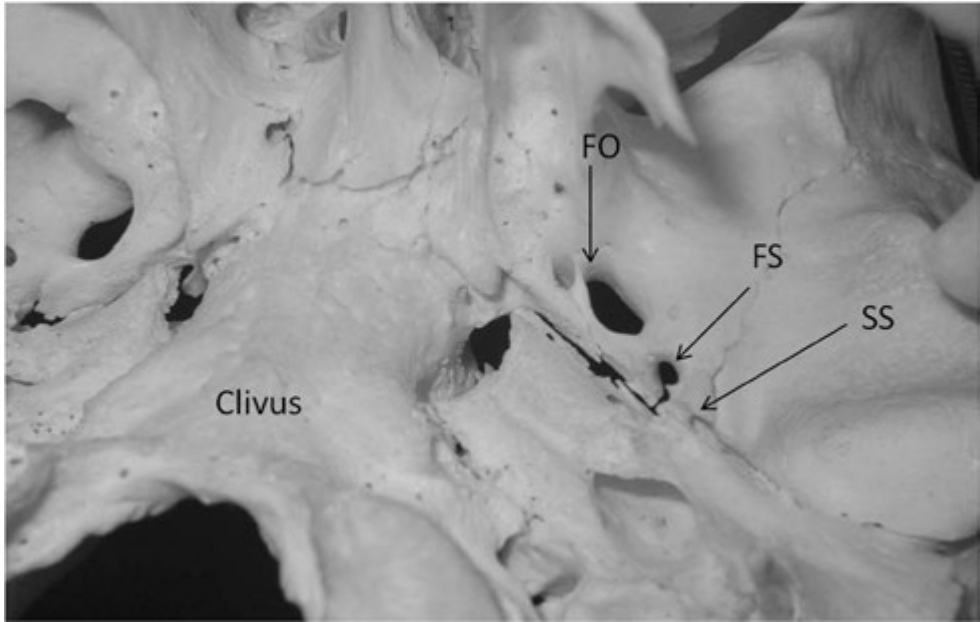


Figure 1 – Dry skull specimen illustrating the normal anatomy of the left sphenoid spine (SS). For reference, note the clivus, left foramen ovale (FO) and left foramen spinosum (FS).

by drafts, extreme temperature, palpation of the face, as well as speaking and swallowing. She described the pain primarily under her left eye, jaw, and extending to the left tongue. Though she noted the pain originated acutely in January, her medical record indicates several emergency department visits for discrete episodes of self-limited left jaw and neck pain dating back to April 2011. She underwent diagnostic work up with non-contrast computerized tomography of the head and magnetic resonance imaging of the brain with and without contrast as well as magnetic resonance angiography which were unrevealing for intracranial pathology, specifically no demyelinating or inflammatory lesions were identified. She was evaluated by neurologists and diagnosed with trigeminal neuralgia. Her face pain was refractory to medical treatment with carbamazepine, baclofen, gabapentin, and pregabalin. She was then referred to the neurosurgery service in May 2012 where surgical intervention with glycerol rhizolysis, microvascular decompression, or gamma knife stereotactic radiosurgery were discussed. The patient opted for glycerol rhizolysis. Following alcohol skin prep and initiation of monitored anesthesia, a spinal needle was inserted 1 centimeter lateral and below the left corner of the mouth and directed towards the foramen ovale. Jaw jerk and patient wince correlated with fluoroscopic evidence of penetration of the region of the V₃ branch of the trigeminal nerve. Iohexol contrast was injected through the spinal needle under live fluoroscopy, revealing the spinal needle not to have penetrated the foramen ovale. Four attempts were made to access the foramen ovale before the procedure was aborted. Post-procedural imaging noted bilateral enlargement and elongation of the spine of the sphenoid bones that caused

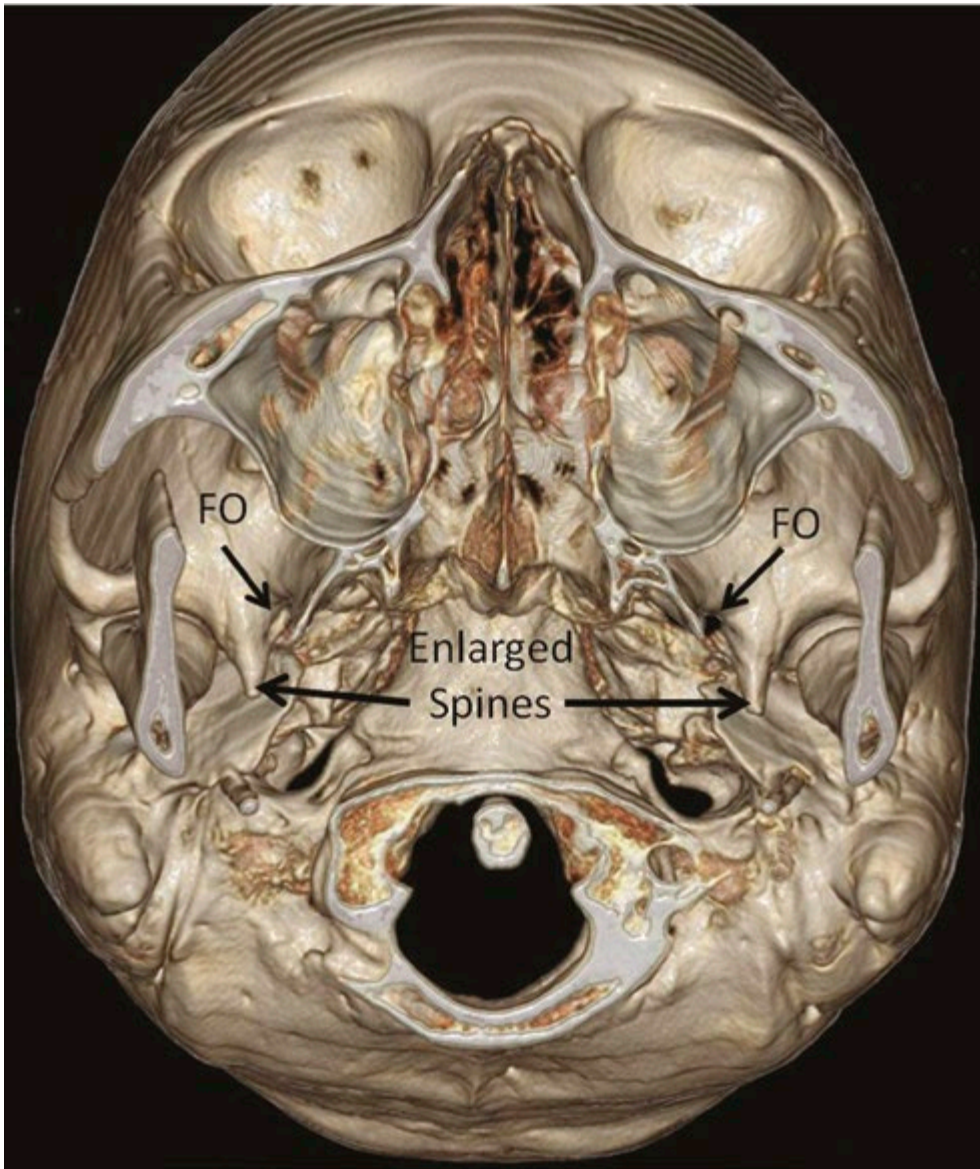


Figure 2 – 3D reconstructed CT of the skull base from the patient presented herein. Not the enlarged spines of the sphenoid and bilateral foramina ovalia (FO). The ipsilateral foramen ovale is deformed and effectively blocked by the sphenoid spine elongation when a needle is advanced in the typical anterolateral approach used in transcutaneous approaches to treat trigeminal neuralgia.

deformation of the foramen ovale and effectively blocked this structure from the approaching transcutaneous needle (Fig. 2).

Discussion

Typical needle pathways used for transfacial transcutaneous approaches to the foramen ovale include a skin insertion 2 to 3 cm lateral to the corner of the mouth aimed at the medial aspect of the ipsilateral pupil in the left-right plane and at a point 2.5 cm anterior to the tragus in the anteroposterior and superior-inferior planes. This takes the needle along a pathway toward the junction of the medial and inferior walls of the orbit, 0.5 cm anterior to the condyle of the mandible and aimed at a point 1 cm behind the posterior clinoid along the angle of the clivus (Browsher, 1997). A needle entry site that is too medial results in the placement of its tip lateral to the foramen ovale, and a needle entry site that is too lateral results in the placement of the needle medial to the foramen ovale.

The spine of sphenoid bone is an irregularly shaped projection originating from the posterolateral edge of the greater wing just lateral. Placed just lateral to the foramen spinosum and posterolateral to the foramen ovale, the spine of sphenoid is an attachment site for the sphenomandibular and pterygospinous ligaments. The sphenomandibular ligament widens as it descends and attaches to the lingula of the mandibular foramen. Along with the stylomandibular ligament and temporomandibular ligament, these support the temporomandibular joint. The pterygospinous ligament connects the posterior border of the lateral pterygoid plate to the spine of sphenoid. The chorda tympani and auriculotemporal nerves travel medial to the spine of the sphenoid. Both these nerves are at risk of damage in cases of fracture of the spine of the sphenoid with resultant loss of salivary gland innervation and taste on the anterior two-thirds of the tongue and sensory loss anterior and superior to the tragus.

With the mandibular branch of the trigeminal nerve coursing through the foramen ovale and Meckel's cave being a site for treatment of trigeminal neuralgia through transcutaneous injections, understanding the anatomy and possible causes of obstruction to the site is important for clinicians to take into account before and during the procedure. Included as a cause of obstruction of the foramen ovale are bony bars. For example, ossification of the pterygospinous ligament creates a foramen through which the mandibular segment of the trigeminal nerve travels before innervating the masseter, temporalis and lateral pterygoid muscles. These foramina have been shown as a possible cause of obstruction and increased difficulty of access to the foramen ovale for percutaneous injections and possible compression of the mandibular branch of the trigeminal nerve (Tubbs et al., 2009). Ossification of either the pterygospinous or stylomandibular ligament could result in an enlarged spine of the sphenoid causing obstruction in the foramen ovale.

To our knowledge, obstruction of the foramen ovale due to an enlarged spine of the sphenoid bone has not been described. Although apparently very rare, such a cause may be considered by the neurosurgeon during procedures where the foramen ovale cannot be entered via a transcutaneous route. In our case, the elongation distorted the normal anatomical position of the foramen ovale and effectively blocked it from the typical anterolateral transcutaneous approach used to treat trigeminal neuralgia.

Ethics

This study complies with ethical standards of the United States. The authors deny any conflict of interest.

References

- Bowsher D. (1997) Trigeminal neuralgia: an anatomically oriented review. *Clin. Anat.* 10: 409-415.
- Taha J.M., Tew J.M. Jr. (1997) Treatment of trigeminal neuralgia by percutaneous radiofrequency rhizotomy. *Neurosurg. Clin. N. Am.* 8: 31-39
- Tubbs R., May W.R. Jr, Apaydin N., Shoja M.M., Shokouhi G., Loukas M., Cohen-Gadol A.A. (2009) Ossification of ligaments near the foramen ovale: an anatomic study with potential clinical significance regarding transcutaneous approaches to the skull base. *Neurosurgery* 65: 60-64.