

Ancient Egyptian paleopathology – The population of the tomb of IPI, necropolis of Dahshur-South

Andreas G. Nerlich

Institut für Pathologie, Academic Clinic Munich-Bogenhausen, Engschalkingerstr. 77, D-81925 Munich, Germany

Abstract

This study investigated the human remains of the tomb complex built by the ancient Egyptian high ranking official “Ipi” (4th Dynasty, ca. 2700-2600 BCE) in the Lower Egyptian necropolis of Dahshur-South. Beyond burials from the tomb owner and his family from the Old Kingdom, the complex was re-used until the Late Period. The excavated material presented the human remains of at least 73 individuals. Unfortunately, initial excavations had collected and mixed individual burials, so that individual identification in most skeletons was not possible. Later excavations presented complete individual burials. The custom typical of the New Kingdom until the Late Period of transnasal trephination offered, even with the mixed burials, a collection of 23 disturbed adults’ skulls (New Kingdom until Late Period) and 33 skulls of undisturbed adults (Old Kingdom). In these two groups sex ratios were fairly balanced. Most adult individuals died between 20 to 30 years. There were relatively few immature burials and a single skeleton was that of a 7th lunar month fetus, an obvious stillbirth; total number of immature was 10 (17.8%). Numerous paleopathological observations indicated the considerable impact of living conditions and health. There were 12 cases with healed traumatic sequelae including one with a healed ankylosed fracture of the knee and another with a fracture of the humerus, three cases of nonspecific osteomyelitis, three cases highly suggestive of spinal tuberculosis, one with evidence of metabolic bone disease from vitamin deficiency, and two cases with malignant bone tumours; one with multiple metastases of the vertebrae, and the other chondrosarcoma of the pelvis. Also, typical pathological changes were seen in teeth and jaws. Finally, the rate of osteoarthritis of large joints and that of spondylosis suggest significant work load. These findings indicate various ailments either due to heavy work load (arthrosis and spondylosis, traumatic sequelae), or to the living conditions (tooth abrasion by sand ingestion; tuberculosis due to foundation of settlements and townships), metabolic osteopathies possibly due to parasitic diseases and/ or malnutrition. These skeletal remains therefore contribute to our understanding of ancient Egyptian life and diseases.

Keywords

paleopathology; trauma; inflammation; tuberculosis; malignant bone tumour; vitamin deficiency.

Introduction

Our current knowledge on daily life and living conditions of past populations is mainly derived from archaeological findings and written sources. In most instances, however, it remains unclear to what extent the resulting information is correct and/ or complete. More and more information on life and disease in ancient cultures is

Corresponding author. E-mail: Andreas.Nerlich@extern.lrz-muenchen.de

obtained through the meticulous analysis of human remains, in most cases by anthropological and paleopathological investigations of skeletons and mummies.

This holds also true for the ancient Egyptian high culture. This flourished for more than 3,000 years in the Nile valley with significant variation of the population size in different time periods and regions. Beginning with the most extensive investigations by Smith and Jones (1908) in the early 20th century when emergency excavations in the Nile valley south of the first cataract (i.e. in the south of the Upper Egyptian city of Aswan) had to be performed due to the building of the first Aswan dam and the following flooding of the valley, several study groups have analysed specific populations in later periods. Since then, however, beyond differences in the populations also the techniques of analysis, the diagnostic certainty of diseases and their traces, and the extent of preserved material have been subjected to significant changes over time. It is therefore of considerable interest to collect as many data on as many available populations of the ancient Egyptian empire in order to refine our knowledge on their historic living conditions.

Besides Smith and Jones' (1908) studies, some analyses have been performed on the large necropolis of Qubbet-el-Hawa near Aswan, Upper Egypt by Rösing (1990) and Minshat-Abu-Omar in the Nile delta (Parsche 1991). These analyses provided considerable information on the population of townships at the periphery of the Egyptian empire. Significant data on distinct populations have previously been made available for the New Kingdom capital of ancient Egypt, Thebes, describing the anthropological and palaeopathological findings from various major tombs of the necropolis of Thebes-West which are part of the "Tombs of the Nobles" (Nerlich et al., 2000); these cover burials of mainly higher class individuals of the capital of the empire. Further, though limited, studies have been presented on other Theban tomb complexes (Dra-Abu-el-Naga) from Middle to New Kingdom period (Polz et al. 1999), the Theban tomb complex TT-196 (Asasif) (Zink and Nerlich, 2007) and from the Old Kingdom necropolis of Abydos (Zink and Nerlich, 2002) and Buto (Hartung et al. 2009).

The present study provides information on a specific population; the burials of the tomb complex of Ipi, an Old Kingdom royal court official during the reign of Pharaoh Sneferu (4th dynasty). This covers both Old Kingdom (OK) and Late Period (LP) burials in the large necropolis of Dahschur-South (Alexanian et al., 2006). The tomb complex comprises not only the original burial in a typical *Mastaba* complex, but also later intrusive burials. However, all material has been subjected to significant grave robbery. In addition, early modern period excavations did not take care of the human remains which were moved and intermingled. Although this setting renders the analysis much more difficult, a methodical investigation using anthropological and palaeopathological approaches can provide useful information, even in those instances where the material is mixed and/or partly destroyed.

Materials and Methods

The necropolis and the tomb complex of "Ipi"

The necropolis of Dahschur, some 30 km south of present-day Cairo and only few km in distance from the ancient Egyptian capital of Memphis, covers a large area



Figure 1. Standing-striding figure of the Court Musician Ipi (4th dynasty, limestone, Dahschur, inv. nr. 1600, Staatliches Museum Ägyptischer Kunst, München, Germany). Frontal (a) and lateral view (b) (Photos: A. Nerlich, with permission).

at the interface between the Great Western Desert and the irrigated Nile valley. The necropolis was used from the early period of the first pyramids that had been erected in Dahschur by Pharaoh Sneferu (4th dynasty, ca. 2700 – 2600 BCE). In close proximity to the cemeteries of the pyramids, high royal court officials were granted the right to build their own tombs in the necropolis area as a special favour of the Pharaoh.

The high court official “Ipi” (Fig. 1), musician at Pharaoh Sneferu’s court, built a *mastaba* for his family and household, several hundred metres south of the so-called “bent pyramid”, one of the three pyramids that had been erected by the King. The tomb complex was first scientifically analysed by the American journalist and archaeologist Muses (Gabra, 1971, Muses, 2000) and later extensively re-analysed by the mission of the German Archaeological Institute Cairo by Alexanian (Alexanian and Seidlmayer, 2000 and 2002). These investigations proved the correct attribution of the tomb complex to Ipi, but also showed an extensive re-use of the burial complex in later periods into the Late Period (until 330 BC). The complete complex was found to contain seven burial sites, with burial DAS-9 being the by far largest tomb, and contained the original inhumation (Alexanian and Seidlmayer, 2002).

Unfortunately, during the first archaeological excavations (by Muses) the tomb complex DAS-9 had been opened and all the human remains were collected together and left mixed up, rather than separated as individuals. The subsequent excavations detected this pile of bones, removed all the human remains en-bloc, and provided this material as one sample for anthropological-paleopathological analysis. The subsequent excavation of the other tombs in the complex, DAS-8, DAS-11, DAS-12, G2, G4 and G16, were performed step by step; all human remains were collected separately and investigated as individual findings, although this material also showed significant previous grave robbery and destruction. In consequence, the present analyses comprised two sets of material; the mixed material from DAS-9, and the individual findings from the six other smaller burial sites.

Material

All material from the tomb complex comprised skeletonised human remains; there were no soft tissues. The isolated skeletal remains (except DAS-9) was evaluated for completeness of the skeletons (representability) and the condition of the bone material (state of preservation) using an established scoring system (Nerlich et al., 2015).

Methods

All skeletal material was subjected to an anthropological and paleopathological investigation as previously described (Nerlich et al., 2000). The mixed material was recorded and the numbers of skeletal elements were used to estimate the minimum number of individuals (MNI). In the isolated tombs, the number of individuals was determined by the (complete) skeletons detected. In order to estimate the number of individuals in the mixed material of DAS-9, all skulls were specially recorded for presence/ absence of a perforation of the lamina cribrosa of the nasal roof (the site for excerebration since the early New Kingdom, i.e. ca. 1500 BC) and/ or the presence of embalming substance residues within the skull (Ikram and Dodson, 1998). Thereby, a rough estimation of burials before and after 1500 BC could be performed.

All estimations for age and sex distribution were performed as previously described in detail (Nerlich et al., 2000) and in clear accord with suggested criteria (Buikstra and Ubelacker, 1996; Harbeck, 2014). For sub-adult individuals the criteria by Scheuer et al. (2010) were applied. Pathological changes in affected skeletal elements were recorded individually and differential diagnoses were established as previously described (Nerlich et al., 2000, Nerlich et al., 2015).

Results

Estimation of the number of individuals

In the tomb complex DAS-9 the mixed bones were first organised by anatomical site. There were at least 46 adult skulls present, 33 complete and 13 fragmented ones. There were 40 mandibles (either complete or fragmented), 43 right and 42 left femora, 37 right and 38 left tibiae, 43 right and 42 left humeri, 29 right and 34 left radii, and




Figure 2. Fetal bones (7th gestational month) excavated from the tomb complex DAS-8. (Scale 1 cm).

41 right and 36 left ulnae. The number of complete or fragmented adult pelvic bones comprised 33 right and 29 left ones. In addition, at least four immature individuals could be identified; two *Infans I* (0-7 years), one *Infans II* (7-14 years), and one *Juvenis* (adolescent 14-18 years).

In total, there were at least (MNI) 46 adults and four sub-adults/ children in the mixed bone group. The macroscopic condition of the bone material suggests an overall good state of preservation, although for this material no further data on completeness or state of preservation could be evaluated.

For the other tombs the following observations were made. DAS-8 contained the burials of nine individuals, four adults and four sub-adults, three *Infans I* and *II* and one fetus (still-birth 7 months; Fig. 2). In DAS-11 only one adult burial was detected, while DAS-12 contained nine burials with five adults and four sub-adults *Infans I*. In the tombs G2, G4 and G16 each with one adult was found and adjacent to G16 one additional *Infans I* had been buried.

In summary, the complete tomb complex of the *mastaba* of “Ipi” contained the human remains of 73 burials, with 46 adults and four sub-adults in the main complex and 13 adults and 10 sub-adults in the adjacent parts of the tomb area. The rate of immature burials (fetus; *Infans I* and *II* and juveniles) was 10 out of 73 (17.8%).

Attribution to burial time periods

From time-specific embalming procedures 20 skulls of DAS-9 were attributed to the Old Kingdom and 23 to the New Kingdom until the Late Period; three skulls were not attributable. The four sub-adults could not be further classified due to major bone loss of the few residual and fragmented skull bones.

For the nine burials in DAS-8, the single burial in DAS-11, and the nine burials in DAS-12, there was no evidence of skull manipulations suggesting all may be of original

early burials dating to prior to 1500 BCE. At least one of the four burials in G2, G4 and G16 showed bitumen residue in the skull and seem to represent a later intrusive burial.

Representability and state of preservation

Representability could only be evaluated for the material in individual burials, but not for the material in DAS-9. In the 23 identifiable individuals only one was a fairly complete skeleton (30.8 points out of 42), in 10 cases moderately complete material (10 to 20 points out of 42 points), and in 12 samples little skeletal material (< 10 points out of 42 points). Therefore, most of those cases were only incompletely preserved.

The state of preservation in contrast was much better. Six individuals showed excellently preserved bone material (>70-100%), a further six good preservation (>50-70%), 10 samples were moderately well preserved (>30-50%) and only one case was poorly preserved (<30%).

Age and sex-distribution

In the mixed material of DAS-9, age estimation from skulls and pelvic bones in adults showed no significant differences between the Old Kingdom and the Late Periods with a mean age-at-death between 20 and 30 years (Fig. 3). However, the older material contained significantly more males than females when compared to the later material ($p=0.02$, Fisher Exact Probability Test) (Fig. 4).

The adjacent burials to Ipi's tomb showed an age distribution that reflected the high rate of immatures which influenced the plot. The low number of adults has to be interpreted with great care (Fig. 5). Similarly, the sex distribution with mainly adult males (Fig. 6) obviously does not provide representative observations.

Paleopathological observations

The paleopathological findings of both study groups were combined since the material of the adjacent tombs to DAS-9 showed little evidence of pathology; two

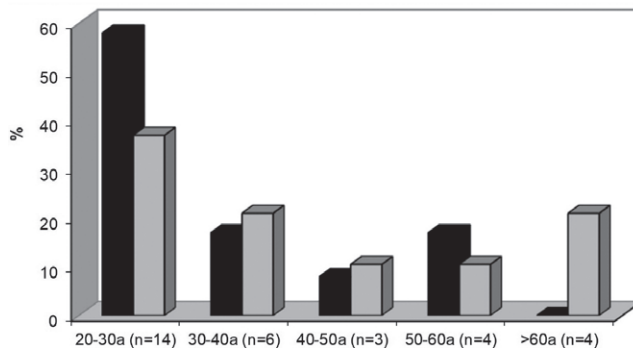


Figure 3. Age distribution of the skulls excavated in the tomb complex DAS-9, divided into material from the Old Kingdom and later material. (Black = Old Kingdom material; white = New Kingdom until Late Period).

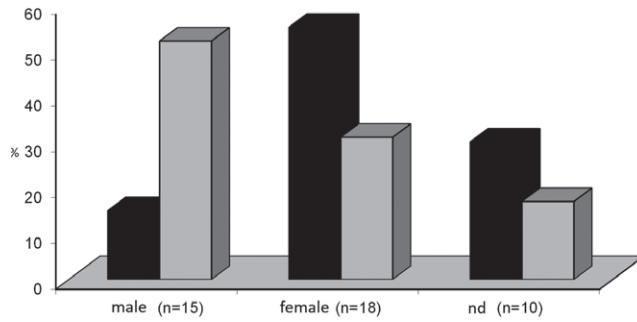


Figure 4. Sex distribution of the skulls excavated in the tomb complex DAS-9 (Black = Old Kingdom; White = New Kingdom until Late Period).

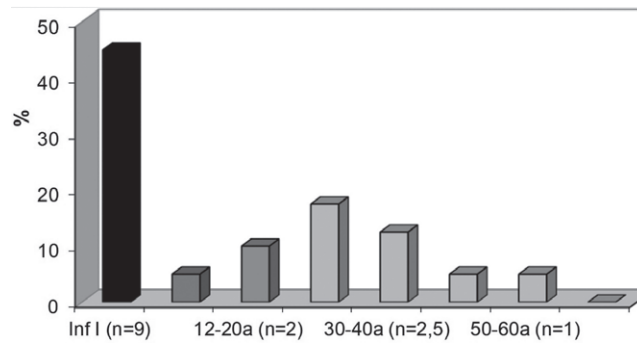


Figure 5. Age distribution of the human material from the tomb complexes except DAS-9 (Black = *Infans I*; Dark grey = *Infans II*; Grey = Adults until mature age).

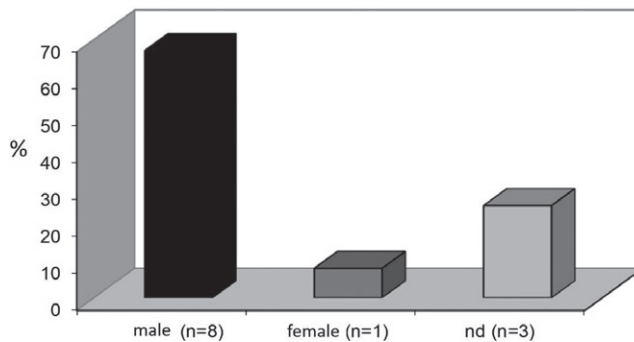


Figure 6. Sex distribution of the human remains from the tomb complexes except DAS-9 (Black = males; Dark grey = females; Grey = not determined).

Table 1. Summary of the pathological findings and anatomical variations.

Observation	DAS 9 N	Relative frequency %	Other tombs N	Total fre- quency %	Old Kingdom N	Later periods N
Spina bifida	3	6.5	0	5.1	0	0
Spondylolisthesis	2	4.3	0	3.4	0	0
Sutura metopica	3	6.5	0	5.2	2	1
Trauma	12+	27.9	2	24.1	0	0
Cribrā orbitalia	5	10.9	0	7.4	2	3
Osteopenia	2+	4.3	3	7.3	0	0
Scurvy	2+	4.3	0	3.4	0	0
Arthrosis	36 out of 605	5.9	*	5.9	0	0
Spondylosis	85 out of 372	22.8	*	22.8	0	0
Nonspecific inflammation	3	6.5	0	5.2	0	0
Tuberculous Spondylitis	3	6.5	0	5.2	0	0
Benign Tumors	3	6.5	0	5.2	0	0
Malignant Tumors	2	4.3	0	3.4	0	0
Tumour-like lesions	2	4.3	0	3.4	0	0
Dental caries	5	10.0	0	8.6	0	2
Intra-vital dental loss	6	13.0	0	10.3	0	1
Dental abscess	11	23.9	1	20.7	2	3

NB:

Arthrosis = number of degenerated joints per the total number of joints evaluated

Spondylosis = number of degenerated vertebral bodies/ facet joints per total number of vertebral bodies investigated

*The adult joints and vertebrae in the adjacent tomb complexes were so poorly preserved that these were not included in this table.

traumatic injuries, three with osteopenia, and one with a dental abscess. A detailed summary of findings is reported in Table I. This contains not only the frequencies for the respective lesions, but also the burial period (OK vs. LP) where possible (i.e. in skull findings).

Out of these overall data, several specific observations have to be described more in detail. First, a high rate of traumatic sequelae was noted with 20 showing fracture healing in 14 skeletal sites either callus or bony ankylosis. In eight cases metatarsals and phalanges had posttraumatic reactions consistent with a stress (or march) fracture (Fig. 7), and a further march fracture in an individual from an adjacent tomb (DAS-12). Further fracture sites and types were; the rib, clavicle (three) (Fig. 8), and forearm (two ulnae, and one radius), and the fibula with a typical spiral fracture of the shaft. There was one bony ankylosis of the knee with bridging callus following fractures between the distal femur and the patella (Fig. 9). There was also a case of severe trauma to the shoulder with almost complete destruction of the head of the

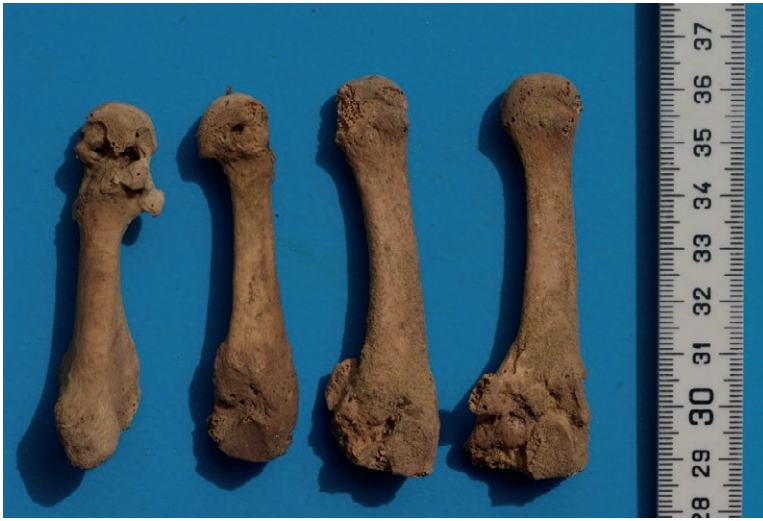

Figure 7. Metatarsals with the 5th (on the left) showing a healed distal shaft transverse stress fracture (left, DAS-8).

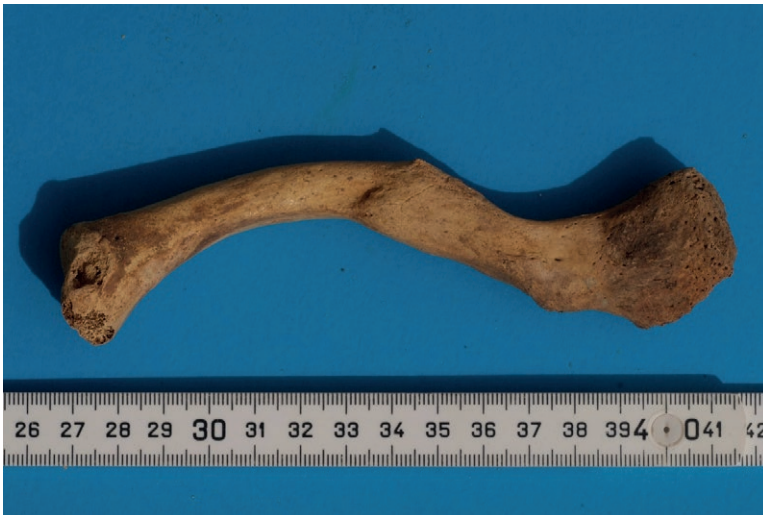

Figure 8. Old healed short oblique fracture of the mid-shaft of the clavicle.

humerus and the glenoid with extensive new bone formation (Fig. 10). These last two injuries required considerable force, probably from an accident and survived for a long period afterwards despite significant disability in the right leg and right arm respectively.

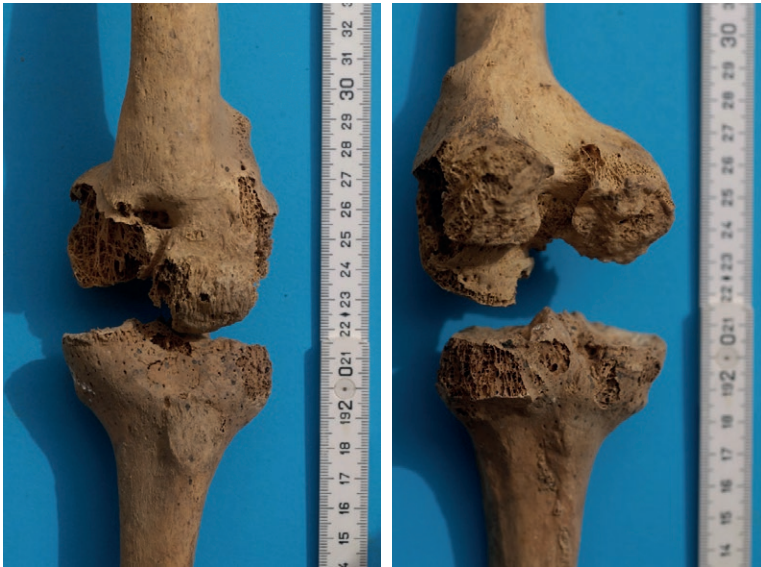

Figure 9. Severe traumatic injury of the right knee joint with bridging ankylosis of the patella to the distal femur. Despite some *post-mortem* bone loss severe *in vivo* destruction of the joint is clearly evident. Note also the malunion of the lateral condyle of the distal femur indicating an old-healed fracture line. A: ventral view; B: dorso-lateral view.

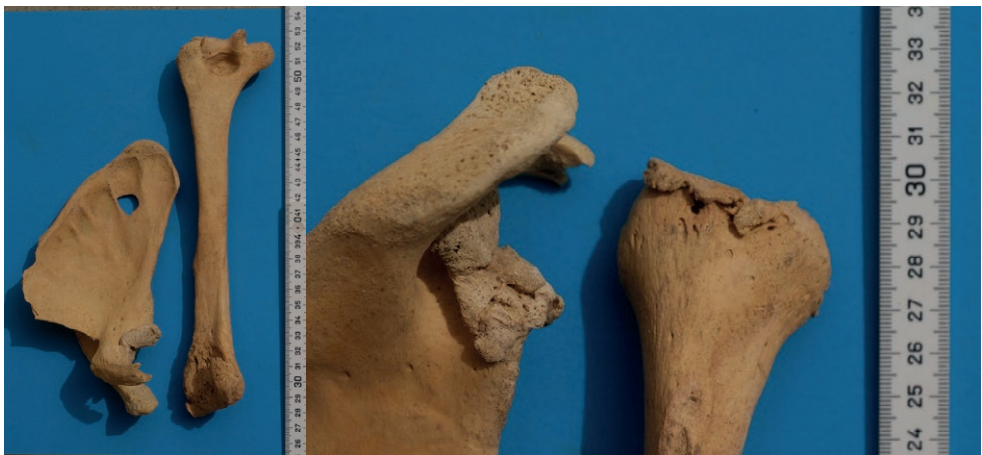

Figure 10. Severe traumatic injury of the right shoulder joint. There is almost complete resorption of the humeral head presumably following avascular necrosis from a humeral neck fracture, plus severe deformity of the glenoid joint surface, consistent with a displaced fracture dislocation of the glenohumeral joint. A = anterior view; B = close-up posterior part.

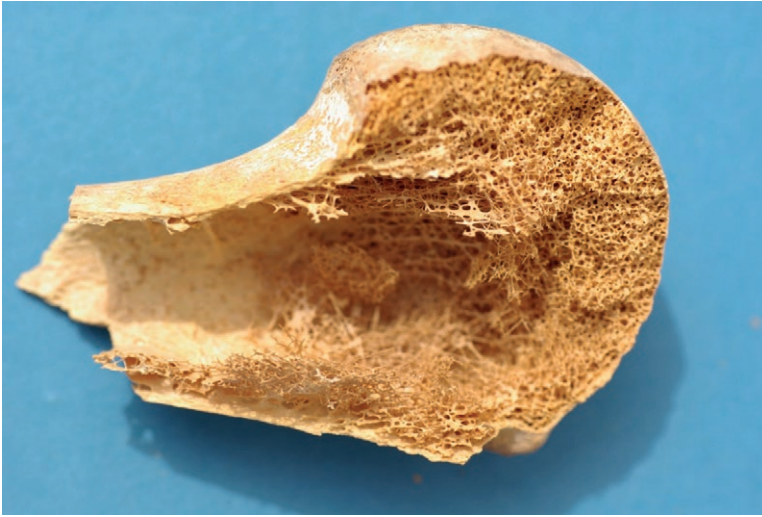

Figure 11. Considerable osteopenia of the humeral head. Note the very thin metaphyseal cortical bone and the loss of cancellous bone in the marrow cavity.

Evidence for metabolic disease was present as *cribra orbitalia* in five of the 46 skulls from DAS-9, mostly mild to moderate. Two of the affected individuals came from the Old Kingdom population, and the other three burials from the LP. Osteopenia, which in younger populations typically is due to vitamin D deficiency, was seen from DAS-9 in eight samples belonging to at least two individuals (typically multiple bones are affected) (Fig. 11), and in three individuals from adjacent tombs, included an *Infans I*. Since the latter also showed some bowing of the long bones, the diagnosis of rickets is most likely. Finally, at least two individuals showed subperiosteal new bone formation close to the joint which is typical of an ossifying haematoma from chronic vitamin C-deficiency (scurvy). Again several bone fragments were affected which must have belonged to at least two individuals.

A further group of paleopathological findings demonstrated degenerative lesions of the joints and the vertebral column. In the mixed bone material of DAS-9, 36 out of the 385 complete long bone joints mild to moderate arthrotic lesions were present. In seven joints severe osteoarthritis was seen. The shoulder, hip and knee joints were the most affected. These data, however, have their limitations since considerable number of the joints were only poorly preserved and did not allow a detailed evaluation. This held particularly true for the material from the tombs outside DAS-9. Similarly, most vertebral bodies and facet joints did not show degeneration. In the spine, degeneration was mostly seen in 34% of lumbar, 24% of cervical, and 10% of thoracic vertebrae.

Inflammatory reaction in bones and joints were clearly seen in six samples from three individuals with typical non-specific inflammatory bone changes and three with probable tuberculosis. The latter all affected the spine with destruction of the anterior part of the vertebral body; two upper lumbar and one lower thoracic (Fig. 12). All came from DAS-9.



Figure 12. Lumbar vertebral body with major destruction mainly affecting the ventral part including the end (ground) plate. This type of lesion leads to a kyphotic spinal deformity and is very suggestive of spinal tuberculosis.

The final group of pathological lesions, which have a great clinical impact in modern medicine, were bone tumours, either primary or metastases, which have to be distinguished from tumour-like lesions. In the material from Ipi's tomb complex, all three types of lesions were detected. First, there were two femora with metaphyseal osteochondromata with 19x11 mm and 15x4 mm bony spurs respectively. Then there was an Old Kingdom skull with an incomplete osteolytic lesion of the inner table and an adjacent large blood vessel bony impression consistent with the diagnosis of meningioma. The blood vessel impression was outside the area where normal blood vessel impressions (Pacchionian granulations) are typically seen. Although meningiomata are currently classified by the "Union International Contre le Cancer" (UICC) as semi- or low-grade malignant, most meningiomata have a benign clinical course. In the material from Ipi's *mastaba* a typical tumour-like lesion close to the shoulder was a well-defined lobulated bone cyst with a smooth inner wall. An Old Kingdom male skull showed thickening of the inner table of the frontal bone (hyperostosis frontalis), another tumour-like lesion.

In addition, there were two lesions highly suggestive of malignant growth. The first was a large cauliflower-like lobulated tumour of the lower pelvic bone (os ischium), 39 x 24 x 11 cm in size, which extended beyond the outer cortex into the adjacent soft tissues (Fig. 13). The location and morphology strongly suggested the diagnosis of a well-differentiated chondrosarcoma; a large malignant tumour arising from cartilage with secondary calcification and reactive bone formation. These tumours are rare and become more frequent with increasing age. They most often affect the pelvic girdle and usually grow slowly without metastasising until they dedifferentiate when they spread haematogenically.

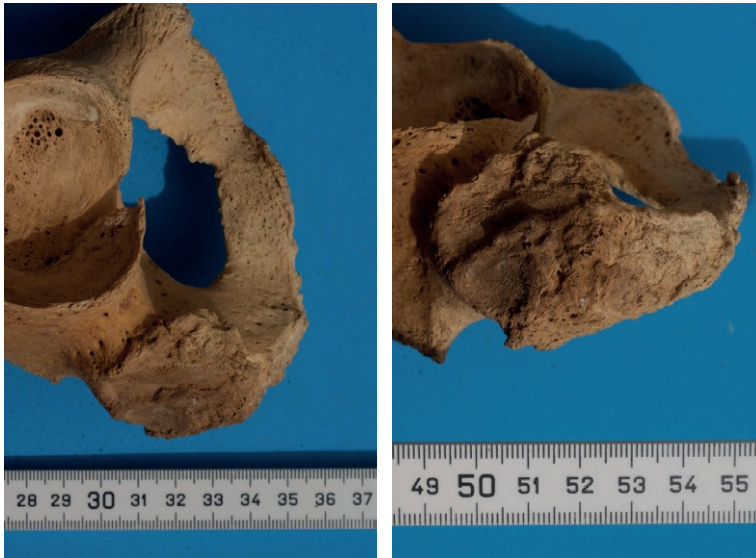


Figure 13. Tumour arising from the os ischium of the right pelvis with an irregular extension of the bone surface with protrusion into the soft tissue. This type of lesion is strongly suggestive of a chondrosarcoma of the pelvis. A = caudal view; B = lateral view.



Figure 14. Three lumbar vertebrae with the bodies showing irregular osteolytic defects in the central to posterior part, highly suggestive of spinal metastases. Type and location excludes degenerative lytic lesions as well as Schmorl's nodes.

The second case of suspected malignancy affected several vertebral bodies with confluent small osteolytic lesions (Fig. 14). The most likely diagnosis is metastases from a malignant solid organ tumour. Lytic bony metastases have to be distinguished from osteoblastic (bone forming) ones. However, there no indicators for age, sex or any other possibly affected skeletal elements, so the underlying primary tumour is not certain.

Finally, teeth not only allow evaluation of nutrition, but may show distinct pathological lesion such as dental loss, abrasion and caries. The latter are frequent findings in most historic populations, mostly due to poor oral hygiene and the use of stone mills for bread making. In the DAS-9 material, dental caries was seen in five individuals of DAS-9 (11 %), while none of the other burials were affected (9%). This parallels the rate of *in vivo* dental loss, mostly from caries; in DAS-9, 13%, and other burials, 10%. Dentogenic abscesses were seen in 11 individuals from DAS-9 (24%) and the other burials (21%). Dental abrasion in these younger individuals was surprisingly more pronounced than in older ones, possibly as the result of differences in social ranking.

Discussion

The investigation of human remains using a combination of anthropological and paleopathological techniques offers a direct approach to understanding the life and living conditions of historic populations. Ancient Egyptian populations are ideal because their funerary arrangements provide, not only human remains, but pictorial and written material. A number have already been investigated (Smith and Jones, 1908; Rösing, 1990, Parsche, 1991, Nerlich et al. 2000). This paper presents a further collection of human skeletal material which, despite some being disrupted and mixed, still provides useful and important data. It also shows the advantages of modern day excavation techniques using careful planned recovery and storage of human remains for further analysis.

The tomb complex under investigation was of a high royal court officer named Ipi dating to the Old Kingdom (4th dynasty, c. 2700 – 2200 BC). Both the archaeological investigation (Alexanian, 2006), as well as the present anthropological-paleopathological study, support the notion that the *mastaba* was initially used for Old Kingdom burials, namely that of Ipi, his family, and possibly members of his household. However, as seen very frequently in ancient Egyptian necropoli (Nerlich et al., 2000), later intrusive burials destroyed part of the tomb complex and may also have disturbed the original ones.

The complete excavation of the tomb complex showed the human remains of at least 73 individuals, the number being determined by Harbeck's anthropological analysis (Harbeck, 2014). Since ancient Egyptian embalming techniques changed considerably at the end of the Middle Kingdom to the New Kingdom period, i.e. ca. 1500 BCE (Ikram and Dodson, 1998), it was possible to divide most of the skulls into two separate sub-populations; one presumed from the OK period, and one of later burials which may be dated into the Third Intermediate to Late Period (LP) (Ikram and Dodson, 1998). From this, 22 burials were assigned to the OK, and 24 burials to the LP periods.

The sex distribution in the OK group of DAS-9 significantly favoured females but was near equal when the other OK burials were included. It may well be that the initial incomplete excavation in 1957 led to an unequal retrieval of the material and that the combination of both groups presents a more realistic population distribution. This is supported by the addition of immature skeletons of both settings coming to a total of 14 individuals (ca. 18% of all individuals), covering a broad range between one fetus through to two juveniles.

Most interestingly, the estimated sex ratios and the age at death distribution were not significantly different between the “OK” and the “LP” (at least as far as this can be reconstructed) indicating that basic living conditions could have been comparable between both periods. This is similar to previous data which also showed that most adult individuals died between 20 and 40 years, an immature ratio of between 10 – 20% and a balanced sex ratio in various populations of the Nile valley (Smith and Jones, 1908; Rösing, 1990; Parsche, 1991; Nerlich et al. 2000).

A repeated, but nevertheless surprising observation, was the low rate of infants and sub-adults in the study population. A similarly low rate of immatures was seen in various previous studies of between 10 and 30% with minor differences between pre-dynastic to Christian period in Nubia (Smith and Jones, 1908). The analysis of a large necropolis in Lower Egypt (Minshat Abu Omar in the Nile Delta region, Parsche, 1981) revealed an infant rate of 32%. Several Theban necropolis closely resembles the present data with an immature rate of 19% which is also significantly lower than supposed from Egyptian data of Khedive Period around 1900 CE where the immature death rate ranged at about 70% (Smith and Jones, 1908). The low amount of immature mummy residues may be due either to a rather selective loss of the much more fragile skeletal elements of the infants to adults, or a truly lower rate of immature deaths than expected, or that not all immature individuals were buried in the tombs. The latter has been observed since in-house burials of infants have been detected in the ancient Egyptian city of Elephantine, Aswan (Schulz and Schmidt-Schulz, 1993) or as separate cemeteries for infants as seen in Deir-el-Medineh (Bonnet and Valbelle, 1976). However, since the conditions of tissue preservation in general are excellent with storage in a dry, arid climate, the amount of lost infant skeletons can assumed to be limited. This may be supported by the presence of fetal and neonatal bones despite being the most fragile ones that should perish quickly. The answer to this open question awaits further archaeological findings.

The pathological findings in the individuals of the Ipi tomb complex need to be compared with the findings in other populations. The rate of dental pathology seems to be slightly lower in the Ipi population of Dahschur when compared to the Aswan and Theban material. Nevertheless, the severe abrasion of teeth, in combination with the low age at death, indicates the effects of stone mill debris and sand inclusion in the daily diet. The rates of dental caries, dental apical abscesses and *in vivo* tooth loss are comparable to those of other ancient Egyptian populations.

In contrast, the population buried in Ipi's *mastaba* contained a high number of traumatic sequelae (24%) which clearly exceeds those of previous ancient Egyptian studies e.g. 3% in the Nubian material of Smith and Jones, 1908, 9 % in the necropolis of the Qubbet-el-Hawa(Rösing, 1990), and 16% in the Theban necropolis(Nerlich et al., 2000), but which is comparable to a study on Nubian material, south of Aswan, dating in the Late Period until Christian time with 21% trauma cases (Alvrus, 1999). The reason for the increased trauma rate in the Dahschur material may relate to the type of fractures; most occurred in the small bones of feet and hands and may be the result of working injuries during the building and/or maintaining of the necropolis. The two cases with severe trauma injuries of the shoulder and knee joint however were due to high energy mechanisms, such as falls from a height, or a blow by a heavy or speeding vehicle and would have led to severe, debilitating loss of the func-

tion of the affected limb. To have continued in the community would have required the individuals to have a supportive social network.

As seen in previous studies on ancient Egyptian human remains, significant bone changes consisted with chronic metabolic disease were found; typically, this is due to chronic anaemia or vitamin deficiencies. Cribra orbitalia which is assumed to occur as a result of chronic anaemia, were noted in around 7%, which is lower than in other populations at 15-20% (Parsche, 1981; Nerlich et al., 2000). The most likely cause for chronic anaemia is chronic infection, in particular parasitic infections such as schistosomiasis (Ruffer, 1910), pulmonary parasitosis (Nerlich et al., 1995), leishmaniasis (Zink et al., 2006) and chronic malaria (Nerlich et al., 2008).

Similarly, the rates for osteopenia and periosteal new bone formation at the metaphyses of long bones were also considerably high. Periosteal new bone formation is characteristically seen in scurvy. Around 4% of individuals were found to have this abnormality, which is less than found, for instance, in the Theban necropolis at 8 - 11.5%. In a country with a wealth of vitamin C-containing fruit, nutritional deficiency is unlikely; thus it is more likely to be due to disorders that "consume Vitamin C" such as in chronic infectious diseases. Interestingly, in previous cases with molecularly proven tuberculosis (Nerlich et al., 1997), periosteal new bone formation was seen e.g. in the distal femora. Osteopenia is a feature of several pathological conditions, in particular pre-osteoporosis (mainly as senile or hormonally induced), but can also occur in chronic vitamin D-deficiency (osteomalacia) or overactivity of the parathyroid glands (hyperparathyroidism). Since this study population were mostly young when they died (see above) then the osteopenia is much more likely to reflect chronic vitamin D-deficiency and osteomalacia. Since vitamin D-deficiency may also result from chronic intestinal infection, such as with parasites, then the deficiency is more likely to be from intestinal worms than lack of sunlight.

In this study the rate of inflammatory osseous lesions was low at around 5% with half of these of tuberculosis. This is still significantly higher than that seen elsewhere. Smith and Jones' (1908) in their series of 6000 ancient Egyptian mummies/skeletons specimens showed no inflammation at all or any osteomyelitis. This has already been extensively discussed in previous papers on various ancient Egyptian human remains (Nerlich and Lössch, 2009; Zink et al., 2005). However molecular testing (Zink et al., 2005) supports the view that the high incidence of tuberculosis in ancient Egypt fits in with the present study's findings.

The osteoarthrotic and spondylotic bone changes found in this study in a relatively young population implies extreme mechanical loads on the large joints especially the hip and knee, and the spine. The rate of affected joints, and the degree of degeneration, is in keeping with previous study populations. Likewise, populations of several Theban tomb complexes showed a joint osteoarthrosis rate of 4 - 7% (Nerlich et al., 2000; Polz et al., 1999; Zink and Nerlich 2002) which is comparable to the Dahschur material from Ipi's tomb complex at 5%. Degenerative lesions of the vertebral column (spondylosis) were 23% in the Dahschur material and 12 - 36% in the Theban material (Nerlich et al., 2000, Polz et al., 1999; Zink and Nerlich 2002). The Ipi's *mastaba* complex rates suggest comparable mechanical load and stress on joints and the vertebral column to those of the New Kingdom until Late Period tomb material from Thebes. Furthermore, the fairly constant figures suggest only little changes in the work load of populations of comparable social status and possible function over many centuries of ancient Egyptian history.

Finally finding a number of benign and malignant tumours affecting the skeleton in this study was unsurprising since all other previous studies on larger series of human remains were able to detect tumours. Although repeatedly discussed, tumours, in particular malignant ones, have been seen in the majority of ancient populations (Nerlich, 2018), but the relatively high frequency should be noted (and is at variance to the interpretations by David and Zimmerman, 2010). While there do not exist comparable data on benign tumours, the malignant tumour rates have extensively been documented and discussed (Strouhal, 1976; Waldron, 1996; Nerlich et al., 2006; Nerlich, 2018). The identification of two cases of malignant tumours, one a genuine osseous tumour (the pelvic chondrosarcoma and the other metastatic infiltration of the spine, add to the previous lists of malignant tumours found in ancient Egypt and strongly support the notion that malignant tumours were not rare at that time especially as the age at death was much younger than today (Waldron, 1996; Nerlich, 2018).

In summary, the analysis of all the available human material from a large tomb complex of the necropolis of Dahschur, erected by Ipi in the Old Kingdom, presents novel data on the structure and the occurrence of distinct diseases in that population. Beyond some basic data on the structure of the population and further observations of an unexpectedly low rate of immature burials, this study adds information to the spectrum and frequency of diseases in ancient Egyptian populations, with the surprisingly comparable types and rates of diseases with other populations of the Egyptian high civilisation over almost 3,000 years. Therefore, this study concludes that life and living conditions were very comparable over a long period of time.

This study shows that analysis of poorly curated material with intermingling of skeletal remains at a burial site can still provide useful data that enhances the knowledge of the lifestyle and diseases of an ancient population.

References

- Alexanian N, Seidlmayer SJ (2002) Die Residenznekropole von Dahschur. Erster Grabungsbericht. *Mitt. Dtsch. Archäol. Inst. Kairo (MDAIK)* 58: 1–28.
- Alexanian N, Seidlmayer SJ (2006) Die Nekropole von Dahschur. *Forschungsgeschichte und Perspektiven*, in: Bárta, Krejčí J (eds.) *Abusir and Saqqara in the Year 2000*, *ArOr Suppl.* IX, Prag, pp. 283–304.
- Alexanian N, Becker H, Müller M, Seidlmayer SJ (2006) Die Residenznekropole von Dahschur. *Zweiter Grabungsbericht*, *Mitt. Dtsch. Archäol. Inst. Kairo (MDAIK)* 62: 7–41.
- Alvrus A (1999) Fracture patterns among the Nubians of Semna South, Sudanese Nubia. *Int. J. Osteoarcheol.* 9, 417–429.
- Bonnet C, Valbelle D (1976) Le village de Deir el-Medineh. *Étude archéologique*. *Bull. Inst. Franc. Arch. Orient. (BIFAO)* 76.
- Buikstra JE, Ubelaker DH (1996) Standards for data collection from human skeletal remains. *Proceedings of a seminar at the field museum of natural history*. *Arkansas Archaeological Survey Research Series* 44.
- David AR, Zimmerman MR (2010) Cancer: an old disease, a new disease or something in between? *Nat. Rev. Cancer* 10: 728–733.

- Gabra S (1971) *Chez les derniers adorateurs du Trismegiste. La necropole d'Hermopolis – Touna el-Gebel (Souvenir d'un Archéologue)*, Cairo.
- Harbeck M (2014) *Anleitung zur standardisierten Skelettdokumentation in der Staatssammlung für Anthropologie und Paläoanatomie. Schriften Staatssammlung für Anthropologie und Paläoanatomie München*, pp. 1-54.
- Hartung U, Ballet P, Efland A, French P, Hartmann R, Herbich T, Hoffmann H, Hower-Tilmann E, Kitagawa C, Kopp W, Kreibitz W, Lecuyot G, Lösch S, Marouard G, Nerlich A, Pithon M, Zink A (2009). Tell el-Fara'in – Buto. 10. Vorbericht. *Mitt. Dtsch. Archäol. Inst. Kairo (MDAIK)* 65: 41-65.
- Ikram S, Dodson A (1998) *The Mummy in Ancient Egypt. Equipping the Dead for Eternity*. Thames, London.
- Musès CA (2000) Die Königspyramide des Ameny-Qemau. Die unveröffentlichte Geschichte ihrer Entdeckung, *Kemet (Suppl.)* 20: 1-15.
- Nerlich AG, Parsche F, Wiest I, Schramel P, Löhns U (1995) Extensive pulmonary haemorrhage in an Egyptian mummy. *Virchows Arch.* 427, 423-442.
- Nerlich A., Haas C, Zink A, Szeimies U, Hagedorn H (1997) Molecular evidence for tuberculosis in an ancient Egyptian mummy. *Lancet* 350, 140.
- Nerlich A, Zink A, Hagedorn HG, Szeimies U, Weys C (2000) Anthropological and palaeopathological analysis of the human remains from three "Tombs of the Nobles" of the necropolis of Thebes-West, Upper Egypt. *Anthrop. Anz.* 58: 321-343.
- Nerlich AG, Rohrbach H, Bachmeier B, Zink A (2006) Malignant tumors in two ancient populations: an approach to historical tumor epidemiology. *Oncol. Rep.* 16: 197-202.
- Nerlich AG, Schraut B, Dittrich S, Jelinek T, Zink AR (2008) *Plasmodium falciparum* in ancient Egypt. *Emerg Infect Dis.* 14:1317-1319.
- Nerlich AG, Lösch S (2009) Paleopathology of human tuberculosis and the potential role of climate. *Interdiscip. Perspect. Infect. Dis.* 2009: 437187.
- Nerlich AG, Riepertinger A, Gillich R, Panzer S (2015) Paleopathology and nutritional analysis of a South German monastery population. *BioMed Res. Intl.* Article ID 486467.
- Nerlich AG (2018) Molecular paleopathology and paleo-oncology—State of the art, potentials, limitations and perspectives. *Int. J. Paleopathol.* 21: 77-82.
- Parsche F (1991) Paläodemographische und kulturhistorische Untersuchungen an Skelettfunden der Vor- und Frühdynastischen Nekropole in Minshat Abu Omar (Östliches Nildelta). *Anthropol. Anz.* 49, 49-61.
- Polz D, Gordon WE, Nerlich A, Piccato A, Rummel U, Voß S, Seiler A (1999) Bericht über die 6., 7. und 8. Grabungskampagne, *Mitt. Dtsch. Archäol. Inst. Kairo (MDAIK)* 55: 343-410.
- Rösing FW. (1990): *Qubbet el Hawa und Elephantine - Zur Bevölkerungsgeschichte von Ägypten*. G. Fischer Verlag, Stuttgart
- Ruffer, M.A. (1910): Note on the presence of Bilharzia haematobia in Egyptian mummies of the XXth dynasty. *Brit. Med. J.* 1, 16.
- Scheuer L, Black S, Schaefer MC. *Juvenile Osteology: A Laboratory and Field Manual*. Academic Press, Burlington, San Diego, London, 2010.
- Schulz M, Schmidt-Schulz T. (1993): Erste Ergebnisse der osteologischen Untersuchungen an den menschlichen Skelettfunden der 16.-20. Kampagne. - In: Kai-

- ser, W., Bommas, M., Jaritz, H., Krekeler, A., v. Pilgrim, C, Schultz, M., Schmidt-Schulz, T., Ziermann, M.: Stadt und Tempel von Elephantine. 19./20. Grabungsbericht. - Mitt. Dtsch. Arch. Inst. Kairo (MDAIK) 49, 182-187.
- Smith GE, Jones WF (1908) Report on the human remains. - Archaeological survey of Nubia. Bulletin 2.
- Strouhal E (1976) Tumors in the remains of ancient Egyptians. *Am. J. Phys. Anthropol.* 45: 613–620.
- Waldron T (1996) What was the prevalence of malignant disease in the past? *Int. J. Osteoarcheol.* 6: 463–470.
- Zink A, Nerlich A (2002) Vorbericht zu den anthropologischen und paläopathologischen Untersuchungen des Skelettmaterials aus den prä- und frühdynastischen Grabanlagen in Abydos In: G. Dreyer, U. Hartung et al. Vorbericht zu den Grabungskampagnen in Abydos. *Mitt. Dtsch. Arch. Inst. Kairo (MDAIK)* 59: 49-64.
- Zink A, Grabner W, Nerlich AG (2005) Molecular identification of human tuberculosis in recent and historic bone tissue samples: The role of molecular techniques for the study of historic tuberculosis. *Am. J. Phys. Anthropol.* 126: 32-47.
- Zink A, Spigelman M, Schraut B, Greenblatt CL, Nerlich AG, Donoghue HD (2006) Leishmaniasis in ancient Egypt and upper Nubia. *Emerg Infect Dis.* 2006 12:1616-1617.
- Zink A, Nerlich AG (2007) Die Ergebnisse der anthropologischen Untersuchungen 2000 und 2001, in: E. Graefe (ed.), Die Doppelgrabanlage "M" aus dem Mittleren Reich unter TT 196 im Tal el-Asasif in Theben-West, *Aegyptiaca Monasteriensia* 5: 57-71.

Acknowledgements

The author wants to express his sincere thanks to the Deutsche Archäologische Institut Kairo, head: Prof. Dr. Stephan Seidlmayer, and particularly the late Dr. Nicole Alexanian who was the driving force of all archaeological investigations in the necropolis at Dahschur. Furthermore, the careful correction of language and grammar by Prof. Simon Donnell is gratefully acknowledged.