

Research Article – Basic and Applied Anatomy

Position of the mandibular foramen in adult male Tanzania mandibles

Afadhali. D. Russa^{1*}, Flora M. Fabian²

Departments of ¹Anatomy, School of Medicine, Muhimbili University of Health and Allied Sciences (MUHAS), and of ²Anatomy, School of Medicine, International Medical and Technological University (IMTU); Dar es Salaam, Tanzania.

Submitted May 9, 2013; accepted revised January 14, 2014

Abstract

Failure of the inferior alveolar nerve block anesthesia is common in various dental operations. Anatomical variations of the location of the inferior alveolar nerve as it enters the mandibular foramen have been implicated as a main cause of these anesthesia failures. The aim of this work was to determine the location of the mandibular foramen in relation to the occlusal plane at the level of mandibular first molar and second premolar - often used as landmarks during the blocking procedure - and to different landmarks on the ramus of the mandible. The study was performed using mandibles from adult black male Tanzanians aged 30-45 years. Measurements were accomplished using two-digit electronic Vernier calipers. The distances were determined from the center of the mandibular foramen to the different reference points. The mandibular foramen was above the occlusal plane at the M1 and PM2 reference points in all the mandibles studied. It was also located about 20 mm and 12 mm from the anterior and posterior borders of the ramus respectively. There was no significant difference between the left and right side in any of the measurements. These results indicate that during anesthetic or other clinical procedures, the clinician can precisely determine the position of neurovascular bundle of the inferior alveolar nerve above the occlusal plane.

Key words

Mandibular foramen, occlusal plane, rameal borders.

Introduction

The mandibular foramen (MF) is an opening through which the inferior alveolar nerve (IAN) and vessels enter into the mandibular canal. It is classically located on the upper half of the medial aspect of the ramus of the mandible. The IAN and the vessels enter through the MF to reach the mandibular body and give fine branches that supply the mandibular teeth, gums and the lower lip. Blockage of the IAN under local anesthesia is commonly done at its entrance into the MF during various surgical and dental operations on the mandible and mandibular teeth such as removal of impaction, reductions of fractures and extraction of teeth. IAN block failure is not uncommon and it occurs even with experienced hands (Potocnik and Bajrović, 1999; Vinckier, 2000; Madan et al., 2002). Failure with this procedure could be as high as 45% (Potocnik and Bajrović, 1999; Vinckier, 2000; Madan et al., 2002).

* Corresponding author. E-mail: adrussa@yahoo.com, drussa@muhas.ac.tz.

Variations in the location of the MF have been suggested to be among the responsible factors (Nicholson, 1985; Vinckier, 2000; Keros et al., 2001; Devi et al., 2003) including bilateral variations (Mbajjorgu, 2000; Oguz and Bozki, 2002). Other studies went further to affirm that most cases of unsuccessful anesthesia during block of the IAN are due to the drug being deposited too high, too superficial or too deep, entailing a possibility of an anatomical variant location of the MF being a causative factor (Devi et al., 2003).

Some studies of adult mandibles in different races have given varied results regarding the location of the MF from the anterior and posterior borders, angle of the mandible and the lowest point on the mandibular notch (Nicholson, 1985; Keros et al., 1997; Mbajjorgu, 2000; Oguz and Bozkir, 2002). Although the exact point of reference on the occlusal plane has not been consistent among the studies, it has been suggested that the position of the mandibular foramen changes with age from below the occlusal plane in young children to the level of the occlusal plane at about nine years of age and above that plane in adults (Kilarkaje et al., 2005). These reports, therefore, suggest that there are contradicting results with regard to the anatomical localization of the MF in relation to important landmarks on the mandible among different populations and age categories. This poses challenges in determining the exact location of the MF and in setting standards for the intra-oral approach to block the IAN during injection of the local anesthetic in different populations and age groups. Normally a reference is made to the occlusal plane, and it is suggested that the needle has to pass 1cm above the occlusal plane around the premolar region (Roberts and Sowray, 1997).

Data documenting the position of the MF in relation to the occlusal plane of the mandibular teeth is scanty, particularly among the black African population. In adult black Zimbabweans, Mbarjiogu reported that the position of the MF was at the same level as the occlusal plane in about 47% of the study population, above the occlusal plane in about 29% and below that plane in about 24%, without bilateral variations (Mbarjiogu, 2000). A study among adult Kenyan Africans reported that the MF was below the occlusal plane in about 64.6% and at the level of the occlusal plane in about 31.1% (Mwaniki and Hassanali, 1992). These reports indicate great variation of the MF in relation to the occlusal plane in groups of African blacks. Despite these variations between and within races, studies on the location of the MF have not been done in Tanzania and little is known in regard to the location of this clinically important structure. This study therefore aimed at determining the anatomical location of the MF among the Tanzanian black population in relation to the various established ramal landmarks of both clinical and academic importance. It also assessed any asymmetry between the sides in relation to the established landmarks.

Materials and methods

A total of 44 dry cadaveric mandibles of adult Tanzanian blacks were used in this study. Electronic Vernier calipers (Reco Engineers, Dar es Salaam, Tanzania) were used to measure the distance from the MF to the anterior and posterior borders of the ramus, the mandibular notch and the mandibular angle. A meniscus ruler was used to extend the occlusal plane of the mandibular first molar and second premolar posteriorly to the MF and then the distances between the MF and the posterior extension

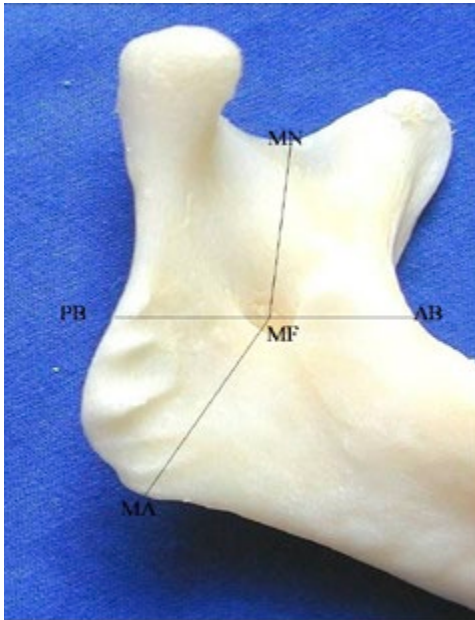


Figure 1 – Medial surface of the ramus of the mandible showing landmarks used for measures. MF: mandibular foramen; MA: mandibular angle; MN: mandibular notch; AB: anterior border; PB: posterior border.

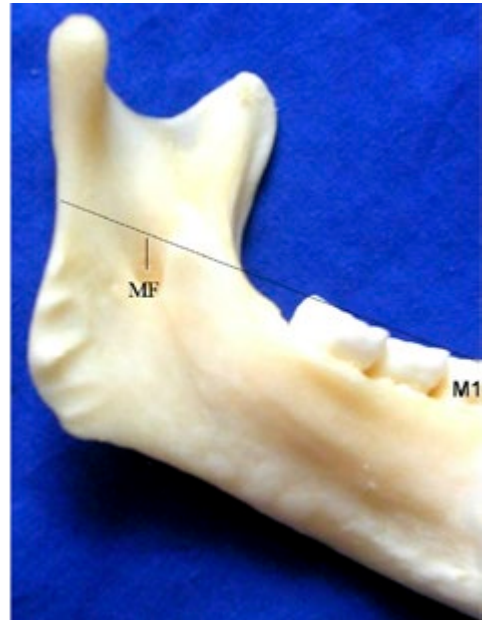


Figure 2 – Medial surface of the mandible showing posterior extension of the horizontal plane of the occlusal surface of the first mandibular molar (M1).

of those occlusal planes were measured. The various landmarks used for measurements are illustrated in Figs. 1 and 2.

Mandibles were obtained from the dissection room of the department of Anatomy, Muhimbili University College of Health Sciences. All the available mandibles in the department during the time of measurements were of male sex. Mandibles were obtained from the cadavers; soft tissues were cleaned using surgical blades and forceps and eventually with hydrogen peroxide using standard procedures. The mandibles were then cleaned with sodium hypochlorite and allowed to dry under room temperature before taking measurements.

Data were analyzed using SPSS Version 17.0 for Windows (SPSS Inc, Chicago, IL). Paired two tail t-test assuming equal population mean and variance were used to compare the left and right sides with p-value <0.05 considered significant. Quantitative data are given as mean \pm standard deviation (SD). Where necessary 95% confidence interval (CI) is provided. Graphical plots were accomplished using Excel (Microsoft Office, 2007)

Results

The MF was above the occlusal plane on both sides in all the mandibles studied. The mean vertical distance from the MF to the occlusal plane of the first molar was

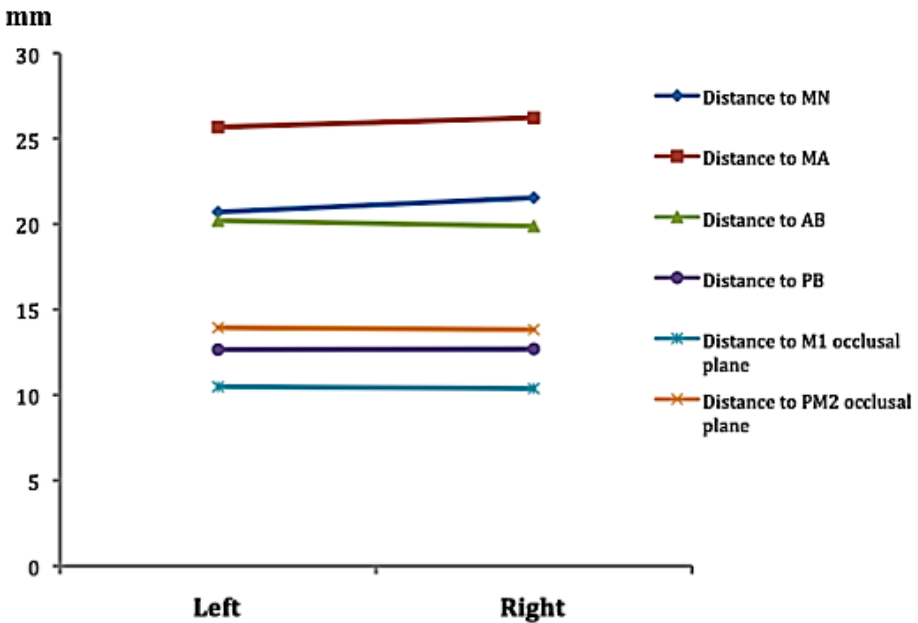


Figure 3 – Mean distance (mm) of the MF to various landmarks of the mandible on either side. MN: mandibular notch; MA: mandibular angle; AB: anterior border of the mandibular ramus; PB: posterior border of the mandibular ramus; M1: first permanent molar; PM2: second premolar.

10.38 ± 3.11 mm (95% CI: 9.46-11.30) and 10.49 ± 2.93 mm (95% CI: 9.62-11.35) for the right and left side respectively. This distance was not statistically different between sides. The vertical distance from the MF to the occlusal plane of the second premolar was 13.82 ± 3.20 mm (95% CI: 12.88-14.77) and 13.94 ± 3.47 mm (95% CI: 12.91-14.97) for the right and left sides respectively, not statistically different between sides (Fig. 3).

The mean distance to the anterior border was 19.88 ± 3.16 mm (95% CI: 18.94-19.81) on the right side and 20.19 ± 2.63 mm (95% CI: 19.42-20.97) on the left while the distance to the posterior border 12.69 ± 2.18 mm (95% CI: 12.05-13.33) and 12.65 ± 2.57 mm (95% CI: 11.89-13.41) for the right and left sides respectively. Both distances were not significantly different between sides. The anterior-posterior distance was larger than its posterior counterpart; indicating that the MF is located in the posterior half of the mandibular ramus. The total width of the ramus was almost the same bilaterally: 32.57 mm on the right side and 32.84 mm on the left (Fig. 3).

As for the location of the MF in respect to the vertical axis of the ramus, the distance to the mandibular angle was 26.23 ± 3.95 mm (95% CI: 25.06-27.39) on the right side and 25.68 ± 4.03 (95% CI: 24.48-26.87) on the left side. The distance to the mandibular notch was 21.54 ± 3.02 mm (95% CI: 20.65-22.43) and 20.70 ± 2.98 mm (95% CI: 19.82-21.58) on the right and left side respectively. The distance to the mandibular angle was generally larger than that to the mandibular notch, entailing that the MF was located in the superior half of the ramus. As for the measurement above, there were no significant differences between sides (Fig. 3).

Discussion

The MF was found above the occlusal plane of mandibular first molar and second premolar bilaterally for all the mandibles studied. This finding differs considerably from previous reports on black African subjects. For example, the MF was found above the occlusal plane only in a majority of black Kenyans (64.6%; Mwaniki and Hassanali, 1992) and in even fewer (29.4%) black Zimbabweans (Mbajjorgu, 2000). These discrepancies might be explained by differences in the methods used to determine the occlusal plane. Variation in the choice of landmarks may also be a source of failure in IAN anesthesia in clinical settings (Nicholson, 1985; Keros et al., 2001). Also at variance with-out results, Nicholson (1985) found the MF to be located below the occlusal plane in a majority of subjects of Indian ethnicity. Whether these morphological divergences are due to ethnic differences, methods of measure or else needs further investigations.

The occlusal plane of the second premolar was higher than that from the occlusal plane of the first molar on either side. The distance to the occlusal plane of the first molar was similar to previous reports (Roberts and Sowray, 1979). During IAN anesthesia therefore if the reference is made at the second premolar occlusal plane there will be an error of about 3.45 to 4.56 mm above the MF. The occlusal plane of the first molar may be suggested as the best reference point to approach the inferior alveolar nerve intraorally.

The total width of the ramus and the distances from the mandibular notch to the mandibular angle, i.e. the total height of the ramus, were similar between sides. The MF was located more frequently on the posterior half of the ramus, in agreement with what has been reported previously (Oguz and Bozkir, 2002; Huang, 2003). Based on our findings, for successful IAN anesthesia the clinician should arrive at about 19.88 to 20.19 mm from the anterior border of the ramus in order to bring the needle point to the MF, about 10 mm (1 cm) above the occlusal surface of the first molar or 14 mm above the occlusal surface of the second premolar.

Conclusions and recommendations

This study shows that the MF is located above the occlusal plane of mandibular first molar and second premolar. Clinicians should make use of this information during the anesthetic procedures involving the IAN, more precisely should estimate the position of the MF to be 10.4 mm and 13.9 mm above the occlusal plane of the first molar or second premolar respectively and 20 mm from the anterior border of the ramus. Further investigations will allow to establish the corresponding measurements for Tanzanian women and compare them with the present ones for men.

Acknowledgements

We are indebted to Seleman Shomvi and Hamis Rajab, mortuary technicians in the Department of Anatomy, Muhimbili University of Health and Allied Sciences, for their commendable efforts during the preparation of the mandibular specimens for this study.

Declaration of no conflict of interest

The authors have no conflict of interest to declare.

References

- Devi R., Ama N., Manjunath K.Y., Balasubramanyam V. (2003) Incidence of morphological variants of mandibular lingula. *Indian J. Dent. Res.*14: 210-213.
- Hayward J., Richardson E.R., Malhotra S.K. (1977) The mandibular foramen: its anteroposterior position. *Oral Surg. Oral Med. Oral Pathol.* 44: 837-843.
- Huang J. (2003) Study on the location of mandibular foramen and the measurement of sigmoid notch and ramus. *Shanghai Kou Qiang Yi Xue* 12: 284-287.
- Jerolimov V., Kobler P., Keros J., Staničić T., Bagić I. (1998) Assessment of position of foramen mandibulae in recent adult population. *Coll. Antropol.* 22: 169-177.
- Keros J., Kobler P., Baucić I., Cabov T. (2001) Foramen mandibulae as an indicator of successful conduction anesthesia. *Coll. Antropol.* 25: 327-331.
- Kilarkaje N., Nayak S.R., Narayan P., Prabhu L.V. (2005) The location of the mandibular foramen maintains absolute bilateral symmetry in mandibles of different age groups. *Hong Kong Dent. J.* 2: 25-27.
- Madan G.A., Madan S.G., Madan A.D. (2002) Failure of inferior alveolar nerve block: exploring the alternatives. *J. Am. Dent. Assoc.* 133: 843-846.
- Malamed S.F. (2004) *Handbook of Local Anaesthesia*. 5th edn. St. Louis, Mosby.
- Mbajjorgu E.F. (2000) A study of the position of the mandibular foramen in adult black Zimbabwean mandibles. *Cent. Afr. J. Med.* 46: 184-190.
- Mwaniki D.L., Hassanali J. (1992) The position of mandibular and mental foramina in Kenyan African mandibles. *East. Afr. Med. J.* 69: 210-213.
- Nicholson M.L. (1985). A study of the position of the mandibular foramen in the adult human mandible. *Anat. Rec.* 212: 110-112.
- Oguz O., Bozkir M.G. (2002) Evaluation of location of mandibular and mental foramina in dry, young, adult human male, dentulous mandibles. *West Indian Med. J.* 51: 14-16.
- Potocnik I. and Bajrovic F. (1999) Failure of inferior alveolar nerve block in endodontics. *Endod. Dent. Traumatol.* 15: 247-225.
- Roberts D. H., Sowray J. H. (1979) *Local Analgesia in Dentistry*. J. Wright, Bristol.
- Souaga K., Adou A., Angoh Y. (2004) Topographical and morphological study of the mandibular foramen in black Africans from the Ivory Coast. *Odontostomatol. Trop.* 27: 17-21.
- Thangavelu K., Kannan R., Kumar N.S., Rethish E., Sabitha S., Sayeeganesh N. (2012) Significance of localization of mandibular foramen in an inferior alveolar nerve block. *J. Nat. Sci. Biol. Med.* 3: 156-160.
- Vinckier I. (2000) What is the cause of failures of local anaesthesia? *Rev. Belge Med. Dent.* 55: 41-50.