

Research Article: Human Anatomy Case Report

The clavicular part of the pectoralis major: a true entity of the upper limb on anatomical, phylogenetic, ontogenetic, functional and clinical bases. Case report and review of the literature

Fabrizio Barberini

Department of Anatomical, Histological, Forensic and Locomotor Apparatus Sciences, Section of Human Anatomy, University of Rome "La Sapienza", Rome, Italy

Submitted February 28, 2013; accepted revised July 12, 2013

Abstract

The pectoralis major consists of three parts: clavicular, sternocostal and abdominal. The first is usually separated from the deltoid by a deltopectoral triangular space, and often from the sternocostal part by another triangular space. The clavicular part is a new acquisition in Anthropoids, to optimize stabilization of the upper limb to the thorax thus permitting an increased limb mobility in Primates. It is synergetic with the deltoid in arm flexion and even more in adduction. This action is important in Humans, as the coracobrachialis becomes smaller in Mammals. Among non human Primates, those having cranially displaced shoulder joint show a significant clavicular origin of the pectoralis major. The clavicular origin might be necessary in flexion of the forelimb, when the humeral insertion of the muscle is on the same transverse plane as, or cranial to, the sternal manubrium. As to the blood and nerve supply, occurrence in Humans of a neuro-vascular pedicle for the clavicular part, shared with the deltoid, indicates a relatively morpho-functional independence of this part from the rest of the muscle. Under this regard, the width of the lateral pectoral nerve, which supplies the clavicular part of the muscle, may be related to a greater functional ability. Many manoeuvres for plastic and reconstructive surgery are performed by isolating the clavicular part of the pectoralis major. Indeed, this part may be considered as a true, self-standing anatomical entity. In fact, it has morphological individuality, peculiar bony attachments and functional autonomy, so that it is simply adjacent to the sternocostal part. Moreover, according to phylogenesis, this topographic relation develops secondarily, in parallel with the development of the clavicle. Therefore, it may be regarded not only as a simple part of an extrinsic muscle of the thorax, but also as an intrinsic muscle of the upper limb.

Key words

Comparative anatomy, development, embryology, human anatomy, muscle function.

Key to abbreviations:

PM = pectoralis major

CP = clavicular part of pectoralis major

SCP = sternocostal part of pectoralis major

AP = abdominal part of pectoralis major

EMG = electromyography

Corresponding author. E-mail: fabrizio.barberini@libero.it.

Introduction

The pectoralis major (PM) consists of a clavicular (CP), a sternocostal (SCP) and an abdominal (AP) part. The CP is separated from the deltoid muscle by a deltopectoral triangular space. In addition, the CP is often separated from the SCP by the interposition of another triangular space, which we also observed in our dissection (see the case report below). The concomitant presence of these two spaces, separating the CP from the deltoid and the SCP, makes the CP resemble a single muscle. On account of the frequent occurrence of such a feature, a possible significance of the CP, based on comparative and human anatomy, as well as embryological and functional aspects, is discussed.

Operatively, the CP is used for myocutaneous flaps to cover acromioclavicular defects, repair injuries caused by cervical malignant tumours (Po-Wing Yuen, 2006), or recover motility in cases of facial paralysis (Goyal et al., 2006). These manoeuvres are carried out by mobilizing the CP, which may be independently transferred on its vascular pedicle (Candiani et al., 1994).

Case report

Dissection was performed on a thorax of a Caucasian male cadaver. The body wall was opened along the anterior median line, the anterior border of the clavicle prolonged to the superior and outer margin of the shoulder, a horizontal line joining this margin with the base of the axilla and the inferior border of the anterior thoracic wall; the skin and subcutaneous layer were reversed laterally (Fig. 1). After removing subcutaneous tissue the PM appeared, as expected, under the pectoral fascia. The CP of the muscle, however, was separated from the SCP by the interposition of a triangular space. This space was filled by adipose tissue and extended from the base, corresponding to the sternoclavicular joint, laterally to the apex, corresponding to the confluence of the two muscle parts. It measured 2 cm in width at the base and 7 cm in length (Fig. 2). After divaricating its borders it clearly appeared to separate completely the two muscle parts, from the anterior to the posterior aspect (Figs. 3 and 4). The observation of a separation between the CP and SCP was the occasion to review the literature on this muscle.

Comparative anatomy

The clavicle is absent from Ungulates and Cetaceans, whereas in Primates it is well conformed. In brachiators, such as the monkeys, it is prominent and *Homo sapiens* retains this feature (Kardong, 2002). The appendicular muscles are composed of smaller, distinct formations. Thus, the deltoid may be subdivided into two parts (scapular and clavicular), with a common humeral insertion (Stefanelli, 1958). These aspects are complicated by musculature of other regions contributing to that of the limbs of Tetrapods (Kardong, 2002). Concerning the PM, this may be divided in parts which spread on the chest like a fan (Hildebrand, 1974). In Rodents it is described as a pectoral complex consisting of two superficial and one deep muscles: respectively,

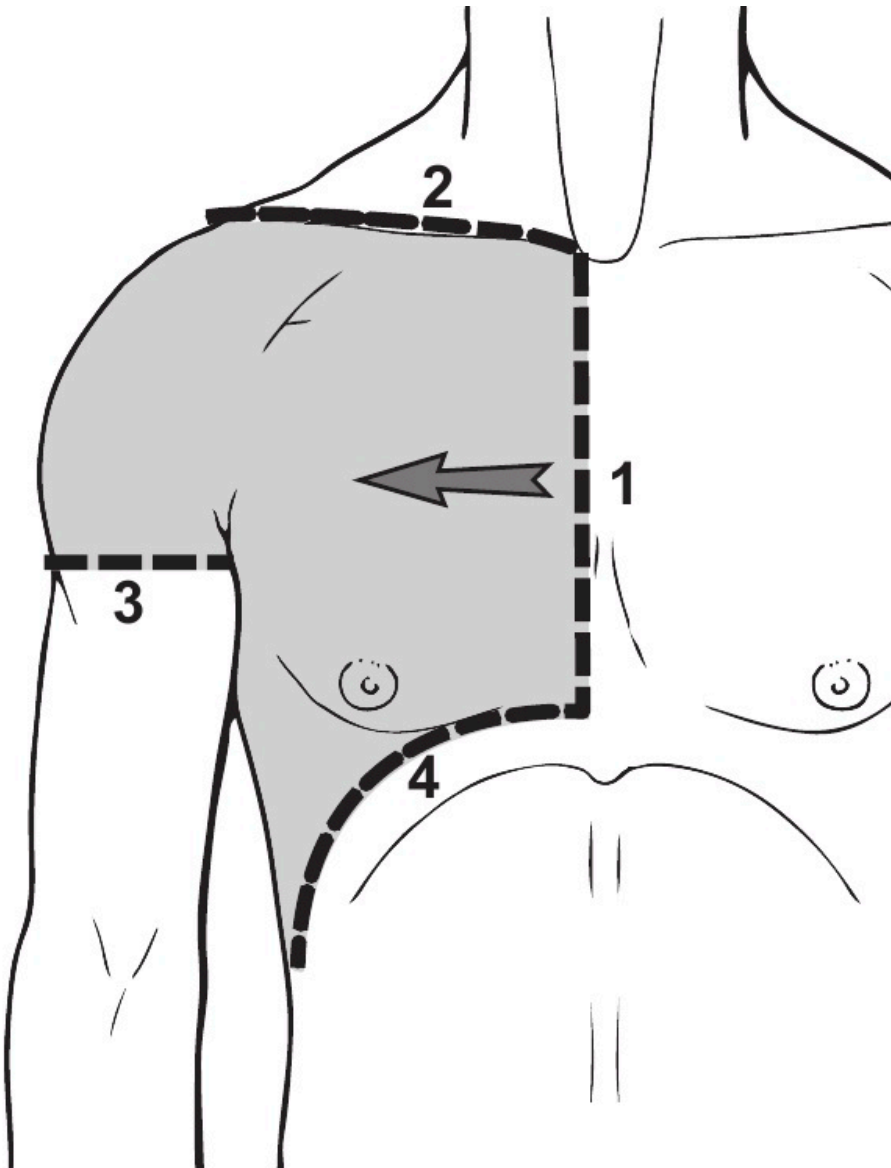


Figure 1 – Drawing of the dissection process. The body wall was opened along the anterior median line (1), the anterior border of the clavicle prolonged to the superior and outer margin of the shoulder (2), a horizontal line joining this with the base of the axilla (3), and the inferior border of the anterior thoracic wall (4). The skin and subcutaneous layer have been reversed laterally (arrow).

a superficial descending muscle that corresponds to the CP of the PM of Primates, a superficial transverse muscle corresponding to the SCP and a deep ascending muscle corresponding to the AP (Popesko et al., 1992). The arrangement of the PM in two

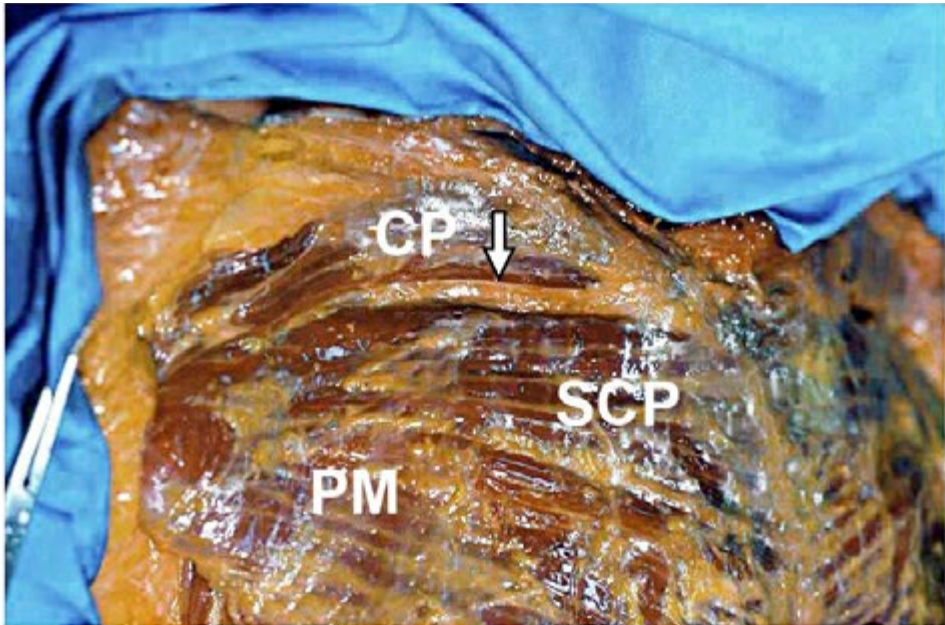


Figure 2 – The thoracic anterior surface has been dissected and PM exposed. Under the fascia, a triangular space (arrow) between the clavicular (CP) and sternocostal (SCP) parts of the muscle is evident. This space is filled by adipose tissue; its base, medial, corresponds to the sternoclavicular joint and the apex, lateral, to the confluence of the two parts.

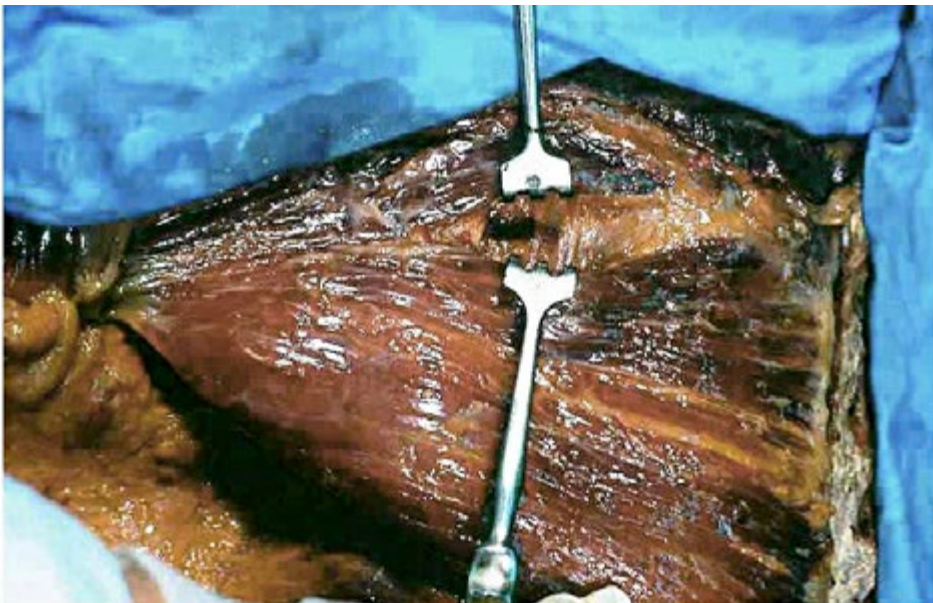


Figure 3 – The triangular intermuscular space has been divaricated to show its depth.

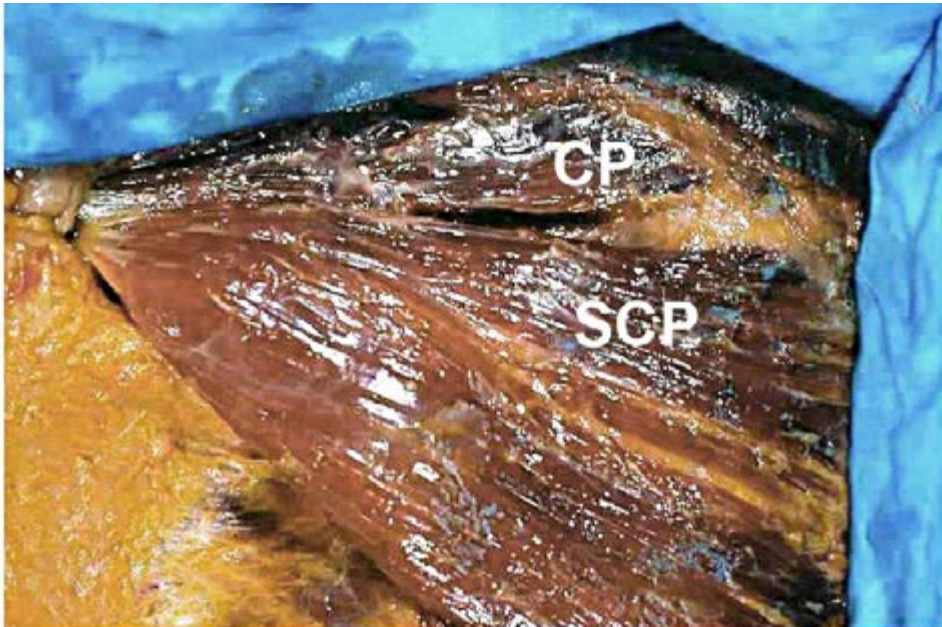


Figure 4 – After autopsy tools removal the sharp separation between the CP and the SCP is apparent.

distinct layers, superficial and deep, is common to different species of Mammals, such as the pig and some Rodents (Testut, 1884). In the cat, which has a reduced clavicle, the PM is made up of two parts, superior and inferior, from the sternum to the humerus (Wischnitzer, 1996). Among Primates, a significant clavicular origin of the PM is absent from prosimians whereas it is constant in Anthropoids (Stern et al., 1980). It occurs in Humans (Loth, 1931) and may cause variations in the course of the cephalic vein (Testut, 1884; Le Double, 1897). Occurrence of a significant CP is related to the development of the clavicle (Loth, 1931).

Human anatomy

The deltopectoral triangle in Humans is very variable in width and may even disappear, the clavicular part of the deltoid and the CP then fusing together in a common mass (Perrin, 1871; Testut, 1884; Le Double, 1897). In this case, the CP might be regarded as a prosecution of the deltoid along the clavicle. Sometimes, the clavicular part of the deltoid sends an anastomotic slip to the CP (Perrin, 1871). On the other hand, the CP and the SCP may be separated by a triangular space, extending as far as the humerus (Testut, 1884; Le Double, 1897). This space may allow observation of the 2nd and 3rd rib, with a portion of the pectoralis minor (Flesch, quoted by Testut, 1884). It seems to be the larger, the narrower is the deltopectoral one, in a sort of balance between the two spaces (Testut, 1884). The humeral tendon of the PM is formed by two layers, the anterior formed by descending fibres, belonging to the CP, and the

posterior formed by horizontal and ascending fibres, belonging to the SCP and AP (Testut, 1884; Tobin, 1985; Sauerland, 1994).

Concerning the blood supply, two distinct (deltoid and pectoral) branches of the thoraco-acromial artery occur in the lateral and medial triangular spaces separating the CP from the deltoid and from the SCP respectively (Romanes, 1981; Po-Wing Yuen, 2006). By angiography in cadavers, the pectoral branch has been considered the main blood source for the PM (Yang et al. 2003). X-rays of injected cadavers demonstrated that the major arterial supply to the SCP is the pectoral branch, a further, clavicular branch being only secondary (Wei et al. 1984). If a muscle has more than a single vascular pedicle, a comparative study of each pedicle may be useful (Peter and Felix, 1986). The two muscle parts have indeed separated blood supplies, the CP from the deltoid branch and the SCP mainly from the pectoral (Manktelow et al., 1980). Angiography confirmed the segmentation of the PM in two sub-units, clavicular and sternocostal, provided with individual vascular supplies (Candiani et al., 1994). Well-developed anastomoses connecting the internal and lateral thoracic arteries and the pectoral branch of the thoraco-acromial artery with each other, but not the deltoid branch of the last artery, have been reported in injected cadavers (Freeman et al., 1981). Other dissections confirmed an autonomous vascular supply for the CP (Reid and Taylor, 1984; Chaffai and Mansat, 1988).

As to innervation, even if anastomoses occur, the CP is supplied by the lateral pectoral nerve (C5-C7) and the SCP, together with the pectoralis minor, by the medial pectoral nerve (C8-T1) (Goldberg and Mazzei, 1977). This distribution has been corroborated by dissection of the lateral subclavicular region. In all cases the lateral pectoral nerve supplied the CP and the medial pectoral nerve supplied the pectoralis minor and then the SCP and AP (Gardetto et al., 2003; Macchi et al., 2007). The lateral pectoral nerve appeared larger than the medial (Gardetto et al., 2003). Such a feature has also been observed *in vivo*, i.e. in patients undergoing plastic surgery (Hoffman and Elliott, 1987). This would indicate heavier innervation (Hoffman and Elliott, 1987; Gardetto et al., 2003) and, therefore, greater functional ability of the CP than the SCP. Extensive survey on 105 cadavers confirmed the CP to be supplied by the lateral pectoral nerve together with the deltoid branch of the thoraco-acromial artery (Tobin, 1985). When the CP was detached and reversed on the arm, branches of the lateral pectoral nerve together with branches of the thoraco-acromial artery were detected penetrating its posterior surface (Sauerland, 1994). Other anatomical observations have shown that the lateral pectoral nerve arises cranially behind the clavicle and runs under the subclavius along the deltopectoral triangle. Many branches enter the CP medially to the coracoid process and laterally to its origin from the clavicle (Corten et al., 2003).

Embryology

The development of the body wall muscles in Humans proceeds from masses of condensed mesenchyme, named premuscular masses. In a 5 week-old human embryo one of these masses occupies most of the space between the costal portion of the muscular plate system and the integument. This mesenchymal mass, lateral to the myotomic system in the region of the arm, extends from the first cervical to the 7th thoracic myotome. It shades off into the surrounding loose mesenchyme except at the anterior

end, at about the level of the first two ribs, where it splits into several masses (Bardeen and Lewis, 1901; Lewis, 1901). At this stage of development the costal processes of both the sclerotomes and the myotomes are extended into the body wall. The upper limb is more advanced in development than the lower. At the level of the first intercostal space four premuscularanlagen are recognizable as partitions of the premuscular lateral mass. The first of these develops ventral to the arm and the brachial plexus, reaching the arm premuscular sheath near the proximal extremity of the humerus. It will differentiate into the pectoral muscles, so that it may be termed premuscular pectoral mass. The second component of the lateral premuscular mass passes dorsal to the arm and brachial plexus and, like the first one, joins the arm premuscular sheath. It constitutes the latissimus dorsi premuscular mass. The third component, parallel to the ventral portion of the cervical myotomic column, represents the levator scapulae and serratus anterior premuscular mass. The fourth and most dorsal component is thinner and less clearly defined than the others, it is the rhomboid premuscular mass. The proximal extremity of the humerus is continuous with the scapula. This is a flattened oval mass embedded in the scapular premuscular tissue. No coracoid or acromion processes are evident. The clavicle is not yet formed, its core consists of dense mesenchyme located inside the premuscular mass (Bardeen and Lewis, 1901; Lewis, 1901).

One week later in development the costal processes extend ventrally, the shape of the scapula changes, both the acromion and coracoid processes are present and of large size. The clavicle has begun to develop and consists of an ill-defined mass of condensed tissue projecting about one-half the distance from the acromion to the tip of the first rib. The lateral premuscular mass is completely divided into distinct muscular groups. The tissue of these groups show a fibrillar structure. The first group, the only one passing ventral to the brachial plexus, constitutes the pectoral muscular mass. It extends from the level of the 3rd rib to the humerus and the clavicle, however there is no insertion on the ribs. The pectoral mass is now spread out into a large sheet, which has split into the PM and pectoralis minor muscles. The PM differentiates cranio-caudally, beginning from the CP (Mosconi and Kamath, 2003). The CP arises from the medial one-third of the clavicle and passes to the humerus. Here it overlaps the humeral attachment of the SCP, which arises from the first six ribs and the sternal anlage. The CP and the SCP are separated by a considerable interval (Lewis, 1901).

At the 7th week the clavicle is well developed and overcomes the first rib, contacting the sternal anlage. Of the whole premuscular pectoral mass, the part first adhering to the skeleton, i.e. the CP, is most often present (about 90% of cases). The SCP and AP, which adhere only later to the skeleton, are small or absent (Bing, 1902; Mosconi and Kamath, 2003).

According to Lewis (1901), failure in caudal growth of the premuscular pectoral mass may cause agenesis or hypoplasia of the caudal parts of this muscle with persistence of the CP only (Goldberg and Mazzei, 1977; Yamasaki, 1989; Cerimele et al., 1991). Such a condition occurs in Poland's syndrome, a congenital unilateral thoracomammary malformation characterized by aplasia of the SCP and persistence of the CP (Muhlbauer and Wangerin, 1977; Pasquali et al., 1993; Perez Aznar et al., 1996; Ferraro et al., 2005). Thus, agenesis of the SCP might occur, due to failed blood supply by the internal thoracic artery during a critical embryonic period (about the 6th week of development), before a sufficient collateral circulation forms (Bouwes Bavinck and Weaver, 1986; Perez Aznar et al., 1996). This would demonstrate a dif-

ferent blood source for SCP and CP already in the embryo, i.e. internal thoracic and thoraco-acromial arteries respectively.

According to embryology, the occurrence of a triangular space between the CP and SCP, like that described in the present case report, would just represent the persistence to adulthood of the considerable interval between these two muscle parts occurring during development (Lewis, 1901).

Function

In brachiation (locomotion by arm swinging from one hold to the other) the clavicle is large, and in monkeys it serves to transfer the body weight to the arm (Kardong, 2002). Functional adaptation related to brachiation is very important for Primates. By electromyography (EMG) on the PM and acromio-deltoid in monkeys, distinct roles for the CP and SCP were described (Stern et al., 1980). During vertical climbing, the SCP is propulsive for the whole, long support phase, while in all monkeys the activity of the CP ceases earlier in this phase. In spider monkey, which have muscle fibres departing from the sternal manubrium and not from the clavicle, the propulsive activity of the CP persists somewhat longer. In all monkeys the common role of the CP is to initiate the recovery phase of the limb. In woolly monkey, which have a significant origin of the muscle from the clavicle, the cranial fibers are predominantly active during the swing phase of the locomotion. During arm swinging the greatest amplitude of activity of the CP occurs in the gibbon at midswing. This maximum is essential for a rapid swing of the forelimb (MacKinnon, 1974; Mittermeier and Fleagle, 1976). According to Stern et al. (1980), a significant clavicular origin might be necessary to flex the forelimb of monkeys, in which the humeral insertion of the muscle is on the transverse plane of, or cranial to the sternal manubrium. Such a location is related to an increased mobility for climbing and suspending.

Recording of muscle activity during pronograde quadrupedalism suggested flexion of the adducted forelimb to be the unique role for the CP, while, as in vertical climbing, the SCP is propulsive. The cranial origin of the PM in non human Primates is related to strength or rapidity of flexion of the adducted forelimb, allowing a rapid pronograde progression on the trees (Ashton and Oxnard, 1963; Stern et al., 1980).

Concerning Humans, adult Caucasians have a shoulder joint on the level of the sternal manubrium, but in human fetus it is higher. So, it might be speculated a higher position having occurred also in human ancestors (Schultz, 1926). In modern Humans, whose shoulder joint is relatively low, the CP is retained and the PM is considered the most powerful adductor of the shoulder and a secondary intrarotator of the arm (Lee and Chun, 1991; Mysnyk and Johnson, 1991). In particular, the CP serves, as in non human Primates, for the flexion of adducted forelimb. On the whole, the clavicular origin of the PM, which the human ancestors retained from other Primates, would have become a preadaptation to the muscle use in bipedal descendants (Stern et al., 1980).

In modern Humans different functions are attributed to the CP and SCP. The former would be adductor and flexor of the arm, whereas the latter would be only adductor. The important role of the CP in arm flexion and intrarotation has been documented by EMG (Boccardi et al., 1991). In addition, dissection and EMG inves-

tigated the segmental anatomy of shoulder joint muscles to establish if these, including deltoid and PM, could be subdivided into discrete parts, and to determine if a segmental activation pattern revealed by surface EMG depend on the line of action of the applied force and the moment arm (i.e. the distance between the axis and the line of action of the force) for the intended movement. Differences were evident in the geometry of each segment in relation to moment arm and orientation of line of action and electric stimulation showed significant differences in the activation pattern of segments. These results originated the expression "muscles within muscles" (Wickham et al., 2004). A three-dimensional study of the PM on dissected and digitized specimens of cadavers showed an architecturally uniform CP, whereas the SCP appeared segmented in 6-7 units (Fung et al., 2009).

In cases of partial agenesis of PM, with failed development of the SCP and persistence of the CP, the functionality of the shoulder and the arm usually is not significantly affected (Poland's syndrome) (Hollinshed and Jenkins, 1981; Mosconi and Kamath, 2003); in the absence of the SCP, the CP may be prominent together with a hypertrophied clavicular deltoid during adduction against resistance (Cerimele et al. 1991; Lee and Chun, 1991).

In conclusion, on the basis of anatomical, comparative, embryological, functional and clinical data, the CP of PM may be considered as a true entity, rather than simply a part of a larger muscle. According to phylogenesis, this topographic relation has developed secondarily, in parallel with the development of the clavicle; therefore, it should be regarded not only as part of an extrinsic muscle of the thorax, but also as an intrinsic muscle of the upper limb.

Acknowledgments

The study was supported by Grants from MIUR, Italy, 2009. The Author would like to thank Dr. Bernardo Luraschi for skilful technical assistance in the preparation of figures.

References

- Ashton E.H., Oxnard C.E. (1963) The musculature of the primate shoulder. *Trans. Zool. Soc. (Lond.)* 29: 553-650.
- Bardeen C.R., Lewis W.H. (1901) Development of the limbs, body wall and back in man. *Am. J. Anat.* 1: 1-35.
- Bing R. (1902) Über angeboren muskeldefekt. *Virchows Arch. Pathol. Anat.* 170: 175-228.
- Boccardi S., Ruggeri A., Guizzardi S., Sandrini G. (1991) *I Muscoli*. Masson, Milano.
- Bouwes Bavinck J.N., Weaver D.D. (1986) Subclavian artery supply disruption sequence: hypothesis of a vascular etiology for Poland, Klippel-Feil, and Möbius anomalies. *Am. J. Med. Genet.* 23: 903-918.
- Candiani P., Campiglio G.L., Saccheri S., Roviario G.C. (1994) The versatility of pectoralis major muscle and musculocutaneous flaps in the reconstruction of the oral cavity and of the anterior chest wall. *Int. Surg.* 79: 130-134.

- Cerimele D., Marinelli I., Scarfi G. (1991) Agenesis parziale del muscolo grande pettorale. *Arch. Putti Chir. Organi Mov.* 39: 277-280.
- Chaffai M.A., Mansat M. (1988) Anatomic basis for the construction of a musculotendinous flap derived from the pectoralis major muscle. *Surg. Radiol. Anat.* 10: 273-282.
- Corten E.M., Schellekens P.P., Bleys R.L., Kon M. (2003) The nerve supply to the clavicular part of the pectoralis major muscle: an anatomical study and clinical application of the function-preserving pectoralis major island flap. *Plast. Reconstr. Surg.* 112: 969-975.
- Ferraro G.A., Perrotta A., Rossano F., D'Andrea F. (2005) Poland syndrome: description of an atypical variant. *Aesth. Plast. Surg.* 29: 32-33.
- Freeman J.L., Walker E.P., Wilson J.S., Shaw H.J. (1981) The vascular anatomy of the pectoralis major myocutaneous flap. *Br. J. Plast. Surg.* 34: 3-10.
- Fung L., Wong B., Ravichandiran K., Agur A., Rindlisbacher T., Elmaraghy A. (2009) Three-dimensional study of pectoralis major muscle and tendon architecture. *Clin. Anat.* 22: 500-508.
- Gardetto A., Thaler C., Kiechl S., Maurer H., Piza-Katzer H. (2003) Isolated compression of the pectoral nerve resulting in atrophy of the major pectoral muscle. *Muscle Nerve* 28: 760-763.
- Goldberg M.J., Mazzei R.J. (1977) Poland syndrome: a concept of pathogenesis based on limb bud embryology. *Birth Defects Orig. Artic. Ser.* 13: 103-115.
- Goyal N., Harjeet K., Gupta M. (2006) Bilateral variant origin of pectoralis major. *Nepal Med. Coll. J.* 8: 65-68.
- Hildebrand M. (1974) *Analysis of Vertebrate Structure.* John Wiley & Sons, New York.
- Hoffman G.W., Elliott L.F. (1987) The anatomy of the pectoral nerves and its significance to the general and plastic surgeon. *Ann. Surg.* 205: 504-507.
- Hollinshed W.H., Jenkins D.B. (1981) *Functional Anatomy of Limbs and Back.* 5th ed. Saunders, Philadelphia.
- Kardong K. (2002) *Vertebrates. Comparative Anatomy, Function, Evolution.* 3rd ed. McGraw-Hill, Boston.
- Le Double A.F. (1897) *Traité des Variations du Système Musculaire de l'Homme et de Leur Signification au Point de Vue de l'Anthropologie Zoologique.* Schleicher Frères, Paris.
- Lee Y.H., Chun S. (1991) Congenital absence of pectoralis major: a case report and isokinetic analysis of shoulder motion. *Yonsei Med. J.* 32: 87-90.
- Lewis W.H. (1901) The development of the arm in man. *Am. J. Anat.* 1: 145-183.
- Loth E. (1931) *Anthropologie des Parties Molles.* Masson & Cie, Paris.
- Macchi V., Tiengo C., Porzionato A., Parenti A., Stecco C., Mazzoleni F., De Caro R. (2007) Medial and lateral pectoral nerves: course and branches. *Clin. Anat.* 20: 157-162.
- MacKinnon J. (1974) The behaviour and ecology of wild orangutans (*Pongo pygmaeus*). *Anim. Behav.* 22: 3-74.
- Manktelow R.T., McKee N.H., Vettese T. (1980) An anatomical study of the pectoralis major muscle as related to functioning free muscle transplantation. *Plast. Reconstr. Surg.* 65: 610-615.
- Mittermeier R.A., Fleagle J.C. (1976) The locomotor and postural repertoires of *Ateles geoffroyi* and *Colobus guereza*, and reevaluation of the locomotor category semibrachiation. *Am. J. Phys. Anthropol.* 45: 235-256.

- Mosconi T., Kamath S. (2003) Bilateral asymmetric deficiency of the pectoralis major muscle. *Clin. Anat.* 16: 346-349.
- Muhlbauer W., Wangerin K. (1977) Embryology and etiology of the Poland and Amazon syndromes. *Handchirurgie* 9: 147-152.
- Mysnyk M.C., Johnson D.E. (1991) Congenital absence of the pectoralis muscles in two collegiate wrestling champions. *Clin. Orthop. Relat. Res.* 265: 183-186.
- Pasquali C., Mignani G., Arlecchini S., Nanni M.L., Marchiodi L. (1993) L'agenesia del muscolo pettorale. *Chir. Organi Mov.* 78: 173-176.
- Perez Aznar J.M., Urbano J., Garcia Laborda E., Quevedo Moreno P., Ferrer Vergara L. (1996) Breast and pectoralis muscle hypoplasia. A mild degree of Poland's syndrome. *Acta Radiol.* 37: 759-762.
- Perrin J.B. (1871) Notes of some variations of the pectoralis major, with its associate muscles. *J. Anat. Physiol.* 5: 233-240.
- Peter J.M., Felix E.G. (1986) Vascular anatomy of the pectoralis major myocutaneous flap. *Arch. Otolaryngol. Head Neck Surg.* 112: 66-69.
- Popesko P., Rajtova V., Horak J. (1992) *Colour Atlas of the Anatomy of Small Laboratory Animals*. Wolfe Publishing, London.
- Po-Wing Yuen A. (2006) Preservation of lateral thoracic artery to improve vascular supply of distal skin without compromising pedicle length in harvesting pectoralis major myocutaneous flap. *J. Plast. Reconstr. Aesthet. Surg.* 59: 1433-1435.
- Reid C.D., Taylor G.I. (1984) The vascular territory of the acromiothoracic axis. *Br. J. Plast. Surg.* 37: 194-212.
- Romanes G.J. (1981) *Cunningham's Textbook of Anatomy*, 12th ed. Oxford Univ. Press, Oxford.
- Sauerland E.K. (1994) *Grant's Dissector*. 11th ed. Williams & Wilkins, Baltimore.
- Schultz A. H. (1926) Fetal growth of man and other primates. *Quart. Rev. Biol.* 1: 465-521.
- Stefanelli A. (1958) *Anatomia Comparata. Morfologia Animale Comparata, Ecologica e Sperimentale*. Ediz. Ateneo, Roma.
- Stern J.T., Wells J.P., Jungers W.L., Vangor A.K., Fleagle J.G. (1980) An electromyographic study of the pectoralis major in atelines and hylobates, with special reference to the evolution of a pars clavicularis. *Am. J. Phys. Anthropol.* 52: 13-25.
- Testut L. (1884) *Les Anomalies Musculaires chez l'Homme Expliquées par l'Anatomie Comparée. Leur Importance en Anthropologie*. Masson, Paris.
- Tobin G.R. (1985) Pectoralis major segmental anatomy and segmentally split pectoralis major flaps. *Plast. Reconstr. Surg.* 75: 814-824.
- Wei W.I., Lam K.H., Wong J. (1984) The true pectoralis major myocutaneous island flap: an anatomical study. *Br. J. Plast. Surg.* 37: 568-573.
- Wickham J.B., Brown J.M.M., McAndrew D.J. (2004) Muscles within muscles: anatomical and functional segmentation of selected shoulder joint musculature. *J. Musculoskeletal Res.* 8: 57-73.
- Wischnitzer S. (1996) *Atlas and Dissection Guide for Comparative Anatomy*. Freeman W.H. & Co., San Francisco.
- Yamasaki M. (1989) Anatomical study on 2 cases of the congenital partial defect of pectoralis major and minor muscles. *Anat. Anz.* 168: 423-432.
- Yang D., Marshall G., Morris S.F. (2003) Variability in the vascularity of the pectoralis major muscle. *J. Otolaryngol.* 32: 12-15.