

Research Article: Human Anatomy Case Report

An ancient anatomic variation: bilateral elongated styloid process of cranium

M. Bulent Ozdemir¹, Mehmet Okunak², Aylin Koseler³, Celal Simsek², Erol Atalay³, Goksin Nilufer Yonguc^{1,*}

¹ Faculty of Medicine, Department of Anatomy, Pamukkale University, Denizli, Turkey

² Faculty of Science and Letters, Part of Archaeology, Pamukkale University, Denizli, Turkey

³ Faculty of Medicine, Department of Biophysics, Pamukkale University, Denizli, Turkey

Submitted February 29, 2012; accepted April 26, 2012

Summary

The elongated stylohyoid process presents with considerable anatomic variability. We report here on an ancient cranium with bilateral elongated styloid process, 3.3 cm on the right side and 5.1 cm on the left side, found during the examination of excavated bones of 2000 years ago (first half of 1st century AD) from the old Greek-Roman city-of Leodikya in Turkey. We determined the gender as female, from the examination of the skeleton (especially skull and pelvic bones). No other variation was observed. On the basis of embryology, the reason for this variation may be partial ossification of the second pharyngeal arch cartilage in the region which commonly becomes the stylohyoid ligament. Although elongation of the styloid process is common, it is important to report this ancient variation, in order to help to compare the bone variations between ancient and modern humans and the contribution of genetic and environmental determinants.

Key words

Human; archaeology; palethnology; stylohyoid process; second pharyngeal arch; Reichert's cartilage.

Introduction

Elongation of the styloid process or ossification of the stylohyoid ligament is common (Satyapal and Kalideen, 2000; Kay et al., 2005). We present here an ancient case of bilateral elongated stylohyoid bone in a women who lived approximately 2000 years ago (first half of 1st century AD) in the old Greek-Roman city of Leodikya (Laodicea) in Turkey. To the best of our knowledge, an ancient anatomic variation like this one has not been published before.

Case report

The skeleton was found at Northern Necropolis in 2008 during the excavation of the old Greek-Roman city of Leodikya in Denizli/Turkey. Roof tiles were stacked

*Corresponding author. E-mail: nyonguc@pau.edu.tr.




Figure 1 – The tomb of the reported skeleton.

above the skeleton which was placed supine (Figure 1, 2). On the basis of stratigraphic level and similar examples, the tomb was dated to the beginning of the 1st century AD (Simsek, 2007, 2011). The bone surfaces were smooth with no evidence of fracture or degenerative changes. During the examination of the cranial bones, we detected bilaterally abnormally long styloid processes. The length was 3.3 cm and 5.1 cm on the right and left side, respectively. The circumference of the process at the most thick and thin parts, respectively, was 1.9 cm and 0.4 cm on the right side and, 1.7 cm and 0.5 cm on the left side (Figure 3). No variation was observed in the other bones, including atlas and axis.

Discussion

The stylohyoid process correlates with the anatomy and embryology of the second pharyngeal arch cartilage (Reichert's cartilage), which is the origin of several structures such as the styloid process of the temporal bone, the lesser horn of the hyoid bone, and the stylohyoid ligament between these portions (Satyapal and Kalideen, 2000; Gozil et al., 2001; Prasad et al., 2002; Basekim et al., 2005; Kay et al., 2005; Rodriguez-Vázquez et al., 2006; Vougiouklakis, 2006; Ramadan et al., 2007) The styloid

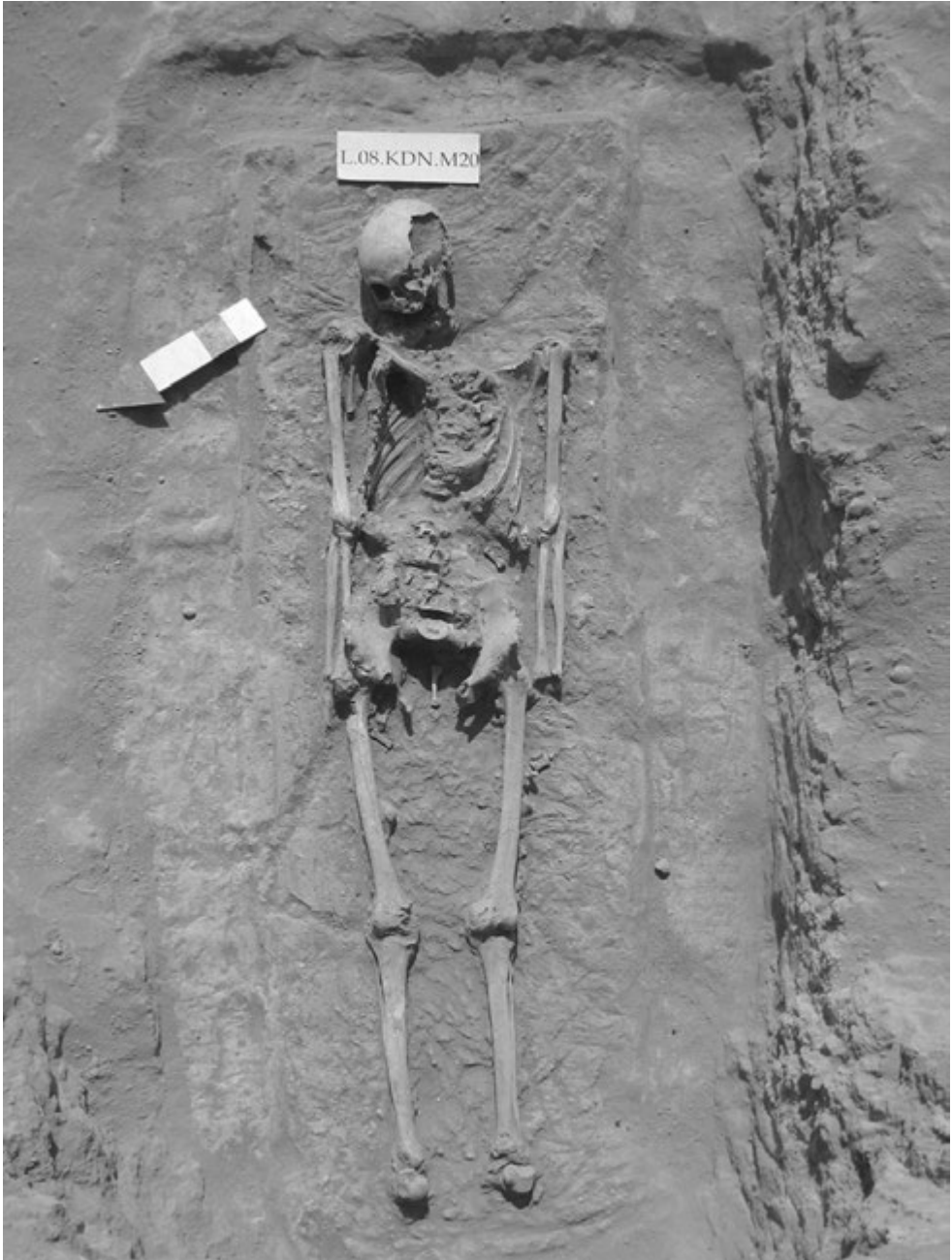


Figure 2 – The skeleton inside the tomb.




Figure 3 – Elongated styloid processes: *, right; **, left. Calibration scale = 10 cm.

process is formed by the ossification of the longer and larger cranial segment of that cartilage. Occasionally, various degrees of ossification of the second arch cartilage may extend from the styloid process along the stylohyoid ligament. Several theories have been proposed to explain the ossification of the stylohyoid ligament. These include degenerative changes, metaplastic alterations due to traumatic stimuli, and spontaneous variation in which the stylohyoid ligament is ossified at an early stage or contains cartilaginous remnants that are ossified later (Rodriguez-Vázquez et al., 2006; Yagcı et al., 2008). The styloid process and stylohyoid ligament ossification has been classified according to the shape and length: normal, elongated, bent, segmented, pseudoarticulated, and distally ossified and fixed to the lesser horn of the hyoid bone (Gozil et al., 2001). The incidence of complete ossification of the stylohyoid ligament has been reported as 0.09% in a series of 1,215 forensic autopsies (Vougiouklakis, 2006).

Most patients are asymptomatic. When symptoms onset, ‘Eagle Syndrome’ may occur, which is an uncommon but important cause of chronic head and neck pain (Dinkar and Amonkar, 2003). The syndrome was first described by Eagle (1937): the elongated styloid process can cause craniofacial and cervical pain, difficulties in swallowing, secondary glossopharyngeal neuralgia, radiating pain into the orbit and maxillary region (Soh, 1999; Prasad et al., 2002; Dinkar and Amonkar, 2003). There is little correlation between the extent of the ossification and the severity of the symptoms (Gozil et al., 2001; Prasad et al., 2002; Basekim et al., 2005; Kay et al., 2005).

Conclusion

Given the occurrence of bilateral elongated styloid process variation in contemporary humans, reports on this variation in ancient populations, if and when they will

become more numerous, may be of help in understanding the genetic and environmental determinants of anatomic variations.

Acknowledgement

This case was obtained during a study that has been supported by Pamukkale University Research Grant BAP:2010-KMR024.

References

- Basekim C.C., Mutlu H., Güngör A., Süit E., Pekkafuli Z., Kutlay M., Çolak A., Ozturk E., Kizilkaya E. (2005) Evaluation of styloid process by three-dimensional computed tomography. *Eur. Radiol.* 15 (1): 134-139.
- Dinkar, Amonkar S.S. (2003) Eagle's syndrome: review of literature and case report. *Indian J Dent Res.* 14(3): 162-168.
- Eagle W.W. (1937) Elongated styloid process: report of two cases. *Arch. Otolaryngol.* 25(5): 584-587.
- Gozil R., Yener N., Calguner E., Araç M., Tunç E., Bahçelioglu M. (2001) Morphological characteristics of styloid process evaluated by computerized axial tomography. *Ann. Anat.* 183(6): 527-535.
- Kay D.J., Har-El G., Lucente F.E. (2001) A complete stylohyoid bone with a stylohyoid joint. *Am. J. Otolaryngol.* 22(5): 358-361.
- Prasad K.C., Kamath M.P., Reddy K.J., Raju K., Agarvval S. (2002) Elongated styloid process (Eagle's syndrome): a clinical study. *J. Oral Maxillofac. Surg.* 60(2): 171-175.
- Ramadan S.U., Gokharman D., Tunçbilek I., Kaçar M., Koşar P., Koşar U. (2007) Assessment of the stylohyoid chain by 3D-CT. *Surg. Radiol. Anat.* 29(7): 583-588.
- Rodriguez-Vázquez J.F., Merida-Velasco J.R., Verdugo-López S., Sánchez-Montesinos I., Merida-Velasco J.A. (2006) Morphogenesis of the second pharyngeal arch cartilage (Reichert's cartilage) in human embryos. *J. Anat.* 208 (2): 79-189.
- Satyapal K.S., Kalideen J.M. (2000) Bilateral styloid chain ossification: case report. *Surg. Radiol. Anat.* 22(3-4): 211-212.
- Simsek C. (2011) Laodikeia Nekropolü (2004-2010 Yılı), Laodikeia Çalışmaları, I.2, İstanbul: 662, Kat. no. L.08.KDN.M20.
- Simsek C. (2007) Laodikeia (Laodikeia ad Lycum), Ege Yayinlari, İstanbul.
- Soh K.B. (1999) The glossopharyngeal nerve, glossopharyngeal neuralgia and the Eagle's syndrome-current concepts and management. *Singapore Med. J.* 40(10): 659-665.
- Vougiouklakis T. (2006) Overview of the ossified stylohyoid ligament based in more than 1,200 forensic autopsies. *J. Clin. Forensic Med.* 13 (5): 268-270.
- Yagci A.B., Kiroglu Y., Ozdemir B., Kara C.O. (2008) Three-dimensional computed tomography of a complete stylohyoid ossification with articulation. *Surg. Radiol. Anat.* 30(2): 167-169.