

Research article: Basic and applied anatomy

## **Semi-quantitative and qualitative evaluation of pial leptomeningeal collateral circulation in acute ischemic stroke of the anterior circulation: the Careggi Collateral Score**

Salvatore Mangiafico<sup>1</sup>, Arturo Consoli<sup>1,\*</sup>, Leonardo Renieri<sup>1</sup>, Andrea Rosi<sup>2</sup>, Alioscia De Renzis<sup>2</sup>, Chiara Vignoli<sup>2</sup>, Leonardo Capaccioli<sup>2</sup>

<sup>1</sup> Interventional Neuroradiology Unit, Careggi University Hospital, Florence, Italy

<sup>2</sup> Department of Radiology, Careggi University Hospital, Florence, Italy

Submitted January 8, 2013; accepted revised April 21, 2013

### Summary

**Introduction:** The imaging of ischemic penumbra in acute stroke is a debated issue and establishing commonly accepted criteria is difficult. Computerized tomography-perfusion studies conducted in animals have showed that the modifications occurring in the brain parenchima are part of a dynamic and progressive process involving the microcirculation. The purpose of this paper is to propose a new angiographic classification of collateral circulation in patients with acute ischemic stroke, with a possible correlation with the clinical outcome.

**Materials and methods:** The basal angiograms of 57 patients with acute ischemic stroke is the territory of anterior circulation secondary to a major occlusion, who underwent endovascular treatment, were retrospectively reviewed and collaterals were classified according to our novel Careggi Collateral Score in 6 grades (0-6). The clinical outcome after 3 months was evaluated with modified Rankin Scale. A ROC (receiver operating characteristic) curve analysis identified a cut-off value of 1.

**Results:** Patients with favorable collateral circulation (grades 2-5) showed a significant correlation with good clinical outcome (modified Rankin Scale  $\leq 2$ ).

**Conclusions:** The Careggi Collateral Score resulted a useful tool to evaluate the chance of obtaining a favorable result with endovascular treatment in patients with acute ischemic stroke in the anterior circulation secondary to the occlusion of a major artery.

### Key words

Cerebral blood flow, computerized tomography, digital subtraction angiography, ischemic penumbra, leptomeningeal anastomoses, reperfusion

### Key to abbreviations:

ACA: anterior cerebral artery

ASITN: American Society of Interventional and Therapeutic Neuroradiology

ASPECT: Alberta Stroke program early CT score

CBF: cerebral blood flow

\* Corresponding author. E-mail: onemed21@gmail.com.

CBV: cerebral blood volume  
CCS: Careggi collateral score  
CT: computerized tomography  
DSA: digital subtraction angiography  
ICA: internal carotid artery  
MCA: middle cerebral artery  
MTT: mean transit time  
NECT: not-enhanced computed tomography  
NIHSS: National Institutes of Health Stroke Scale  
NINDS: National Institute of Neurological Disorders and Stroke  
rt-PA: recombinant tissue plasminogen activator

## Introduction

### The "Theory of the microcirculation" for ischemic stroke

An excessive reduction of cerebral blood flow causes the inactivation of the Na/K pump, with consequent irreversible damage of the cell membrane and cell death. Two different sub-areas may be recognized within the ischemic area: a central one, the ischemic core where the neural population is irreversibly damaged, and a peripheral one, the ischemic penumbra where oxygen and glucose supplies and controlled ion exchanges are maintained thanks to a blood flux of at least 12 ml/mg/min and the membrane of neural cells is still intact. Ischemic penumbra is considered to depend on a sequence of time-related microvascular events. The rationale to evaluate these processes with computerized tomography (CT)-perfusion scan in the acute phase of ischemic stroke is to document the time-related modifications of the three main basic parameters: velocity of the intravascular progression of the contrast agent (represented by the mean transit time), cerebral blood flow and cerebral blood volume (respectively, MTT, CBF and CBV). In the early phases after the arterial occlusion, during the development of ischemic penumbra, both MTT and CBV are increased and CBF is reduced. Subsequently, when the conversion from ischemic penumbra to ischemic core occurs, CBF and CBV rapidly decrease contrarily to MTT (Leiva-Salinas *et al.*, 2011). The explanation of these modifications should consider the hemodynamic events of the cerebral microcirculation. Indeed, during the early phases a progressive microvascular vasodilation is observed (Horiuchi *et al.*, 2002; Toda *et al.*, 2009) that may justify the increased CBV and CBF within the capillaries. This process is followed by a reduction in blood flow through the microcirculation secondary to thrombosis of the venular capillaries in the ischemic territory, corresponding to the decrease in CBF and CBV. Several researches in animal models have documented a progressive obliteration of the capillary circulation secondary to the fibrin deposition and consequent thrombosis (Obrenovitch *et al.*, 1985; Jafar *et al.*, 1989; Naganuma, 1990; del Zoppo *et al.*, 1991, 1993; Okada *et al.*, 1994; Okumura *et al.*, 1997; Hamann *et al.*, 2003; Adhami *et al.*, 2006; Zhang *et al.*, 2012). Furthermore, a recent study reported a similar *in vivo* experience in human patients during craniectomy after acute ischemic stroke (Pérez-Bárcena *et al.*, 2011).

The physiopathological mechanism that leads to thrombosis in the microcirculation seems to be secondary to the prolonged reduction in the blood flow within the ischemic area causing an endothelial alteration with local dysregulation of haemostasis (Zeller et al., 1999). Therefore, a local extended procoagulant reaction occurs leading to platelet adhesion to endothelium, slowdown of capillary blood flow and progressive thrombosis (Yan et al., 1999; Zeller et al., 1999; Zhang et al., 1999, 2000, 2001; Yan et al., 2000; del Zoppo, 2008). Therefore, the collateral circulation may represent the anatomical vascular basis of the residual perfusion of an ischemic area and may influence the extension and the reversibility of the ischemic penumbra, since the conservation of the patency of the microcirculation distally to the site of occlusion is guaranteed only by the integrity and extension of the collateral circulation. It would be possible, basing on these assumptions, to speculate about a correlation between the cerebral hypoperfusion and the extension and efficacy of the collateral circulation.

The aim of this paper is to discuss the correlation between the hemodynamic events occurring within the microcirculation and the visualization of collaterals supplying the cerebral territories in cases of major occlusion of the middle communicating artery (MCA) or internal carotid artery (ICA), to test whether thrombosis in the microcirculation may lead to secondary modifications of the pial collateral circulation within the ischemic territory. These processes would influence the possibility to achieve a useful reperfusion once the recanalization of the previously occluded artery is obtained.

#### Leptomeningeal anastomoses

The cortico-cortical (leptomeningeal) anastomoses provide the residual perfusion of cerebral areas affected by the thromboembolism of a cerebral artery of the anterior circulation. In case of MCA occlusion, blood is supplied through the anterior cerebral artery (ACA) with retrograde filling of leptomeningeal collaterals to the MCA territory from the top to basal areas (Brozici et al., 2003; Liebeskind, 2003). The efficacy of the retrograde collateral circulation can be evaluated by quantitative (extension of the reperfusion in the ACA-MCA territories) and qualitative parameters (velocity of the blood flow within collaterals, stagnation of contrast agent within collaterals secondary to blood stasis). Since the level of occlusion remains stable during the first hours of ischemic stroke if recanalization is not achieved, the mechanisms underlying the progression of the ischemic area may be blood stasis and consequent thrombosis of microcirculation rather than modification in the degree of occlusion. Thrombosis in the microcirculation is a time-dependent phenomenon and reaches a peak a few hours after the occlusion. Therefore, the blood stasis observed within the collateral circulation should be considered secondary to progressive reduction of the pressure gradient from the periphery (cortex) to the depth of brain parenchyma, leading to slowing down of the microcirculation and consequent progressive thrombosis. Therefore, the recanalization of the occluded artery would not lead to the reperfusion of the capillary network and re-occlusion would progressively occur as if there were a loss of blood "aspiration" downstream (the "no reflow phenomenon"; del Zoppo et al., 2003).

On these assumptions about hemodynamics we propose an angiographic qualitative-quantitative score to evaluate: (1) the extension of the reperfused areas in the representation of the cortical ACA-MCA territories as evaluated in antero-posterior projec-

tion and (2) the presence of “regressive” signs, such as the “suspended artery sign” (i.e. the presence of interrupted and isolated arterial segments with endoluminal stagnation of contrast agent even in late venous phases due to slow blood flow and consequent stasis within collaterals, observed in late phases of angiography in lateral projection).

#### Other angiographic scales reported in the literature

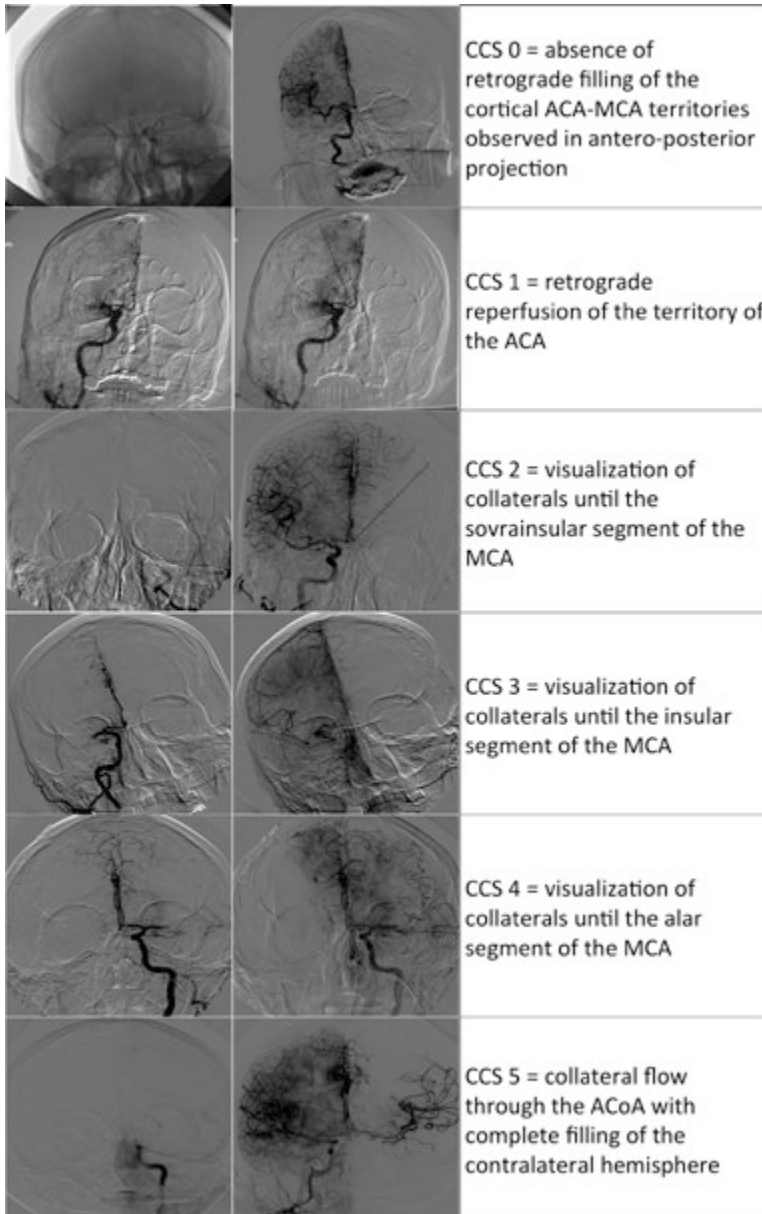
A recent systematic review (McVerry *et al.*, 2012) collected 41 different classifications for the angiographic assessment of cerebral collateral circulation and only 19 of them were proposed for acute ischemic stroke. Four classifications (Qureshi, 2002; Higashida *et al.*, 2003; Kim *et al.*, 2004; Christoforidis *et al.*, 2005) were comparable with ours since they are based on a system with more than 3 levels, while a basic dichotomization (good/poor) (Bozzao *et al.*, 1989; von Kummer *et al.*, 1995; Kucinski *et al.*, 2003) or more general features were used for the other ones (von Kummer *et al.*, 1992; Roberts *et al.*, 2002; Gasparotti *et al.*, 2009; Rai *et al.*, 2011). The Qureshi score (Qureshi, 2002) considers 6 grades of vascular occlusion (from 0 to 5) based on the involved vessels. Collateral perfusion was considered in grade 3 (M1 occlusion) and grade 4 (ICA or basilar artery occlusion) with two dichotomous subtypes: anterograde or retrograde filling (only in posterior circulation) and filling of the ACA or MCA territory (only in anterior circulation). The American Society of Interventional and Therapeutic Neuroradiology (ASITN) classification (Higashida *et al.*, 2003) considers 5 grades of retrograde reperfusion, from 0, no reperfusion, to 4, complete rapid reperfusion. In this case grades 1 and 2 are characterized by partial reperfusion (grade 1 with slow collateral reperfusion, grade 2 with quick reperfusion), while grades 3 and 4 indicate complete reperfusion (grade 3 with slow collateral reperfusion, grade 4 with quick reperfusion). The number of frames necessary to take until complete filling of the circulation, provided that the number of frames per second is known, defines the temporal concept of “slow” and “rapid” collateral reperfusion. Christoforidis *et al.* (2005) described 5 grades of retrograde reperfusion in relation with the occlusion site, considering the position of the last reperfused arterial segment, i.e. that closest to the arterial stop (1: reperfusion until the segment closest to the arterial occlusion; 5: reperfusion until segments distal to occlusion). However, no qualitative assessment was provided. Finally, Kim *et al.* (2004) proposed a collateral assessment in patients with MCA occlusions with a 45-points scoring system where increasing collateral flow is scored from 0 to 3 for each of 15 different areas based on Alberta Stroke program early CT score (ASPECT) model (Barber *et al.*, 2000), allowing for a significantly accurate prediction of the final extent of ischemic lesions.

## Materials and Methods

### The Careggi Collateral Score (CCS)

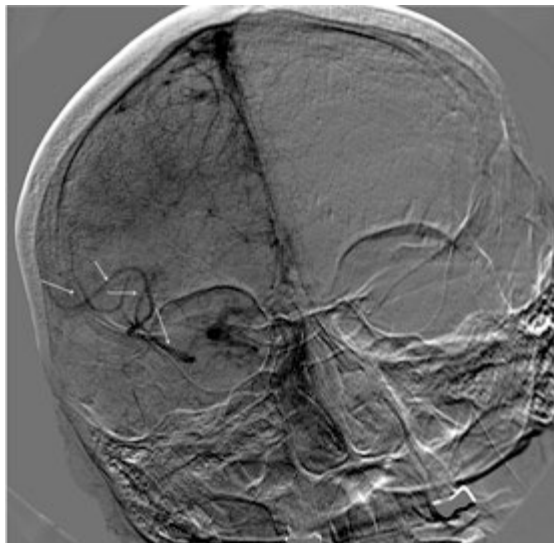
The angiographic assessment of leptomeningeal collaterals in acute ischemic stroke should be performed through a complete study of both anterior and posterior circulation, in antero-posterior and lateral projections, injecting contrast agent into both internal carotid arteries and at least one vertebral artery.

The CCS is subdivided in 6 grades (quantitative evaluation, fig. 1) depending on the extension of the retrograde reperfusion in the cortical ACA-MCA territories observed in antero-posterior projection: grades from 0 to 4 indicate respectively the

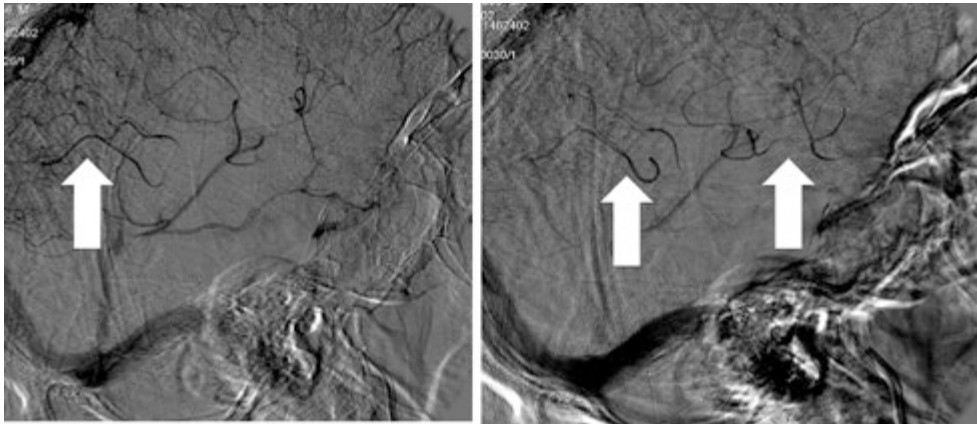


**Figure 1** – The Careggi Collateral

absence of retrograde filling (grade 0), a retrograde reperfusion of the territory of the ACA (grade 1), and the visualization of collaterals until the sovrainsular (grade 2), insular (recognizable because of the “insular S” sign; grade 3, fig. 2) and “alar” segment of the MCA (so called because of the overlap with the ala magna of the sphenoidal bone, grade 4) or M1 segment. Grade 5 is considered only in acute ICA occlusions and occurs when, injecting the contralateral carotid artery, a collateral flow is observed through the ACA with complete filling of the contralateral hemisphere. In case of associated occlusion of the ICA and of the omolateral MCA the CCS should be evaluated using the same scale upon injecting the contralateral ICA. Prolonged injections should be performed in order to evaluate blood stasis within collaterals, visualized in lateral projection during late phases (A: without suspended artery sign; B: with suspended artery sign; fig. 3). The final score (“pure” CCS) is calculated subtracting one point to the initial grade if suspended arteries are visualized in lateral projections, e.g.: initial CCS 3B plus suspended artery: pure CCS = 2. Since collaterals are filled by retrograde flow in the MCA territory through ACA cortical anastomoses, the conditions determining the occlusion of the ACA such as carotid T-siphon limit the possibility of observing a leptomeningeal reperfusion. Furthermore, the occlusion of only one of the two bifurcation branches of the MCA or distal cortical emboli may affect the angiographic assessment of the collateral circulation since it may make difficult to evaluate the effective role of leptomeningeal anastomoses in determining the cerebral reperfusion. For these reasons, in cases of M1 or ICA occlusion we recommend the use of this score only in selected patients; the criteria of exclusion are given in Table 1. The CCS is based on the extension of the reperfused territory and the presence of “regressive” signs of the collateral circulation, independently from the site



**Figure 2** – The “insular S” sign: retrograde leptomeningeal collaterals visible until the insular region, drawing an S (red arrows).



**Figure 3** – Late venous phase of lateral projection upon injecting the internal carotid artery showing the contrast stagnation within segments of cortical arteries secondary to the thrombosis in the microcirculation (the “suspended artery” sign)

**Table 1**

Criteria of exclusion
Posterior circulation strokes
Iatrogenic strokes
Incomplete angiograms (absence of early venous phases)
Incomplete study (in case of internal carotid artery occlusion, absence of angiographic series injecting the contralateral one)
Incomplete occlusions (isolated M2 branches, subocclusive stenosis)

of occlusion, and provides a qualitative-quantitative analysis (pure CCS) to describe both the extension and effectiveness of the collateral circulation.

#### Anatomo-clinical correlations

The CCS was retrospectively applied in a cohort of 57 patients (28 males, 29 females, mean age 66,5 , standard deviation 14,9 years) admitted at our institution with a cerebral ischemic stroke and documented occlusion of the anterior circulation at the level of the MCA (M1 and/or M1-M2 segments) or the ICA with or without involvement of the ACA. Age, gender and National Institutes of Health Stroke Scale (NIHSS; Brott et al., 1989) were evaluated at admission and all the patients underwent a non-enhanced head CT scan to exclude a haemorrhagic stroke and National Institutes of Health Stroke Scale (ASPECT) score was used to evaluate early ischemic signs. Eleven patients received i.v. fibrinolysis (rt-PA) considering the National Institute of Neurological Disorders and Stroke (NINDS Study Group, 1995) criteria. If a major neurological improvement (reduction of at least 4 points of NIHSS) was not observed, the patients were referred to our Interventional Neuroradiology Unit for endovascular treatment.

All patients underwent a digital subtraction angiography (DSA) for the detection of the occlusion site and the assessment of leptomeningeal collateral circulation using the "pure" CCS. The aim of this study was to evaluate the correlation between the CCS and the clinical picture of all patients at admission evaluated with NIHSS. A statistical analysis was performed with  $\chi^2$  test and Spearman's rank correlation coefficient ( $\rho$ ) and its 95% confidence interval; p value was considered statistically significant if  $\leq 0,05$ ; negative values of Spearman's Rho coefficient indicate an inverse correlation.

## Results and discussion

In our cohort the mean NIHSS value was  $20 \pm 6$  and the mean ASPECT score assessed with NECT at admission was  $8 \pm 1,7$ . Twenty-one patients (36,8%) had an ICA occlusion (of the carotid siphon) with involvement of M1 segment or the ACA; in one case (1,8%) the ICA was occluded in the extracranial segment and in the other 35 cases (61,4%) the occlusion was at the level of the MCA (M1, M1-M2) associated or not with occlusion of the ACA (M1+A1). The subdivision of patients on the basis of CCS was as follows: CCS 0, 9 patients (15,7%); CCS 1, in 3 patients (5,3%); CCS 2, 29 patients (50,9 %); CCS 3, 11 patients (19,3%); CCS 4, 4 patients (7%); and CCS 5, one patient (1,8%). A cut-off value (CCS=1) was identified with a ROC curve analysis. The CCS resulted significantly inversely correlated with NIHSS at admission ( $p < 0,001$ , Spearman's Rho coefficient  $-0,528$ ), indicating that an effective collateral circulation may reduce the clinical manifestation of acute ischemic stroke at admission and that this effectiveness can be measured. However, further studies of correlation with clinical outcome after the endovascular procedures should be performed.

## Conclusion

The pial collateral circulation should be considered not only to explain the severity of the clinical condition in acute ischemic stroke but also to evaluate the chance to achieve a successful endovascular treatment in the anterior circulation.

In comparison with the previously published grading systems, the CCS may be interpreted immediately since it is based on the extension of the reperfused territory and on the presence of "regressive" signs of the collateral circulation independently from the site of occlusion. Furthermore, this grading system provides a qualitative-quantitative analysis (pure CCS) to describe both the extension and effectiveness of the collateral circulation, which are relevant to plan effective therapy.

## References

- Adhami F., Liao G., Morozov Y. M., Schloemer A., Schmithorst V. J., Lorenz J. N., Dunn R. S. (2006) Cerebral ischemia-hypoxia induces intravascular coagulation and autophagy. *Am. J. Pathol.* 169: 566–583.
- Barber P. A., Demchuk A. M., Zhang J., Buchan A. M. (2000) Validity and reliability of a quantitative computed tomography score in predicting outcome of hyperacute



- stroke before thrombolytic therapy. ASPECTS Study Group. Alberta Stroke Programme Early CT Score. *Lancet* 355: 1670–1674.
- Bozzao L., Fantozzi L. M., Bastianello S., Bozzao A., Fieschi, C. (1989) Early collateral blood supply and late parenchymal brain damage in patients with middle cerebral artery occlusion. *Stroke* 20: 735–740.
- Brott T., Adams H. P., Olinger C. P., Marler J. R., Barsan W. G., Biller J., Spilker J. (1989) Measurements of acute cerebral infarction: a clinical examination scale. *Stroke* 20: 864–870.
- Brozici M., van der Zwan A., Hillen B. (2003) Anatomy and functionality of leptomeningeal anastomoses: a review. *Stroke* 34: 2750–2762.
- Christoforidis G., Mohammad Y., Kehagias D., Avutu B., Slivka A. P. (2005) Angiographic assessment of pial collaterals as a prognostic indicator following intra-arterial thrombolysis for acute ischemic stroke. *AJNR Am. J. Neuroradiol.* 26: 1789–1797.
- del Zoppo G. J. (2008) Virchow's triad: the vascular basis of cerebral injury. *Rev. Neurol. Dis.* 5 (Suppl 1): S12–21.
- del Zoppo G. J., Mabuchi T. (2003) Cerebral microvessel responses to focal ischemia. *J. Cereb. Blood Flow Metab.* 23: 879–894.
- del Zoppo G. J., Schmid-Schönbein G. W., Mori E., Copeland B. R., Chang C. M. (1991) Polymorphonuclear leukocytes occlude capillaries following middle cerebral artery occlusion and reperfusion in baboons. *Stroke* 22: 1276–1283.
- Gasparotti R., Grassi M., Mardighian D., Frigerio M., Pavia M., Liserre R., Magoni M. et al. (2009) Perfusion CT in patients with acute ischemic stroke treated with intra-arterial thrombolysis: predictive value of infarct core size on clinical outcome. *AJNR Am. J. Neuroradiol.* 30: 722–727.
- Hamann G. F., Schröck H., Burggraf D., Wunderlich N., Liebetau M., Kuschinsky W. (2003) Microvascular Basal lamina damage after embolic stroke in the rat: relationship to cerebral blood flow. *J. Cereb. Blood Flow Metab.* 23: 1293–1297.
- Higashida R. T., Furlan A. J., Roberts H., Tomsick T., Connors B., Barr J., Dillon W. et al. (2003) Trial design and reporting standards for intra-arterial cerebral thrombolysis for acute ischemic stroke. *Stroke* 34: e109–137.
- Horiuchi T., Dietrich H. H., Hongo K., Goto T., Dacey R. G. (2002) Role of endothelial nitric oxide and smooth muscle potassium channels in cerebral arteriolar dilation in response to acidosis. *Stroke* 33: 844–849.
- Jafar J. J., Menoni R., Feinberg H., LeBreton G., Crowell R. M. (1989) Selective platelet deposition during focal cerebral ischemia in cats. *Stroke* 20: 664–667.
- Kim J. J., Fischbein N. J., Lu Y., Pham D., Dillon W. P. (2004) Regional angiographic grading system for collateral flow: correlation with cerebral infarction in patients with middle cerebral artery occlusion. *Stroke* 35: 1340–1344.
- Kucinski T., Koch C., Eckert B., Becker V., Krömer H., Heesen C., Grzyska U. et al. (2003) Collateral circulation is an independent radiological predictor of outcome after thrombolysis in acute ischaemic stroke. *Neuroradiology* 45: 11–18.
- Leiva-Salinas C., Wintermark M., Kidwell C. S. (2011) Neuroimaging of cerebral ischemia and infarction. *Neurotherapeutics* 8: 19–27.
- Liebesskind D. S. (2003) Collateral circulation. *Stroke* 34: 2279–2284.
- McVerry F., Liebesskind D. S., Muir K. W. (2012) Systematic review of methods for assessing leptomeningeal collateral flow. *AJNR Am. J. Neuroradiol.* 33: 576–582.

- Naganuma Y. (1990) Changes of the cerebral microvascular structure and endothelium during the course of permanent ischemia. *Keio J. Med.* 39: 26–31.
- NINDS Study Group. (1995) Tissue plasminogen activator for acute ischemic stroke. The National Institute of Neurological Disorders and Stroke rt-PA Stroke Study Group. *N. Engl. J. Med.* 333: 1581–1587.
- Obrenovitch T. P., Hallenbeck J. M. (1985) Platelet accumulation in regions of low blood flow during the postischemic period. *Stroke* 16: 224–234.
- Okada Y., Copeland B. R., Fitrige R., Koziol J. A., del Zoppo G. J. (1994) Fibrin contributes to microvascular obstructions and parenchymal changes during early focal cerebral ischemia and reperfusion. *Stroke* 25: 1847–1853; discussion 1853–1814.
- Okumura Y., Sakaki T., Hiramatsu K., Tominaga M., Yabuno T. (1997) Microvascular changes associated with postischemic hypoperfusion in rats. *Acta Neurochir.* 139: 670–676; discussion 676–677.
- Pérez-Bárcena J., Goedhart P., Ibáñez J., Brell M., García R., Llinás P., Jiménez C. et al. (2011) Direct observation of human microcirculation during decompressive craniectomy after stroke. *Crit. Care Med.* 39: 1126–1129.
- Qureshi A. I. (2002) New grading system for angiographic evaluation of arterial occlusions and recanalization response to intra-arterial thrombolysis in acute ischemic stroke. *Neurosurgery* 50: 1405–1414; discussion 1414–1415.
- Rai A. T., Jhadhav Y., Domico J., Hobbs G. R. (2011) Procedural predictors of outcome in patients undergoing endovascular therapy for acute ischemic stroke. *Cardiovasc. Intervent. Radiol.* 35: 1332–1339.
- Roberts H. C., Dillon W. P., Furlan A. J., Wechsler L. R., Rowley H. A., Fischbein N. J., Higashida R. T. et al. (2002) Computed tomographic findings in patients undergoing intra-arterial thrombolysis for acute ischemic stroke due to middle cerebral artery occlusion: results from the PROACT II trial. *Stroke* 33: 1557–1565.
- Toda N., Ayajiki K., Okamura T. (2009) Cerebral blood flow regulation by nitric oxide: recent advances. *Pharmacol. Rev.* 61: 62–97.
- von Kummer R., Hacke W. (1992) Safety and efficacy of intravenous tissue plasminogen activator and heparin in acute middle cerebral artery stroke. *Stroke* 23: 646–652.
- von Kummer R., Holle R., Rosin L., Forsting M., Hacke W. (1995) Does arterial recanalization improve outcome in carotid territory stroke? *Stroke* 26: 581–587.
- Yan S. F., Mackman N., Kisiel W., Stern D. M., Pinsky D. J. (1999) Hypoxia/hypoxemia-induced activation of the procoagulant pathways and the pathogenesis of ischemia-associated thrombosis. *Arterioscler. Thromb. Vasc. Biol.* 19: 2029–2035.
- Yan S. F., Pinsky D. J., Stern D. M. (2000) A pathway leading to hypoxia-induced vascular fibrin deposition. *Semin. Thromb. Hemost.* 26: 479–483.
- Zeller J. A., Tschoepe D., Kessler C. (1999) Circulating platelets show increased activation in patients with acute cerebral ischemia. *Thromb. Haemost.* 81: 373–377.
- Zhang J., Tan Z., Tran N. D. (2000) Chemical hypoxia-ischemia induces apoptosis in cerebrovascular endothelial cells. *Brain Res.* 877: 134–140.
- Zhang Y., Fan S., Yao Y., Ding J., Wang Y., Zhao Z., Liao L. et al. (2012) In vivo near-infrared imaging of fibrin deposition in thromboembolic stroke in mice. *PloS One* 7: e30262.
- Zhang Z. G., Chopp M., Goussev A., Lu D., Morris D., Tsang W., Powers C., Ho K.L. (1999) Cerebral microvascular obstruction by fibrin is associated with upregula-

tion of PAI-1 acutely after onset of focal embolic ischemia in rats. *J. Neurosci.* 19: 10898–10907.

Zhang Z. G., Zhang L., Tsang W., Goussev A., Powers C., Ho K. L., Morris D., Smyth S.S., Coller B.S., Chopp M. (2001) Dynamic platelet accumulation at the site of the occluded middle cerebral artery and in downstream microvessels is associated with loss of microvascular integrity after embolic middle cerebral artery occlusion. *Brain Res.* 912: 181–194.