

Original research article

# Anatomical and Congenital Variations of Styloid Process of Temporal Bone in Indian Adult Dry Skull Bones

Kalyan Chakravarthi Kosuri<sup>1,\*</sup>, Venumadhav Nelluri<sup>2</sup>, Siddaraju KS<sup>3</sup>

<sup>1</sup> Associate Professor, Department of Anatomy, Varun Arjun Medical College, Banthra-Shajahanpur - 242307, Uttar Pradesh, India

<sup>2</sup> Assistant professor, Department of Anatomy, Melaka Manipal Medical College (MMMC), Manipal University, Manipal, and Karnataka, India

<sup>3</sup> Lecturer, Department of Anatomy, KMCT Medical College, Manassery, Calicut, Kerala, India

## Abstract

**Background:** Styloid process of temporal bone is clinically significant, because of anatomical or congenital variations in length, number, angulations as well as close proximity to many of the vital neurovascular structures in the neck. Abnormal or congenital variations of the styloid process may compress adjacent neurovascular structures and leads to symptoms of sty-lalgia (Eagle's syndrome). **Aim:** Accordingly this study was aimed to evaluate the anatomical and congenital variations of styloid process of temporal bone in Indian adult dry skull bones. **Materials and Methods:** This study was carried out on 110 dry human skulls irrespective of age and sex at Varun Arjun medical college- Banthra,-UP, Melaka Manipal Medical College- Manipal and KMCT Medical College, Manassery- Calicut. All the skulls were macroscopically inspected for the anatomical and congenital variations of styloid process of temporal bone. Photographs of the anatomical and congenital variations were taken for proper documentation. **Results:** Out of 110 dry human skull bones we noted very rare unusual unilateral triple styloid processes in one skull bone, unusual bilateral double styloid processes in one skull bone and unilateral double styloid processes in right side of one skull bone. **Conclusion:** Congenital double, triple and elongated styloid process noted in this study can leads to styloidogenic jugular compression syndrome or stylo-carotid artery syndrome or disturb the biomechanics of temporomandibular joint or compress/ irritate nearby neurological structures trigger a series of symptoms such as dysphagia, odynophagia, facial pain, ear pain, headache, tinnitus and trismus. Proper knowledge and diagnosis of anatomical and congenital variations of styloid process of temporal bone is important to anaesthetists, dentists, neurosurgeons and otolaryngologists, orthopaedic surgeons, clinical anatomist, Radiologists, forensic experts Architects and morphologists which may increase the success of diagnostic evaluation and surgical approaches to the region.

## Keywords

Bell's palsy, dysphagia, odynophagia, Eagle's syndrome, facia colli, Reichert's cartilage, vascular Eagle's Syndrome.

\* Corresponding author. E-mail: kalyankosuric@gmail.com

## Introduction

Styloid process of temporal bone is a slender bony projection from the inferior surface of the temporal bone, averaging from 2 to 2.5 cm in length when it exceeds the 4 cm length it is assigned the term elongation is considered an anomaly. The elongation of styloid process was first described in 1652 by Italian surgeon Pietro Marchetti. Embryologically it developed from the second pharyngeal/brachial arch called as the Reichert's cartilage because it is of cartilaginous origin. The styloid process provides attachments of two ligaments stylohyoid and stylomandibular ligaments and three muscles stylopharyngeus, stylohyoid and styloglossus muscles. Many important neurovascular structures are presented adjacent to the styloid process.

Styloid process laterally covered by parotid gland, facial nerve crosses its base, external carotid artery crosses its tip and medially, it is separated from beginning of internal jugular vein by stylopharyngeus. Lateral to the stylomastoid foramen, tympanomastoid suture lies which accommodates auricular branch of vagus nerve. Internal carotid artery, internal jugular vein and, vagus, spinal accessory and hypoglossal cranial nerves lie on its medial side. In close proximity is the glossopharyngeal nerve laying in the posterolateral wall of tonsillar fossa (Patil S et al., 2014). Styloid process is usually extends downwards, due to anatomical and congenital variations in length or number and angulations may compress adjacent neurovascular structures.

Stylomastoid foramen intervenes between styloid and mastoid processes; the foramen transmits facial nerve and stylomastoid artery. Any abnormal or congenital variations of styloid process or ossified ligamentous structures around area of stylomastoid foramen may partially or completely compress the facial nerve and leads to Bell's palsy is a condition that causes weakness or paralysis of the muscles in the face. Considering the various relations of styloid process with important neurovascular structures and its morphological variations, this study was aimed to evaluate the anatomical and congenital variations of styloid process in Indian dry adult skulls.

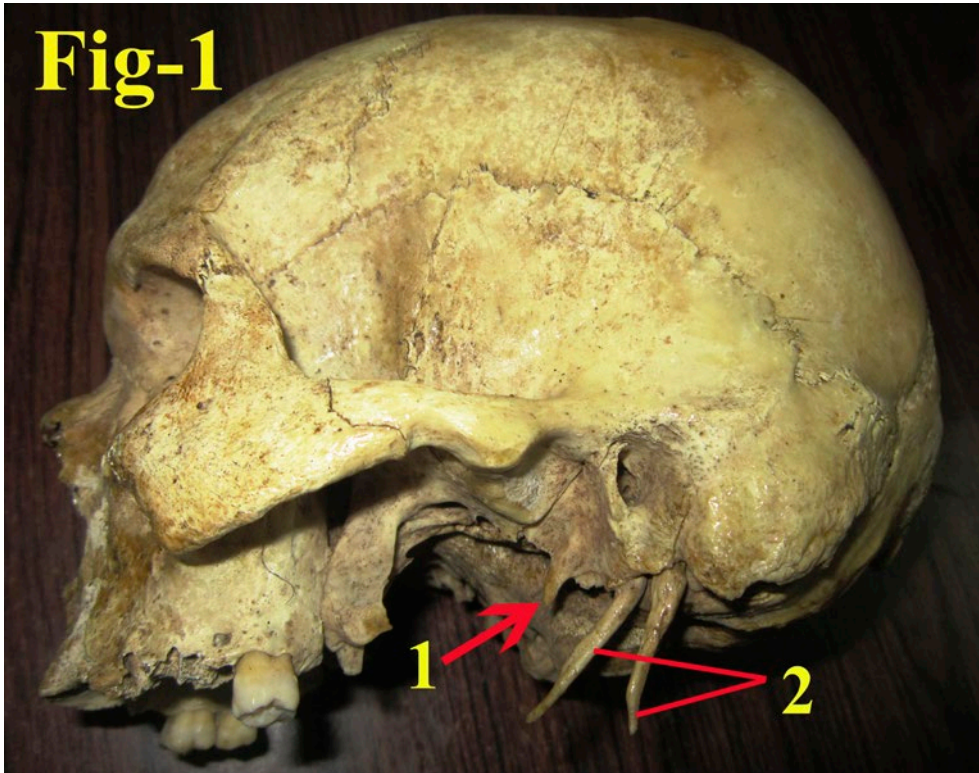
## Materials and Methods

This study was carried out on 110 dry human adult skulls irrespective of age and sex at Varun Arjun medical college- Banthra,-UP, Melaka Manipal Medical College-Manipal and KMCT Medical College Manassery- Calicut. All the skulls were macroscopically inspected for the anatomical and congenital variations of styloid process of temporal bone. Photographs of the anatomical and congenital variations were taken for proper documentation.

## Results

Out of 110 dry human skulls bones the following anatomical and congenital variations of styloid process of temporal bone were noted-

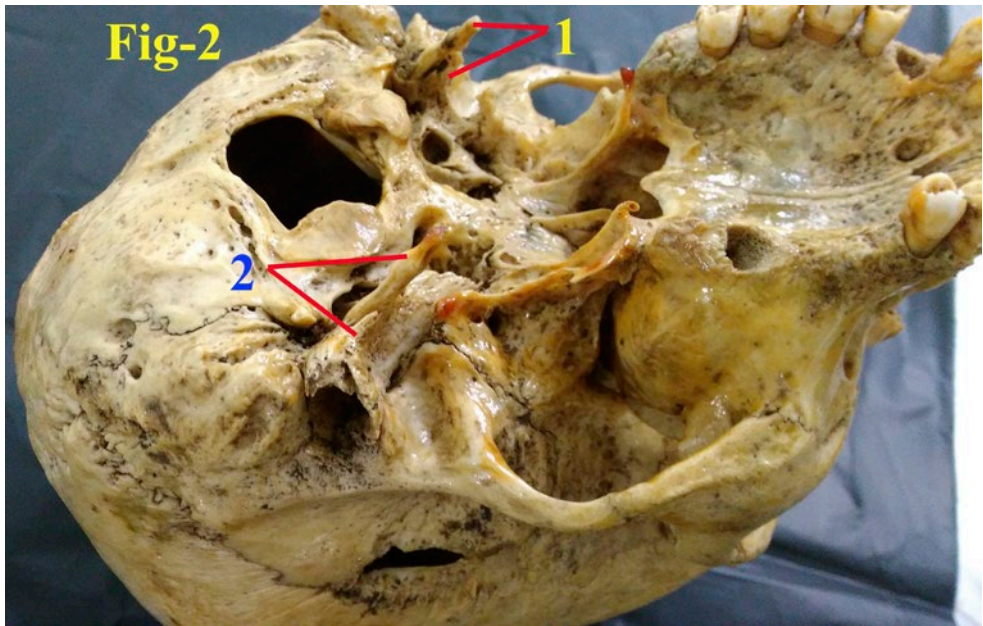
- **CASE-I:** Very rare unusual unilateral triple styloid processes were noted in left side of one skull bone. In which one styloid process with a length of 2.4cm projected from the anterior surface (non articular part of mandibular fossa) and lower



**Figure 1.** Left lateral view of skull showing unilateral Triple styloid processes. 1- Styloid process (bony projection) projected from the anterior surface (non articular part of mandibular fossa) and lower border of tympanic part of temporal bone; 2- Elongated double styloid processes.

border of tympanic part of temporal bone and another two styloid processes were elongated (each 7.3cm length) and projected from the inferior surface of the temporal bone. (Fig. 1)

- **CASE-II:** Unusual bilateral double styloid processes were noted in one skull bone. In which one styloid process with a length of 2.8 cm each projected from the anterior surface and lower border of tympanic part of respective temporal bone (non articular part of mandibular fossa) and another one styloid processes was elongated with a length of each 6.8 cm each projected from the inferior surface of the respective temporal bone. (Fig. 2)
- **CASE-III:** Unilateral double styloid processes were noted in right side of one skull bone. Double styloid processes were elongated and projected from the inferior surface of the temporal bone. In which one styloid process with a length of 5.9 cm extended downwards and forwards and another styloid process is slender and sharp with a length of 5 cm extended backwards. (Fig. 3)
- The length of styloid process (distance between base and tip of the styloid process) were measured with the help of digital vernier calipers.

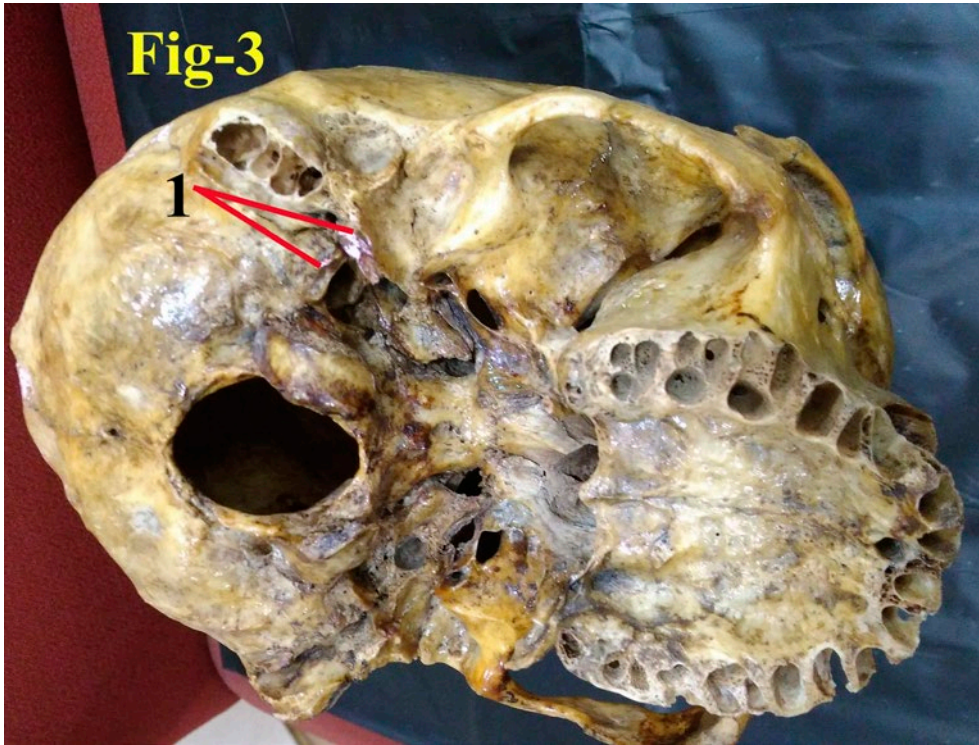


**Figure 2.** Basal view of skull showing bilateral double styloid processes. 1. Right side- double styloid processes; 2. Left side- double styloid processes.

## Discussion

Stylohyoid chain includes the styloid process, stylohyoid ligament, and the lesser horn of the hyoid bone which develops from the Reichert cartilage of the second brachial arch. Anatomical or congenital variation in the length/number of the styloid process and its stylohyoid chain or abnormal ossification of stylohyoid chain components is said to have profound anatomical, anthropological as well as of clinical importance. Such abnormalities may compress or irritate nearby neurovascular structures trigger a series of symptoms such as dysphagia, odynophagia, facial pain, ear pain, headache, tinnitus and trismus. This set of symptoms associated with the elongated styloid process is called Eagle's syndrome was first described by Watt W. Eagle in the year 1937 (Kim E et al., 2008). Two types of Eagle syndrome have been described the first type includes cervicofacial pain aggravated by swallowing and the sensation of a foreign body in the throat after tonsillectomy. The second type is the "stylo-carotid artery syndrome", and is attributed to impingement of the internal carotid arteries, extra cranially by the styloid process this can cause compression when turning the head, resulting in a transient ischemic accident or stroke (Chuang WC et al., 2007; Eagle WW, 1949; Farhat HI et al., 2009).

Dashti SR et al reported symptomatic jugular vein obstruction in association with Eagle syndrome (styloidogenic jugular compression syndrome). He reported two bilateral novel cases presenting with symptoms of increased central venous pressure related to jugular venous outflow obstruction caused by osseous impingement of the



**Figure 3.** Basal view of skull showing unilateral double styloid processes. 1. Right side- double styloid processes.

jugular veins between the transverse process of atlas and a prominent, posteriorly located styloid process. In such cases patients may experience symptomatic central venous hypertension and may be predisposed to venous stasis and cerebral venous sinus thrombosis (Dashti SR et al., 2012). In the present study we noted elongated double styloid process in which one styloid process extended downwards and forwards and another styloid process is slender with sharp edges extended backwards (CASE-III). Such congenital double elongated styloid process may lead to stylo-jugular compression syndrome or stylo-carotid artery syndrome. The knowledge of the congenital double elongated styloid process and the structures related to it noted in this study can help in proper diagnosis and treatment of eagle's syndrome.

Normal range of the length of the styloid process differs among the studies in the literature. Eagle reported the normal length of styloid process as 2.5 cm; other authors measured the length as 3 cm. It has been reported that it is probably symptomatic when the length exceeds 4cm (Monsour P A, Young W G. 1986). Massey et al reported 11 cases of styloid process having length of more than 4 cm out of 2000 cases studied (Massey EW, 1978). Harma et al reported 4 -7% for elongated styloid process (Harma R. Styloalgia, 1966). Cawich et al presented post mortem study elonga-

tion was seen four times more in males than females and in 75% of cases the elongation was bilateral (Cawich SO et al., 2009). Prabhu et al reported a case of bilateral elongated styloid process with the length of 60 and 59 mm on the right and left side, respectively (Prabhu LV et al., 2007). Paraskevas et al presented a case of the dried skull with an elongated right styloid process with a length of 58 mm (Paraskevas G K et al., 2009). Ishwar et al reported a bilaterally elongated styloid process in dried skull measuring 60 mm (Ishwar B et al., 2013). The elongation of styloid process is which can be accompanied by calcification of the stylohyoid and stylomandibular ligaments, Guarna M et al reported abnormally elongated styloid process (70 mm on the left side) was due to ossification of the stylohyoid ligament (Guarna M and Agliano M, 2018). Sanjeev I K et al reported elongated styloid process of 8 cm length in which styloid process proper was 5 cm long and remaining 3 cm was ossified stylohyoid ligament (Sanjeev Irranna Kolagi et al., 2010). In another case, he reported on left side of a male cadaver the styloid process was 6.3 cm long. Very rare and unusual unilateral triple styloid process noted in our study (CASE-I), in which one styloid process projected from the anterior surface (non articular part of mandibular fossa) and lower border of tympanic part of temporal bone with a length of 2.4 cm, such congenital variations may disturb the biomechanics of temporomandibular joint. The auriculotemporal nerve is branch from posterior division of mandibular nerve, it supplies cutaneous sensitivity from the auriculotemporal area, including roof and anterior wall of external acoustic meatus, tragus, anterior portion of the ear, skin of temple, cuticular layer of tympanic membrane, articular branch to temporo-mandibular joint, and also carries parasympathetic fibres to the parotid gland. The auriculotemporal nerve arises as two roots unite to form a trunk passes between the neck of the mandible and the sphenomandibular ligament and then turn superiorly, posterior to its condylar head. The auriculotemporal nerve can be damaged or compressed between anomalous styloid process (projecting from the anterior surface and lower border of tympanic plate (CASE-I)) and temporomandibular joint results in auriculotemporal neuralgia. And another two styloid processes were elongated and projected from the inferior surface of the temporal bone with a length of 7.3 cm each (CASE-I), surprisingly stylomastoid foramen intervenes between them such congenital variations may leads to compression of facial nerve and can results in symptoms of Bell's palsy. Unilateral triple styloid process noted in our study (CASE-I) may be due to errors of embryologic cleavage of Reichert cartilage of the second brachial arch during development. To the best of our knowledge, triple and double styloid processes observed in this study have not been cited in modern literature. Such multiple styloid processes presented in this study may create a diagnostic problem for the radiologist examining for foreign bodies or may compress neurovascular structures and can cause serious implications in any surgical intervention in the region, and may lead to false radiological or neurological differential diagnosis. So it is important that clinicians and radiologists should keep this entity in mind as it may increase the success of diagnostic evaluation and surgical approaches to the region.

Unusual bilateral double styloid process noted in our study (CASE-II), in which one styloid process projected from the anterior surface (non articular part of mandibular fossa) and lower boarder of tympanic part of respective temporal bone with a length of 2.8 cm each. Another styloid process was elongated and projected from the inferior surface of the respective temporal bone with a length of 6.8 cm each.

The deep cervical fascia or fascia colli invests the muscles of the neck and fills up the interval between muscles, vessels and cervical viscera. The deep cervical fascia generally described to possess three layers from outside inwards- investing, pretracheal and vertebral. When we see the vertical extent of investing fascia traced above at the lower pole of parotid gland, it splits superficial and deep layers (parotid fascia). The superficial layer is strong, passes superficial to the gland, is attached to the lower margin of zygomatic arch and blends with the epimysium of the masseter to form a strong parotid-masseteric fascia. The deep layer passes medial to the gland and is attached to the lower boarder of the tympanic plate and the styloid process of temporal bone. Here the deep layer is thickened to form stylomandibular ligament which extends from the tip of the styloid process to the angle of mandible. Anomalous styloid process projecting from the anterior surface and lower border of tympanic plate noted in our study may be the results of calcification and ossification of the deep layer of the parotid fascia attached to the lower boarder of the tympanic plate. Clinically the relation of tip of the stylohyoid process is important, course of it situated in between external and internal carotid arteries, anteriomedially it is related to facial nerve, medially with accessory and vagus nerves any pressure at the surrounding area of tonsillar fossa or manipulations around the neck area may lead to fracture of such double styloid process leading to many clinical signs. Knowledge of the existence of such congenital variation or elongated styloid process is important for dentist otolaryngologist, surgeon, and radiologist.

## **Conclusion**

We believe that the present study has provided some important data which will contribute to the scientific literature, providing the anatomical data of styloid process of temporal bone in the Indian adult dry skull bones. To the best of our knowledge, triple and double styloid processes observed in this study have not been cited in modern literature. Proper knowledge and diagnosis of anatomical and congenital variations of styloid process of temporal bone not only enlightening for the anaesthetists, dentists, neurosurgeons and otolaryngologists, orthopaedic surgeons, also vital for the clinical anatomist, Radiologists, Forensic experts Architectures and morphologists.

## **Funding**

None.

## **Conflict of interest**

None declared.

## **Ethical approval**

Not required.

## References

- Chuang WC, Short JH, McKinney AM, Anker L, Knoll B, McKinney ZJ. (2007) Reversible left hemispheric ischemia secondary to carotid compression in Eagle syndrome: Surgical and CT angiographic correlation. *AJNR Am J Neuroradiol* 28: 143- 145.
- Cawich SO, Gardner M, Shetty R, Harding HE. (2009) A post mortem study of elongated styloid Processes in a Jamaican population. *The Internet Journal of Biological Anthropology*. Volume 3: Number 1.
- Dashti SR, Nakaji P, Hu YC, Frei DF, Ablal AA, Yao T, Fiorella D. (2012) Styloidogenic jugular venous compression syndrome: Diagnosis and treatment. Case report. *Neurosurgery*. 70(3): E795-799.
- Eagle WW. (1949) Symptomatic elongated styloid process: Report of two cases of styloid process-carotid artery syndrome with operation. *Arch Otolaryngol*. 49: 490-503.
- Farhat HI, Elhammady MS, Ziayee H, Aziz-Sultan MA, Heros RC. (2009) Eagle syndrome as a cause of transient ischemic attacks. Case report. *J Neurosurg*. 110: 90-93.
- Guarna M, Agliano M. (2018) An abnormally long styloid process with ossification of the stylohyoid ligament. *Int J Anat Res*. 6(2.1):5101-03.
- Harma R. Stylalgia. (1966) clinical experiences of 52 cases. *Acta Otolaryngol. suppl* 224: 149+.
- Ishwar B, Gavishiddappa H , Balasaheb P, Balappa B, Ambadasu B. (2013) Bilateral elongated styloid process: its anatomical embryological and clinical implications *Int J Med Res Health Sci*. 2(2):273-276.
- Kim E, Hansen K, Frizzi J. (2008) Eagle Syndrome: case report and a review of literature. *Ear Nose Throat J*. 87, 631-633.
- Monsour P A, Young W G. (1986) Variability of styloid process and stylohyoid ligament in panoramic radiographs. *Oral Med Oral Path*. 61: 522-526.
- Massey EW. (1978) Facial pain from an elongated styloid process. (Eagles syndrome). *South Med J*. 71: 1156-1159.
- Prabhu LV, Kumar A, Nayak SR, Pai MM, Vadgaonkar R, Krishnamurthy A, Madhan Kumar SJ. (2007) An unusually lengthy styloid process. *Singapore Med J*. 48(2):34-36.
- Paraskevas G K, Raikos A, Lazos LM, Kitsoulis P (2009) Unilateral elongated styloid process: a case report. *Cases Journal*. 2:9135.
- Patil S, Ghosh S, Vasudeva N. (2014) Morphometric study of the styloid process of temporal bone. *J Clin Diagn Res. Sep*; 8(9):AC04-6.
- Sanjeev Iranna Kolagi , Anita Herur and Ashwini Mutalik. (2010) Elongated styloid process-report of two rare cases. *Int J Anat Var*. 3: 100-102.