

Research Article: Human Anatomy Case Report

## Humeral septal aperture associated with supracondylar process: a case report and review of the literature

George K. Paraskevas<sup>1,\*</sup>, Konstantinos Natsis<sup>1</sup>, Nikolaos Anastasopoulos<sup>1</sup>, Orestis Ioannidis<sup>1</sup>, Panagiotis Kitsoulis<sup>2</sup><sup>1</sup>Department of Anatomy, Medical Faculty of Aristotle University of Thessaloniki, Greece<sup>2</sup>Department of Anatomy-Histology-Embryology, Medical Faculty of University of Ioannina, Greece

Submitted November 12, 2011; accepted February 21, 2012

### Summary

The supracondylar process is usually a beak-like osseous prominence located at the anteromedial aspect of the distal portion of the humerus. It is usually asymptomatic but occasionally may compress underlying structures such as the median or ulnar nerve, the brachial artery or its branches. The term septal aperture defines an oval or round shaped bony defect of the septum that separates the olecranon from the coronoid fossa of the humerus. It is of significance for surgeons because it may alter the fracture pattern at the region and thus their management. We present a rare case of coexistence of supracondylar process and septal aperture in a macerated left humerus. The reported incidence of the supracondylar process alone varies from 0.28% to 2.78%, while that of the septal aperture from 6.9% to 60%. We have reviewed the literature and emphasized the radiological and surgical significance of the findings.

### Key words

Humerus; neurovascular compression; impingement; Struthers' ligament; fracture management.

### Introduction

The supracondylar process of the humerus (SCP) is a congenital variation of the distal third of the humerus, also termed supracondyloid, supraepitrochlear, supra-trochlear or supracondylar spur, epicondylar or epicondylic process (Newman, 1969; Terry, 1921). Morphologically, it is usually a beak-like anomalous bony or cartilaginous prominence that arises from the anteromedial surface of the humerus, 3-7 cm proximal to the medial epicondyle, and is directed distally, medially, and anteriorly (Kolb and Moore, 1967; Marquis *et al.*, 1957). Its length varies from a few mm to 20 mm (Ivins, 1996; Laha *et al.*, 1977). The reported incidence of the trait ranges from 0.28% (Newman, 1969) to 2.78% (Adachi, 1928) in the general population; it is usually an incidental finding in plain radiographs of the distal humerus (Subasi *et al.*, 2002).

The septal aperture of the humerus (SA), alternatively termed supratrochlear foramen, is a deficit of the bony septum of the humerus that separates the coronoid from the olecranon fossa. Its incidence in adults varies from 6.9% in American whites (Benfer and Tappen, 1968), to almost 60% in some Northern African and West African

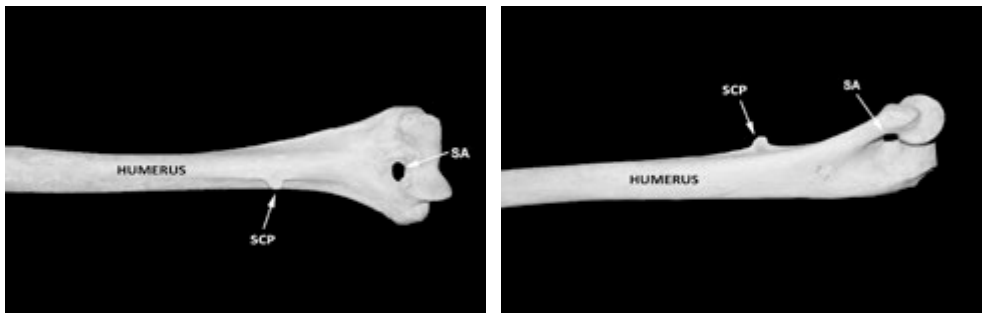
\*Corresponding author. E-mail: g\_paraskevas@yahoo.gr; Tel.: +30 2310 999330.

groups (Glanville, 1967; Meier and Hunt, 2006), and it is more frequent in females (Paraskevas *et al.*, 2010). Besides the anatomical and anthropological interest, the presence of SCP and SA anatomic variants may be of significant radiological and surgical interest in cases of neurovascular impingement as regards SCP (Subasi *et al.*, 2002; Thompson and Edwards, 2005; Tzaveas *et al.*, 2010) and in cases of humeral fractures and their management as concerns the SA (Paraskevas *et al.*, 2010; Sahajpal and Pichora, 2006).

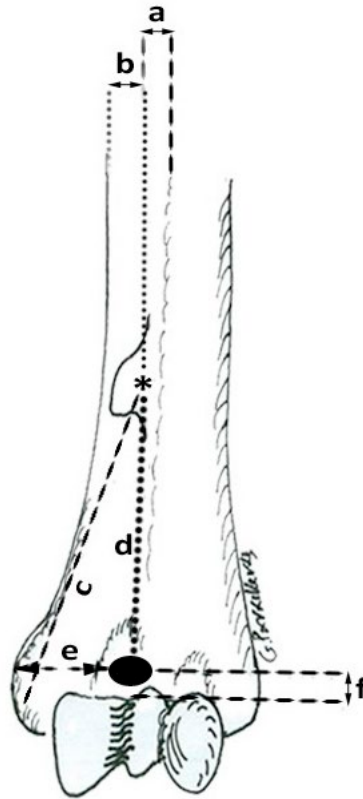
The aim of the present study is to present a rare case of coexistence of SCP and SA, which to the best of our knowledge has been previously reported only once (Varlam *et al.*, 2005). We discuss the possible clinical implications of the variants and review the current literature.

### Case report

In a macerated left humerus belonging to a female derived from the osteological collection of our Anatomy Department, the trait of SCP was encountered in the same humerus along with a SA (Fig. 1). The SCP was noticed on the anteromedial surface of the distal third of the humerus, had spur-like appearance, and was directed medially and anteriorly. The root of the SCP was 7.41 mm long (in proximo-distal direction), while its tip was 3.93 mm long. The middle of the SCP root was located 4.38 mm far from the anterior border and 9.36 mm far from the medial border of the humerus. The middle point of the SCP root was situated 52.54 mm far from the tip of the medial epicondyle of the humerus and 47.32 mm from the center of the SA. The SA in the distal portion of the humerus was oval shaped, with a transverse diameter of 7.81 mm and a vertical diameter of 5.09 mm. The center of the SA was located 21.59 mm from the tip of the medial epicondyle and 5.21 mm (vertical distance) from the superior border of the trochlea. The distance between the medial and lateral epicondyle was 46.72 mm. The distances measured in our study are provided in Fig. 2. All the measurements in the study were made with the aid of a digimatic Vernier sliding caliper accurate to 0.1 mm (Mitutoyo Co., Japan).



**Figure 1** – Supracondylar process (SCP) and septal aperture (SA) as seen from the anterior (a) and medial/oblique (b) aspect of the distal third of a left humerus.



**Figure 2** – Schematic representation of Figure 1. “a” and “b” are the measured distances between the SCP and the anterior, as well as the medial border of the humerus. “c” is the distance between the SCP and the medial epicondyle. “d” is the distance between the SCP and SA. “e” is the distance between the SA and the medial epicondyle. “f” corresponds to the distance between the SA and the superior border of the trochlea. “\*” refers to the base of the SCP.

## Discussion

The SCP is a congenital variation of the distal third of the humerus. It is usually a hook-shaped anomalous bony or cartilaginous prominence that arises at acute angle from the anteromedial surface of the humerus and is usually directed distally, medially and anteriorly towards the medial epicondyle (Kolb and Moore, 1967; Marquis *et al.*, 1957). Such a process has been mentioned in the 16<sup>th</sup> century by Coiter, as cited by Marquis *et al.* (Marquis *et al.*, 1957), but it was first described in apes and monkeys by Tiedemann (1818) and later in humans by Knox (1841). The SCP is rarely found bilaterally (Spinner *et al.*, 1994; Subasi *et al.*, 2002); it is more common on the left side (90%) and in males (60%) (Natsis, 2008). A band of fibrous tissue, which occasionally can be ossified, known as “Struthers’ ligament”, sometimes connects the tip of the SCP with the anterior aspect of the medial epicondyle, thus forming a supracondy-

lar foramen through which the median nerve passes accompanied by the brachial, or ulnar, or even radial artery if a high bifurcation is present (Smith and Fisher, 1973; Spinner *et al.*, 1994). Proximal fibers of the pronator teres, as well as the distal fibers of the coracobrachialis may arise from the SCP or Struthers' ligament (Sener *et al.*, 1998). Furthermore, the ligament may be present without the presence of an SCP (Smith and Fisher, 1973).

The SCP rarely causes any clinical symptoms, it can be found incidentally during plain radiographic examination or palpation of the region by the patient or his/her physician (Laha *et al.*, 1977). The clinical syndromes possibly associated with SCP are median nerve entrapment with or without brachial artery compression, ulnar nerve with or without median nerve entrapment and fracture of the process (Ivins, 1996; Laha *et al.*, 1997; Newman, 1969). Simultaneous compression of the median and ulnar nerve is infrequent (Mittal and Gupta, 1978; Thomsen, 1977). The variability of entrapment symptoms depends on the distribution of the median or ulnar nerve and on the degree of entrapment of the brachial artery (Sener *et al.*, 1998). The symptoms usually are exacerbated by pronation of the forearm (Sener *et al.*, 1998) or by extension and pronation/supination of the forearm as in the repetitive action of catching a baseball (Thompson and Edwards, 2005). Nerve compression usually induces intense pain, paresthesia, sensory loss and muscular weakness in the area of median nerve distribution (Ivins, 1996; Koppel and Thompson, 1963). Although the ulnar nerve lies posterior to the SCP, it may be compromised over the spur during flexion of the elbow originating symptoms of ulnar neuropathy (Tzaveas *et al.*, 2010). Furthermore, the median nerve and the brachial artery may be stretched over the bony process on extension and supination of the forearm and originate symptoms in cases with SCP lying posterior to them (Ay *et al.*, 2002). In rare cases of localized brachial artery compression due to SCP, ischemic symptoms such as claudication and coldness, and reduced radial or ulnar pulses can be detected (Ivins, 1996; Thompson and Edwards, 2005). The diagnosis can be proposed on palpation, although it may escape in patients with well-developed musculature, but confirmation by radiographic imaging is mandatory (Laha *et al.*, 1977). Electrophysiological studies as well as Doppler evaluation may be helpful to confirm the diagnosis (Subasi *et al.*, 2002). Fracture of the process after a traumatic incident may evoke localized compression phenomena (Spinner *et al.*, 1994). In symptomatic cases, the nerve or arterial impingement caused by the presence or fracture of the SCP can be relieved after surgical resection of the process; the underlying periosteum should be also resected to prevent SCP recurrence (Ivins, 1996; Thompson and Edwards, 2005). Differential diagnosis includes bony formations that may mimic SCP such as osteochondroma and myositis ossificans (Fragiadakis and Lamb, 1970; Subasi *et al.*, 2002). It has been reported that the median nerve can be entrapped by Struthers' ligament alone even in cases where there is no SCP (Smith and Fisher, 1993).

The SA is a foramen of the bony septum that separates the olecranon from the coronoid fossae at the distal end of the humerus. It was first reported by Meckel in 1825 as cited by Kate and Dubey (Kate and Dubey, 1970). Genetic and environmental factors such as nutrition and working conditions with extensive impact pressure from the olecranon have been assumed as factors that may modify the thickness of the supratrochlear septum (Glanville, 1967). The SA is usually more frequent in females than in males (Akabori, 1934; Genovels, 1958; Mahajan, 2011; Paraskevas *et al.*, 2010), although

there are reports of a greater incidence in males (Glanville, 1967; Meier and Hunt, 2006). The SA, when present, is more commonly found on the left-side (Mahajan, 2011; Singhal and Rao, 2007). The majority of the apertures are oval shaped, while some are round or triangular (Nayak *et al.*, 2009). According to Singhal *et al.*, 66% of the supra-trochlear septa in their study were translucent (Singhal and Rao, 2007).

The SA beyond its anthropological interest appears to be of clinical and surgical importance as well. It may lead to increased local stress and significantly alter the pattern and stability of fractures (Kuhn *et al.*, 1995; Sahajpal, and Pichora, 2006). It may also interfere with fracture therapy. According to Akpinar *et al.* (2003), in two bones with SA the distal part of the medullary canal was too narrow for effective nailing, being less than 4 mm. Nayak *et al.* (2009) observed in plain radiographs that the SA was located closer to the medial epicondyle resulting in difficult intramedullary nailing. Paraskevas *et al.* (2010) noticed that the distal portion of the medullary canal in humeri with SA was narrower and shorter at the entry point of a retrograde nail than in humeri without a SA. Additionally, the SA is a relatively radiolucent area commonly described as a "pseudo lesion" in an x-ray of the upper limb and can be mistaken as an osteolytic or cystic lesion (De Wilde *et al.*, 2004).

In the literature we were able to detect only one similar case of coexistence of SCP and SA in the same humerus (Varlam *et al.*, 2005). For comparison with the present findings, in that case the length of the base and tip of the SCP was 9.01 mm and 6.15 mm, respectively, and the superior and inferior borders were 10.86 mm and 9.44 mm long, respectively. The SA was elliptical also in that case with diameters 6.32 mm and 4.36 mm. The superior, inferior, anterior and posterior angles formed between the longitudinal axis of the SCP and the humeral shaft (not measured here), were 149.66°, 59.36°, 177.32° and 88.45°, respectively.

The significance of our findings of coexistence of a SCP with a SA contributes to the available catalogue of anatomical variants and might be useful for anthropologists, orthopaedic surgeons, and radiologists in their everyday clinical practice.

## Conclusions

Although the trait of SCP and SA is familiar to anatomists and anthropologists, it remains quite unknown to clinicians, since it is overlooked in most standard textbooks. The awareness of SA is important for the orthopaedic surgeons, since it may affect the preoperative planning in case of distal humerus fracture, whilst the possibility of a SCP must be suspected in patients presenting with symptomatology of median or ulnar nerve entrapment, as well as with brachial artery obstruction. Furthermore, radiologists need to be familiar with the variants in order to avoid misdiagnosis during interpretation of plain radiographs and computed tomography scans of the distal third of the humerus.

## Acknowledgements

The authors declare that they have no competing interests. We are indebted to Dr. Athanasios Raikos for his technical assistance during photographic documentation of

Fig. 1. GKP analyzed the specimen from the osteological collection of the Anatomy Department and supervised the manuscript writing. GKP, KN, NA and PK performed the literature review and wrote the draft of the manuscript. GKP and OI made critical review and final editing of the manuscript. GKP designed the schematic drawing. All the authors have read and approved the final manuscript. Written consent was obtained from the cadaver's next of kin for the publication of this article.

## References

- Adachi B. (1928) *Das Arteriensystem der Japaner*. Vol. 1. Kyoto: Maruzen. Pp. 296-304.
- Akabori E. (1934) Septal aperture in the humerus in Japanese and in Koreans. *Am. J. Phys. Anthropology* 18: 395-401.
- Akpinar F., Aydinlioglu A., Tosun N., Dogan A., Tuncay I., Unal O. (2003) A morphometric study on the humerus for intramedullary fixation. *Tohoku J. Exp. Med.* 199: 35-42.
- Ay S., Bektas U., Yilmaz C., Diren B. (2002) An unusual supracondylar process syndrome. *J. Hand Surg. Am.* 27A: 913-915.
- Benfer R.A., Tappen N.C. (1968) The occurrence of the septal perforation of the humerus in three non-human primate species. *Am. J. Phys. Anthropol.* 29: 14-28.
- De Wilde V., De Maeseneer M., Lenchik L., Van Roy P., Beeckman P., Osteaux M. (2004) Normal osseous variants presenting as cystic or lucent areas on radiography and CT imaging: A pictorial overview. *Eur. J. Radiol.* 51: 77-84.
- Fragiadakis E.G., Lamb D.W. (1970) An unusual case of ulnar nerve compression. *Hand* 2: 14.
- Genovels S. (1958) Estudio de los restos oseos de Coixtahxuaca, Caxaca. *Miscellanea Paul Rivet* 1: 455-484.
- Glanville E.V. (1967) Perforation of the coronoid-olecranon septum. humero-ulnar relationships in Netherlands and African populations. *Am. J. Phys. Anthropol.* 26: 85-92.
- Ivins G.K. (1996) Supracondylar process syndrome: a case report. *J. Hand Surg. Am.* 21: 279-281.
- Kate B.R. and Dubey P.N. (1970) A note on the septal apertures in the humerus of Central Indians. *E. Anthropol.* 33: 105-110
- Knox R. (1841) On the occasional presence of a supracondyloid process in the human humerus. *Edinb. Med. Surg. J.* 56: 125-128.
- Kolb L.W., Moore R.D. (1967) Fractures of the supracondylar process of the humerus. Report of two cases. *J. Bone Joint Surg.* 49: 532-534.
- Koppel H.P., Thompson W.A.L. (1963) *Peripheral entrapment neuropathies*. Baltimore: Williams & Wilkins. Pp. 101-105.
- Kuhn J.E., Lois D.S., Loder R.T. (1995) Divergent single-column fractures of the distal part of the humerus. *J. Bone Joint Surg.* 77: 538-542.
- Laha R.K., Dujovny M., DeCastro S.C. (1977) Entrapment of median nerve by supracondylar process of the humerus: case report. *J. Neurosurg.* 46: 252-255.
- Mahajan A. (2011) Supratrochlear foramen: Study of humerus in North Indians. *Professional Med. J.* 18: 128-132.

- Marquis J.W., Bruwer A.J., Keith H.M. (1957) Supracondyloid process of the humerus. *Proc. Staff Meet. Mayo Clin.* 32: 691-697.
- Meier L.N., Hunt D.R. (2006) Incidence of humeral septal aperture and its relation to population and sex. *Am. J. Phys. Anthropol. (Suppl.)* 42: 129.
- Mittal R.L., Gupta B.R. (1978) Median and ulnar nerve palsy: an unusual presentation of the supracondylar process. *J. Bone Joint Surg.* 60: 557-558.
- Natsis K. (2008) Supracondylar process of the humerus: Study on 375 Caucasian subjects in Cologne, Germany. *Clin. Anat.* 21: 138-141.
- Nayak S.R., Das S., Krishnamurthy A., Prabhu L.V., Potu B.K. (2009) Supratrochlear foramen of the humerus: An anatomico-radiological study with clinical implications. *Ups. J. Med. Sci.* 114: 90-94.
- Newman A. (1969) The supracondylar process and its fracture. *Am. J. Roentgenol. Radium. Ther. Nucl. Med.* 105: 844-849.
- Paraskevas G.K., Papaziogas B., Tzaveas A., Giaglis G., Kitsoulis P., Natsis K. (2010) The supratrochlear foramen of the humerus and its relation to the medullary canal: A potential surgical application. *Med. Sci. Monit.* 16: BR119-123.
- Sahajpal D.T., Pichora D. (2006) Septal aperture: an anatomic variant predisposing to bilateral low-energy fractures of the distal humerus. *Can. J. Surg.* 49: 363-364.
- Sener E., Takka S., Cila E. (1998) Supracondylar process syndrome. *Arch. Orthop. Trauma Surg.* 117: 418-419.
- Singhal S., Rao V. (2007) Supratrochlear foramen of the humerus. *Anat. Sci. Int.* 82: 105-107.
- Smith R.V., Fisher R.G. (1973) Struther's ligament: a source of median nerve compression above the elbow. *J. Neurosurg.* 38: 778-779.
- Spinner R.J., Lins R.E., Jacobson S.R., Nunley J.A. (1994) Fractures of the supracondylar process of the humerus. *J. Hand Surg. Am.* 19: 1038-1041.
- Subasi M., Kesemenli C., Necmioglu S., Kapukaya A., Demirtas M. (2002) Supracondylar process of the humerus. *Acta Orthop. Belg.* 68: 72-75.
- Terry R.J. (1921) A study of the supracondyloid process in the living. *Am. J. Phys. Anthropol.* 4: 129-139.
- Thompson J.K., Edwards J.D. (2005) Supracondylar process of the humerus causing brachial artery compression and digital embolization in a fast-pitch softball player. A case report. *Vasc. Endovasc. Surg.* 39: 445-448.
- Thomsen P.B. (1977) Processus supracondyloidea humeri with concomitant compression of the median nerve and the ulnar nerve. *Acta Orthop. Scand.* 48: 391-393.
- Tiedemann F. (1818) Ueber einen am Oberarmbein bei Mehreren Geschwanzten Affen Vorkommenden kanal und eine Damit in Verbindung Stehende Besondere Anordnung der Arterien und Nervus des Arms. *Deutsches Archiv für die Physiologie* 4: 544-549.
- Trotter M. (1934) Septal apertures in the humerus of American whites and negroes. *Am. J. Phys. Anthropol.* 1: 213-227.
- Tzaveas A.P., Dimitriadis A.G., Antoniou K.I., Pazis I.G., Paraskevas G.K., Vrettakos A.N. (2010) Supracondylar process of the humerus: A rare case with compression of the ulnar nerve. *J. Plast. Surg. Hand Surg.* 44: 325-326.
- Varlam H., Antohe D.S., Chistol R.O. (2005) Supracondylar process and supratrochlear foramen of the humerus. *Morphologie* 89: 121-125.