

Research Article: Basic and Applied Anatomy

Osteometry of the skull of one-humped camels.

Part I: immature animals

Ahmed Yahaya¹, James O. Olopade^{2,*}, Hyelduku D. Kwari¹, Ibrahim M. Wiam¹¹ Department of Veterinary Anatomy, University of Maiduguri, Nigeria² Department of Veterinary Anatomy, University of Ibadan, Nigeria

Received January 29, 2011; accepted June 14, 2011

Summary

The aim of this study was to investigate osteometric indices of immature camels (2-3 years old) in Nigeria. The cranial length, viscerocranial length, maximum zygomatic width, neurocranial volume, skull and facial index for females and males were 22.1 cm and 22.3 cm; 16.3 cm and 16.7 cm; 15.8 cm and 16.1 cm; 479 ml and 496 ml; 40.9 and 41.3, and 96.4 and 96.2 respectively. The mean orbital horizontal and vertical diameters of young camels were similar to each other giving a near complete circular shape. The foramen magnum index was over 100 because of a relatively higher height than width. The data were compared with those of other types of immature camels in the literature and will be useful for anatomical, developmental, anthropological and clinical studies of camels.

Key words

Anatomy; domestic animals; skull; morphometry; young.

Introduction

It is estimated that over 70% of the world camel population is found in Africa; most of these camels are of the dromedary species and found mainly in the semi desert areas like Ethiopia, Somalia, Sudan and Mauritania (Knoess, 1977). There has been an increasing desertification rate in Nigeria's northern arid zones in the last decades (Omijeh, 2008) and most camels in Nigeria have migrated to these zones through the semi arid and arid tropical access of Niger and Chad (Ghaji and Ade-gwa, 1986).

Camels usually have accelerated body weight increase in the first four years of life after which the increase becomes minimal and are actually recommended to be slaughtered at about 5 years of age (Burgemeister, 1978). In fact, camels at 2-3 years of age (though may be relatively big in size) have been referred to as immature (Al-Sagair and Elmougy, 2002).

The literature on craniometric indices of the camel is scanty. We have been investigating the skull morphometry of camels in Nigeria and report herein the osteometric anatomy of immature camels.

*Corresponding author. Email addresses: jkayodeolopade@yahoo.com, jo.olopade@mail.ui.edu.ng.

Materials and methods

A total of 12 immature camels (2-3 years old), 6 males and 6 females, were used for this study. The heads were obtained after slaughter from Maiduguri main abattoir in North East Nigeria; the ages had been estimated based on works of Williamson and Payne (1978) and Wilson (1984). The skulls were macerated based on works of Onar *et al.* (1997) and Olopade and Onwuka (2009). A total of 45 craniometric indices were measured in each skull and were adapted from Brehm *et al.* (1985), Onar (2001), Endo *et al.* (2002), Al-Sagair and Elmougy (2002), Olopade and Onwuka (2008; 2009). The landmarks for each index measured are described below and most are depicted in Figs. 1-7.

Values for each measurement were expressed as means \pm standard deviation while independent samples t-test was used to test the sex difference.

Craniometric measurements and indices

1. Inter-orbital width (**IOW**): Minimum distance between the upper edges of the orbits measured across the tip of the skull (Fig. 1).
2. Inter-canthi distance (**ICD**): Minimum distance between the median margins of the orbits (Fig. 1).
3. Maximum width of the neurocranium (**WNC**): Distance from the most lateral point of the cranial cavity on the left to most lateral point of the cranial cavity on the right (Fig. 1).
4. Nasal length along the mid-line (**NL1**): Overall length of the nasal bones along the midline (Fig. 1).
5. Nasal length on the side (**NL2**): Maximum length of the nasal bone along the side (Fig. 1).

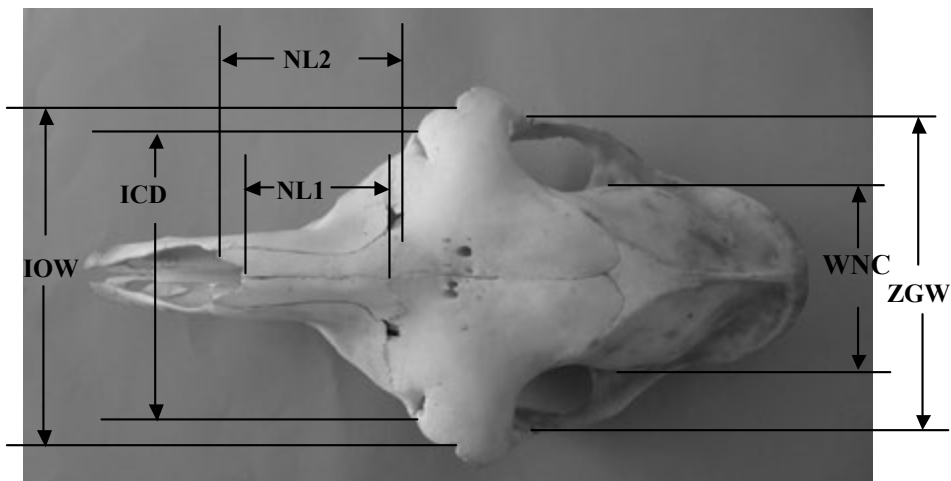


Figure 1 – Young camel skull (dorsal view) showing maximum zygomatic width (ZGW), maximum width of the neurocranium (WNC), interorbital width (IOW), nasal length along the midline (NL1), nasal length along the side (NL2) and inter-canthi distance (ICD).

6. Nasal width (**NW**): Maximum width of the nasal bone (Fig. 2).
7. Maximum zygomatic width (**ZGW**): Maximum width across the zygomatic arches (Fig. 1).
8. Nasal index (**NI**): $(ZGW \times 100) / NL1$.
9. Cranial length (**CL**): Distance from nuchal crest to the junction of the left and right nasofrontal sutures on the median plane (Fig. 2).
10. Cranial index (**CI**): $(WNC \times 100) / CL$.
11. Viscerocranial length (**VCL**): Distance from the junction of the left and right nasofrontal sutures in the median plane to the anterior end of the inter-incisive suture (Fig. 2).
12. Facial index (**FI**): $(ZGW \times 100) / VCL$.
13. External sagittal crest length (**ESCL**): Distance from the caudal extremity of the external crest to the origin of its cranial bifurcation (Fig. 2).
14. Skull length (**SL**): Maximum length of the skull from the cranial tip of the incisive bones to the caudal end of the nuchal crest (Fig. 2).
15. Distance between the left and right depression (**DMXD**): Distance between the ventral bony limit of the left maxillary depression rostral to the second upper premolar measured over the nasal bone to the corresponding point on the right side (Fig. 3).
16. Skull height (without mandible) (**SH**): Length from the level of the highest point of the frontal bone to the base of the jugular process (Fig. 3).
17. Orbital circumference length (**OBCL**): Maximum circumference of the orbit, along the rim (Fig. 3).

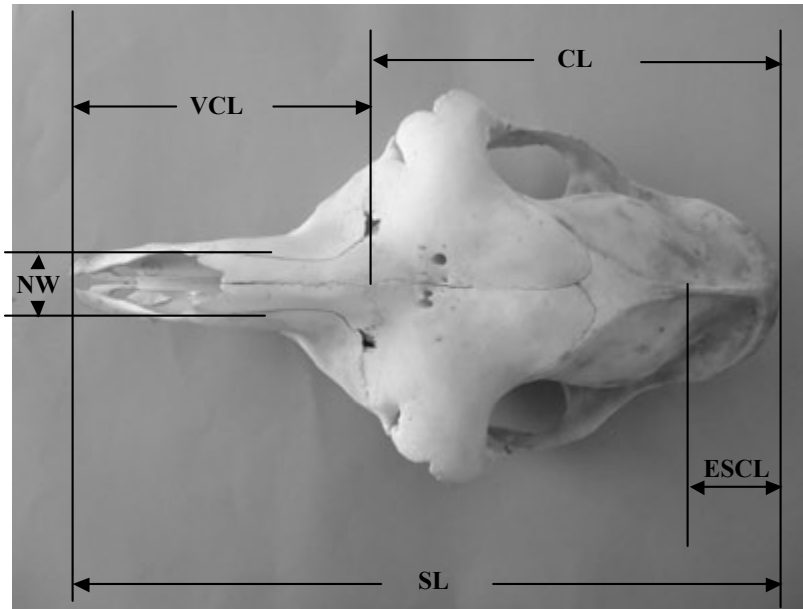


Figure 2 – Young camel skull (dorsal view) showing viscerocranial length (VCL), cranial length (CL), external sagittal crest length (ESCL), nasal width (NW) and skull length (SL).

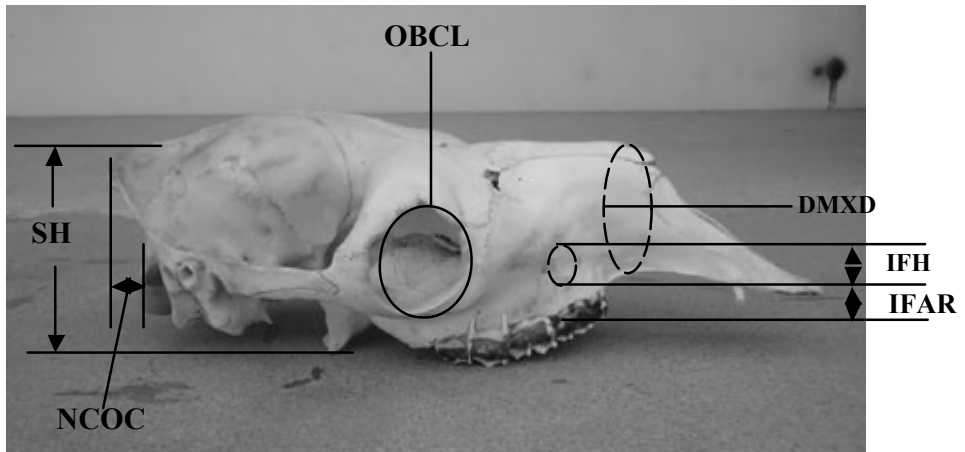


Figure 3 – Young camel skull without the mandible (lateral view) showing orbital circumference length (OBCL), distance between the left and right depression (DMXD), distance from nuchal crest to occipital condyle (NCOC) infraorbital height (IFH), distance from infraorbital foramen to dorsal root of alveoli (IFAR) and skull height (SH).

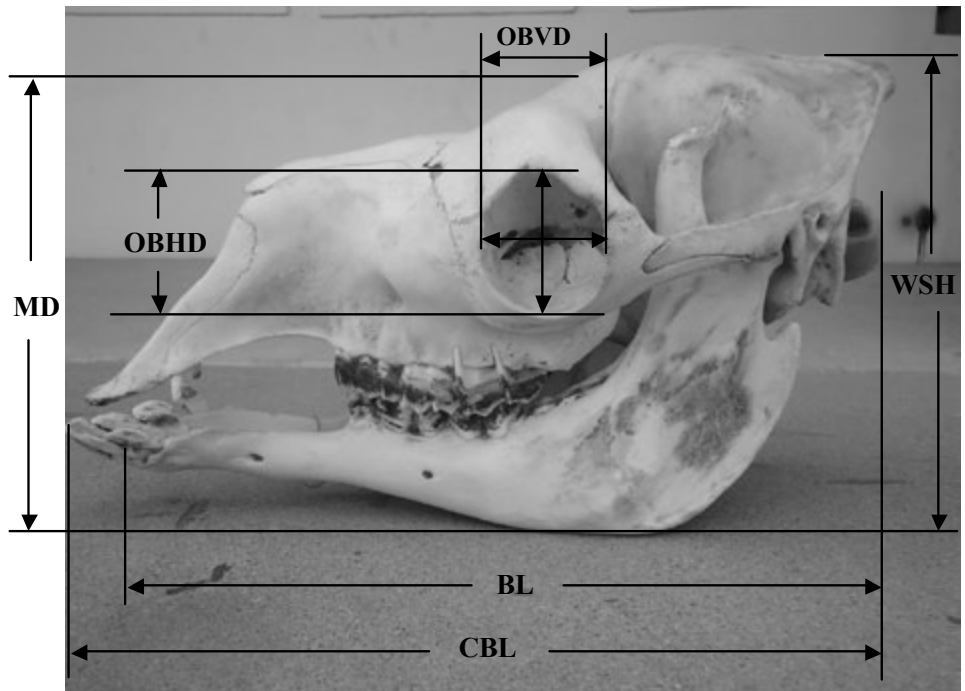


Figure 4 – Young camel skull with the mandible (lateral view) showing orbital horizontal diameter (OBHD), orbital vertical diameter (OBVD), condylobasal length (CBL), basal length (BL), mandibular depth (MD) and whole skull height (WSH).

18. Orbital horizontal diameter (**OBHD**): Maximum horizontal diameter of the orbit (Fig. 4).
19. Orbital vertical diameter (**OBVD**): Maximum vertical diameter of the orbit (Fig. 4).
20. Condylbasal length (**CBL**): Length of the skull measured from the cranial tip of the incisive bones to the rear surface of the occipital condyles (Fig. 4).
21. Basal length (**BL**): Length from the cranial alveolar end of the mandible to the occipital condyles at the level of the jugular process (Fig. 4).
22. Whole skull height (**WSH**): Distance from the highest level of the external sagittal crest to the lowest level of the mandible (Fig. 4).
23. Mandibular depth (**MD**): Distance measured from the point of bifurcation of the external sagittal crest to the lowest point of the angle of the mandible (Fig. 4).
24. Infraorbital foramen height (**IFH**): Minimum distance between the dorsal and ventral brim of the foramen (Fig. 3).
25. Infraorbital foramen to alveoli margin (**IFAR**): Direct distance from the lower brim of the infraorbital foramen to the alveolar margin (Fig. 3).
26. Mandibular index (**MDI**): $(MD \times 100) / BL$.
27. Skull index (**SI**): $(ZGW \times 100) / SL$.
28. Foramen magnum height (**FMH**): Mid-vertical height of the foramen magnum (Fig. 5).
29. Foramen magnum width (**FMW**): Largest width of the foramen magnum (Fig. 5).
30. Occipital triangle height (**OCTH 1**): Distance from the nuchal crest to the lower brim of the foramen magnum (Fig. 5).
31. Occipital triangle height (without foramen magnum) (**OCTH 2**): Distance from the caudoventral projection of the nuchal crest to the upper rim of the foramen magnum (Fig. 5).
32. Intercondylar width (**ICW**): Width between the lateral ends of the occipital condyles (Fig. 5).
33. Interparacondylar width (**IPCW**): The greatest breadth between the ventromedial end of the jugular processes (Fig. 5).
34. Paracondylar process length (**PCPL**): Length from the tip of the paracondylar process to its junction with the squamous occipital bone (Fig. 5).
35. Maximum paracondylar process thickness (**PCPT**): Circumference around the thickest part of the paracondylar process.
36. Occipital condyle thickness (**OCT**): Maximum width of single occipital condyle from the most lateral extent to the foramen magnum (Fig. 5).
37. Foramen magnum index (**FMI**): $FMH / FMW \times 100$
38. Nuchal crest to occipital condyle (**NCOC**): Distance from the cranial end of the alveolar process of the mandible to the caudal end of the nuchal crest (Fig. 3).
39. Palate width at molar 1 (**PLW1**): Width between the median limits of the alveoli at the level of the first molar (Fig. 6).
40. Palate width at molar 2 (**PLW2**): Width across the median limits of the alveoli at the level of the second molar (Fig. 6).
41. Palate length (**PLL**): Length from the midline of the caudal end of the palatine bone to the cranial midline of the palatine part of the maxillary bone (Fig. 6).
42. Hard palate length (**HPLL**): Distance from the midline of the caudal end of palatine bone to the rostral end of the incisive bone on the midline (Fig. 6).

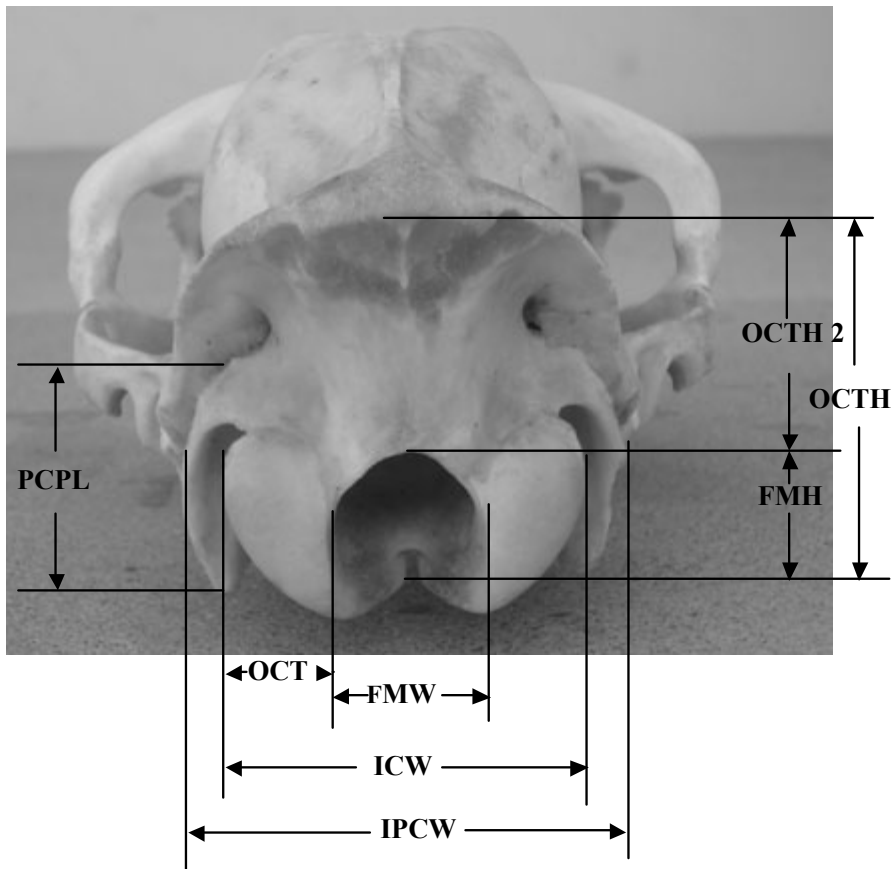


Figure 5 – Young camel skull (caudal view) showing foramen magnum height (FMH), foramen magnum width (FMW), occipital triangle height (OCTH 1), occipital triangle height (without foramen magnum) (OCTH 2), intercondylar width (ICW), interparacondylar width (IPCW), paracondylar process length (PCPL) and occipital condyle thickness (OCT).

43. Neurocranium height (NCH): Vertical distance from the deepest indentation of the sella turcica to the inner aspect of the cranium roof (Fig. 7).
44. Neurocranium length (NCL): Length along the midline from the deepest indentation of the frontoethmoidal junction to the inner aspect of the external occipital protuberance (Fig. 7).
45. Neurocranium volume (NCV). The volume of the neurocranium in milliliters; measured by using fresh plasticine to block all the foramina of the intact skull and filling the neurocranium with fine quality millet grains through the foramen magnum to the level of the distal border of the foramen. The millet was then emptied into a measuring cylinder to determine the volume.

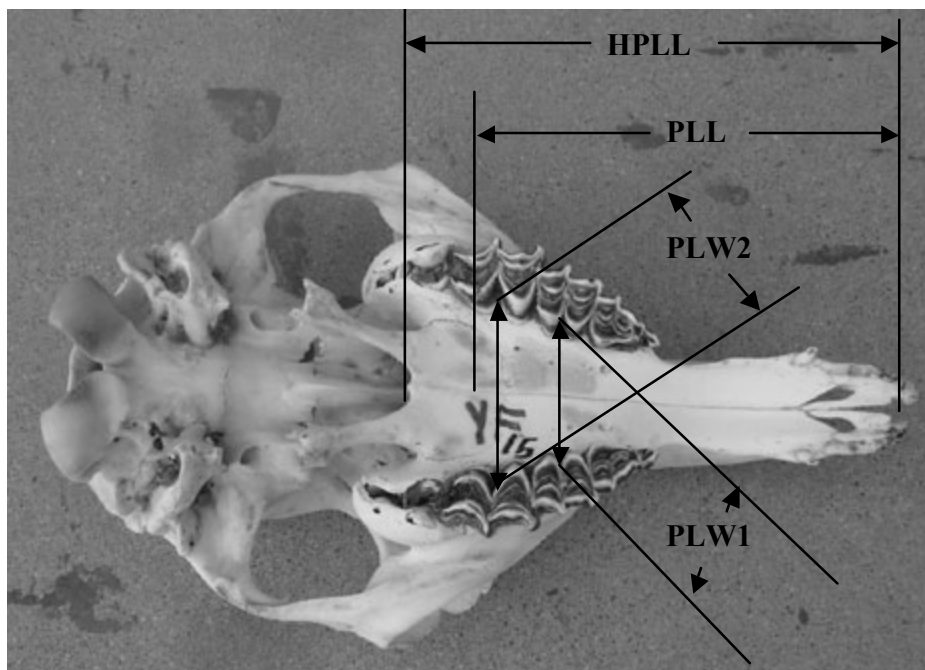


Figure 6 – Young camel skull (ventral view) showing palate width at molar 1 (PLW1), palate width at molar 2 (PLW2), palate length (PLL) and hard palate length (HPLL).




Figure 7 – Sagittal sections of the skull of a young camel showing neurocranium height (NCH) and neurocranium length (NCL).

Results

The data obtained for females and males are shown in Tables 1-4. No significant difference was seen in all 45 skull parameters studied between females and males. The value of the nasal index was high, i.e. the nose was relatively quite wide. The inter-orbital width was longer than the inter-canthi distance (ICD) while the orbital horizontal and vertical diameters were similar, i.e. the orbits were round and located on a fronto-lateral oblique plane. The foramen magnum height was larger than the width, meaning that it was elliptical with vertical major axis.

Discussion

This report at the best of our knowledge is the most comprehensive in the literature on the skull of immature camels. A total of 45 craniometric indices were determined and no significant differences were observed between the sexes; this implies that osteometric parameters of immature camels may not be sexually dimorphic. This is similar to findings in most of the craniometric measurements in the Pyrenean chamois (Garcia-Gonzalez and Barandalla, 2002) in which no marked sexual dimor-

Table 1 – Skull measures and indices of young one-humped camel in Nigeria (appreciable from a dorsal view)

Measurement	Mean	Male	Female	Intersexual difference
Inter-orbital width (IOW)	15.27± 0.22	15.52± 0.24	15.02± 0.35	NS
Inter-canthi distance (ICD)	12.82± 0.17	12.95± 0.21	12.68± 0.27	NS
Maximum width of the neurocranium (WNC)	9.19± 0.08	9.35± 0.13	9.03± 0.07	NS
Nasal length through the mid-line (NL1)	5.93± 0.20	6.20± 0.28	5.67± 0.27	NS
Nasal length through the lateral (NL2)	8.26± 0.18	8.38± 0.29	8.13± 0.22	NS
Nasal width (NW)	2.76± 0.05	2.87± 0.06	2.65± 0.06	NS
Maximum zygomatic width (ZGW)	15.93± 0.14	16.07± 0.15	15.78± 0.24	NS
Cranial length (CL)	22.23± 0.27	22.30± 0.48	22.17± 0.31	NS
Viserocranial length (VCL)	16.55± 0.24	16.72± 0.32	16.38± 0.36	NS
External sagittal crest length (ESCL)	7.93± 0.37	7.67± 0.61	8.18± 0.46	NS
Distance between the left and right maxillary depression (DMXD)	18.04± 0.19	18.28± 0.28	17.80± 0.26	NS
Nasal index (NI)	271.64± 9.14	261.65± 11.59	281.63± 13.90	NS
Cranial index (CI)	41.42± 0.43	42.07± 0.70	40.77± 0.40	NS
Facial index (FI)	96.35± 0.95	96.23± 1.39	96.47± 1.44	NS

NS: not significant

Table 2 – Skull measures and indices of young one-humped camel in Nigeria (appreciable from a lateral view)

Measurement	Mean	Male	Female	Intersexual difference
Condylbasal length (CBL)	37.74± 0.36	37.92± 0.55	37.57± 0.51	NS
Skull length (SL)	38.88± 0.45	39.17± 0.68	38.58± 0.64	NS
Basal length (BL)	35.26± 0.32	35.32± 0.55	35.20± 0.37	NS
Whole skull height (WSH)	19.29± 0.21	19.33± 0.31	19.25± 0.31	NS
Mandibular depth (MD)	18.90± 0.18	19.00± 0.21	18.80± 0.31	NS
Skull height (without mandible) (SH)	11.61± 0.16	11.45± 0.18	11.77± 0.27	NS
Orbital circumference length (OBCL)	17.14± 0.15	17.13± 0.13	17.15± 0.29	NS
Orbital horizontal diameter (OBHD)	5.45± 0.06	5.48± 0.09	5.42± 0.09	NS
Orbital vertical diameter(OBVD)	5.48± 0.04	5.47± 0.06	5.50± 0.05	NS
Infraorbital foramen height (IFH)	2.37± 0.05	2.30± 0.09	2.43± 0.06	NS
Infraorbital foramen to dorsal alveoli root (IFAR)	1.00± 0.02	1.02± 0.03	0.98± 0.03	NS
Mandibular index (MI)	53.63± 0.34	53.83± 0.55	53.42± 0.45	NS
Skull index (SI)	40.99± 0.33	41.05± 0.38	40.93± 0.57	NS

NS: not significant

Table 3 – Skull measurements and indices of young one-humped camel in Nigeria (appreciable from a caudal view)

Measurement	Mean	Male	Female	Intersexual difference
Foramen magnum height (FMH)	3.29± 0.05	3.32± 0.07	3.27± 0.06	NS
Foramen magnum width (FMW)	3.18± 0.05	3.23± 0.07	3.13± 0.06	NS
Occipital triangle height (OCTH1)	8.21± 0.08	8.25± 0.11	8.17± 0.11	NS
Occipital triangle height (without foramen magnum) (OCTH2)	5.19± 0.09	5.20± 0.13	5.18± 0.13	NS
Intercondylar width (ICW)	8.25± 0.13	8.45± 0.17	8.05± 0.18	NS
Interparacondylar width (IPCW)	7.97± 0.14	8.25± 0.19	7.68± 0.14	NS
Paracondylar process length (PCPL)	2.73± 0.05	2.78± 0.07	2.67± 0.06	NS
Maximum paracondylar process thickness (PCPT)	0.57± 0.03	0.52± 0.02	0.62± 0.04	NS
Occipital condyle thickness (OCT)	2.53± 0.04	2.58± 0.08	2.47± 0.03	NS
Foramen magnum index (FMI)	103.58± 1.71	102.83± 3.17	104.33± 1.63	NS
Nuchal crest to occipital condyle (NCOC)	1.22± 0.16	1.25± 0.22	1.18± 0.25	NS

NS: not significant

Table 4 – Skull measurements and indices of young one-humped camel in Nigeria (appreciable from a medial view and from a ventral view)

Measurement	Mean	Male	Female	Intersexual difference
Palatal width at molar 1 (PLW1)	3.57± 0.11	3.55± 0.22	3.58± 0.08	NS
Palatal width at molar 2 (PLW2)	4.43± 0.04	4.47± 0.06	4.38± 0.05	NS
Palatal length (PLL)	17.33± 0.24	17.55± 0.34	17.12± 0.35	NS
Hard palate length (HPLL)	21.34± 0.32	21.48± 0.44	21.20± 0.49	NS
Neurocranium volume (NCV)	487.92± 7.55	496.67± 13.40	479.17± 6.38	NS
Neurocranium height (NCH)	7.27± 0.08	7.40± 0.12	7.13± 0.07	NS
Neurocranium length (NCL)	15.25± 0.08	15.40± 0.06	15.10± 0.06	NS

NS: not significant

phism was observed in most of the skull indices measured. However, the fact that camels have accelerated growth in the first four years of life (Burgemeister, 1978) leaves open the possibility that sexual dimorphism may be found in our ongoing study on adult camels.

The skull index (SI), maximum zygomatic width (ZGW) and skull length (SL) were similar to those obtained by Al-Sagar and El Mongy (2002) in age matched immature camels of the Malha phenotype in Saudi Arabia. The SI values were similar because of minute differences in the ZGW and SL which are the indices for calculating the SI (see methods). However, Al-Sagar and Elmongy (2002) reported higher figures in viscerocranial length (VCL) and maximum neurocranium width (WNC), and a far higher figure for cranial index (CI) (20.55 cm, 11.33 cm and 73.70 respectively). In addition, they reported lower figures for cranial length (CL) and facial index (FI) and a far lower figure for neurocranial volume (NCV): 15.45 cm, 72.31 and 231.73 and respectively. The huge differences from our CI data (40.7 cm for females and 42.07 cm for males) arose from the fact that the WNC of Malha camel was higher and the CL was hugely smaller. Though we used similar methodologies as these authors for NCV, our result was twice as high as that for Malha camels. This largely arose from much longer neurocranial length (15.10 cm and 15.40 cm) and height (17.15 cm and 7.45 cm, for females and males respectively) in Maiduguri than in Malha camels. These facts may imply differences in brain volume and weight (Olopade and Onwuka, 2010). The differences in facial index arose from differences in VCL data even though both camel groups showed similarities in ZGW. The longer VCL implies that Malha camels at least in the immature stage have a more long-nosed shape than Maiduguri camels.

The inter-orbital width (IOW) in our study was 15.27±0.22 cm while the intercanthi distance (ICD) and orbital circumference were 12.82±0.17 cm and 17.14±0.15 cm respectively. The fact that the orbital horizontal and vertical diameters were similar (5.45±0.06 cm and 5.48±0.04 cm) indicates that the orbits were almost completely spherical in these camels.

The foramen magnum Index (FMI) in Maiduguri camels was over 100 as a result of foramen magnum height being higher than width. Animals with similar fora-

men magnum morphology are West African Dwarf goats (Olopade, 2006), whereas Red Sokoto goats (Olopade and Onwuka, 2008), Sahel goats (Olopade and Onwuka, 2009), rabbits and Alsatian dogs (Kahvecioglu et al., 2000, Onar et al. 1997) have FMI below 100.

The study has shown absence of sexual dimorphism in the osteometry of immature camels and this could be of importance in paleontological studies as similarities in cranial measurements of fossils may not mean that they are of the same sex if they are immature animals. In addition, our work has provided baseline data on the skull osteometry that will be useful for comparative anatomical and developmental studies between age groups and breeds of camels, and for clinicians who work on the camel.

References

- Al-Sagair O., ElMougy S.A. (2002) Post-natal development in the linear and tric morphometrics of the camelidae skull. *Anat. Histol. Embryol.* 31: 232-236.
- Brehm H., Loeffler K., Komeyli H. (1985) Skull shape in the dog. *Anat. Histol. Embryol.* 14: 324-331.
- Burgemeister R. (1978) Distribution and use of dromedaries. *Anim. Res. Dev.* 7: 39-48.
- Endo H., Hayashi Y., Yamazaki K., Motokawa M., Pei J., Lin L., Chou C., Oshida T. (2002) Geographical variation of the mandible size and shape in the wild pig (*Sus scrofa*) from Taiwan and Japan. *Zool. Studies* 41: 452-460.
- Garcia-Gonzalez R., Barandalla I., (2002) Sexual dimorphism of Pyrenean chamois (*Rupicapra p. pyrenaica*) based on skull morphometry. *Pirineos* 157: 25-38.
- Ghaji A., Adegwa A.O. (1986) The significance of camel production in Nigeria. *Nig. J. Anim. Sci.* 13: 29-35.
- Kahvecioglu K.O., Onar V., Alpak H., Pazvant G. (2000) The morphometry of the foramen magnum in rabbits and its correlation with craniometric measurements. *Folia Vet.* 44, 62-69.
- Knoess K.H. (1977) The camel as a meat and milk animal. *Word Animal Rev.* 22: 3-8.
- Olopade J.O., Onwuka S.K. (2008) A craniofacial analysis of the skull of Red Sokoto (Maradi) goat (*Capra hircus*). *Eur. J. Anat* 12: 57-62
- Olopade J.O., Onwuka S.K. (2009) Morphometric analysis of the skull of the Sahel goat breed: basic and clinical anatomy. *It. J. Anat. Embryol.* 14: 167-178.
- Omijeh J. (2008) Strategies for the control of desertification in northern Nigeria. *FUTY J. Environ.* 3: 72-83.
- Onar V., Mutuş R., Kahvecioğlu K.O. (1997) Morphometric analysis of the foramen magnum in German shepherd dogs (Alsations). *Ann. Anat.* 179: 563-568.
- Onar V., Özcan S., Pazvant G. (2001) Skull typology of adult male Kangal dogs. *Anat. Histol. Embryol.* 30: 41-48.
- Williamson G., Payne W.J.A. (1978) *An Introduction to Animal Husbandry in the Tropics.* 3rd edn., Longman, London. P. 755.
- Wilson R.T. (1984) *The Camel.* Longman, London & New York. Pp. 60-65.