

Research Article - Human Anatomy Case Report

## Sternalis “mystery” muscle and its clinical implications

Gnanasundaram Vaithianathan\*, Subramanian Aruna, Rajendran Hannah Sugirthabai Rajila, Thotakura Balaji

Department of Anatomy, Chettinad Hospital &amp; Research Institute, Rajiv Gandhi Salai, Kelambakkam, Kanchipuram District, Tamilnadu – 603103, India

Submitted December 19, 2010; accepted May 17, 2011

### Summary

Sternalis is an anomalous muscle found occasionally in the anterior part of the thorax. During routine dissection sternalis muscle was found in a male cadaver. This rare anatomic variant is reported in 8% of the population. In the present case, the muscle was found bilaterally, placed obliquely on either side of the sternum. It originated by tendinous fibres from the lower costal cartilages and inserted to the manubriosternal junction. The right side muscle was well developed whereas the left one was reduced in size. The pectoralis major and minor were normal. The knowledge of sternalis is important for radiologists and surgeons.

### Key words

Sternalis; Pectoralis Major; manubriosternal junction.

### Introduction

The sternalis muscle is a rare anatomic variant, which was reported by Cabrollo (1604) in his book *Anatomes Elenchus Accuratissimus*. The sternalis muscle was formally described by Du Puy (1726). According to Turner (1867), Boerhaave gave a detailed description of this muscle. Since its initial discovery it has been called *musculus sternalis*, *presternalis*, *rectus sternalis*, *sternalis brutorum* or *thoracicus*.

This muscle has been just mentioned in Gray's anatomy as *rectus sternalis*, a variation of *pectoralis major* (Salmons, 1995), and in Langman's Essential Medical Embryology as sternalis, a derivative of rectus column (Sadler, 1995).

The sternalis muscle may be unilateral or bilateral. Its origin may be from sternocleidomastoid muscle (Blees, 1968), pectoralis major (Novakov, 2008), *rectus abdominis* (Blees, 1968), *panniculus carnosus* (Barlow, 1935) or external oblique muscle (Testut, 1884). Here we report a case of bilateral sternalis muscle and discuss the importance of this muscle in breast surgery and mammography.

\* Corresponding author. E-mail: vaithi316@gmail.com; Phone: +919003531705; Fax: +914447411011.

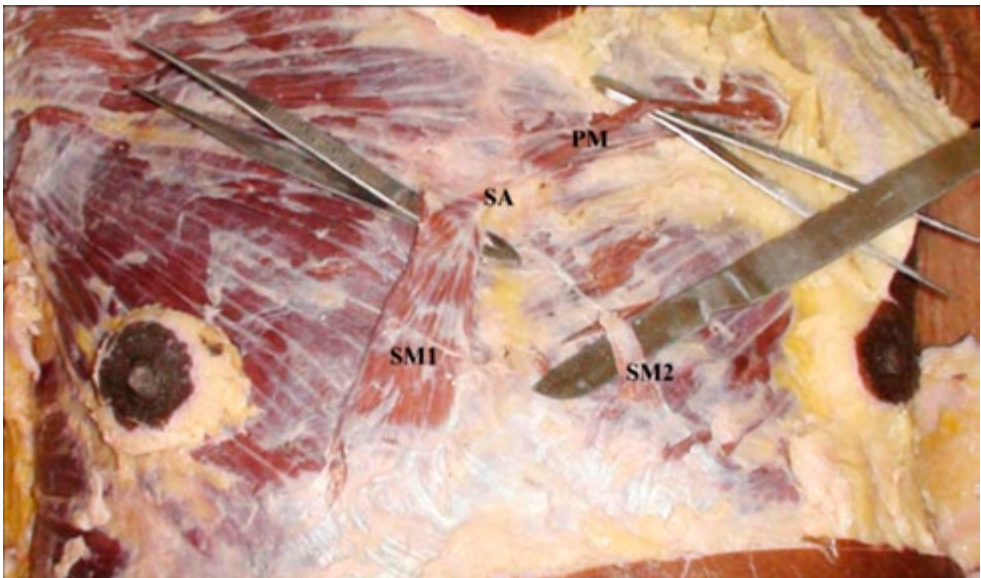
## Methods

Twenty-five cadavers fixed in formalin for dissection were studied along 3 years in the dissection laboratory of Chettinad Hospital & Research Institute, Chennai, India. The cadavers were dissected as part of the undergraduate curriculum in the Medical College. All the cadavers were neatly dissected and the pectoral region was exposed, studying the muscles, nerves and vessels. The length and width of variant muscles were measured using calipers.

## Results

Among 25 cadavers studied in three years, one presented sternalis muscle bilaterally, though asymmetrically. The cadaver was of a 55 year old male. The muscle was found in parasternal position, anterior to the *pectoralis major* and beneath the superficial fascia (Fig. 1).

Both muscles inserted cranially to the manubriosternal junction (sternal angle) and were innervated by the 6<sup>th</sup> intercostal nerve. The right muscle originated from the 7<sup>th</sup> and 8<sup>th</sup> ribs, the corresponding cartilages and the external oblique aponeurosis. It measured 10.5 cm in length and 2 cm in width. The left muscle originated from the 7<sup>th</sup> rib and costal cartilage and the external oblique aponeurosis. It measured 6 cm in length and 0.8 cm in width.



**Figure 1** – Photograph showing bilateral presence of sternalis muscle having its origin from the sternal angle. PM, Pectoralis Major; SM1, Sternalis Muscle – right; SM2, Sternalis Muscle – left; SA, Sternal Angle.

The right muscle was better developed than the left one. Some fibres of insertion of right sternalis blended with the sternal origin of the left *pectoralis major*. The left sternalis ended with a thin tendon. No other variations were encountered in the pectoral region of the cadaver which bore the sternalis muscle.

## Discussion

The sternalis, an anomalous muscle, may belong to the group of pectoral muscles, since it is located in the anterior chest wall, or may derive from abdominal muscles since it shows the same direction of fibres as the latter muscles. The incidence is reported between 3% and 6% irrespective of sex. According to Barlow (1935), the incidence is 11% in Asians, 6% in Afro-Americans, 2% in Europeans. Incidence reported in Indian population is 4-8% (Shah AC, 1968). The incidence of sternalis in cases of anencephaly has been reported to be 48 %. (Schaeffer JP, 1942)

Although it was discovered in the 17<sup>th</sup> century by Cabrollo, the development of this muscle remains elusive. Turner (1867) described it as a form of atavism, corresponding to the *pectoralis cutaneous* of lower animals. According to Ruge (1905), it is a vestige of the cuticular muscle of mammals which are present subcutaneously in trunk, also seen in humans in the form of the axillary arch. Clemente (1985) said it as a misplaced portion of *pectoralis major*. Sadler (1995) interpreted it as part of the ventral longitudinal muscle column arising from the ventral lips of hypomeres. According to Barlow (1935), it represent a remain of *panniculus carnosus*. Kumar et al. (2003) reported bilateral presence of sternalis accompanied by the absence of the sternal head of *pectoralis major*.

In our case the muscle was found in the pectoral region distinct from other muscles. It was not continuous with the abdominal muscle either. The fibre direction was same as that of the abdominal muscles and perpendicular to the pectoral muscle. Therefore we would exclude that it is part of pectoral muscles and rather agree with Sadler (1995) that it as part of the ventral longitudinal column of muscles which during evolution has lost significance; indeed it does not seem to serve any function.

Existing literature states that 55% of sternalis are innervated by branches of internal or external thoracic nerves, 43% by branches of intercostal nerves and 2% by both intercostal and thoracic nerves (O'Neill and Folan-Curran, 1998). Innervation by pectoral nerves has been occasionally reported. The muscle serves no function but it may be confusing for the clinician as it may lead to misdiagnosis of breast tumors in mammograms, where it appears as a density with an ill defined margin on the medial aspect of breast in craniocaudal projection. Harish and Gopinath (2003) studied 1152 patients undergoing radical mastectomy and identified the muscle in eight patients: the incidence percentage is much lower than that reported by Shah (1968). The probable reason for such low incidence might be due to random selection of subjects for the study. This muscle may be relevant to surgery and mammography with respect to dissection planes and the location of internal mammary nodes.

## References

- Barlow R.N. (1935) The sternalis muscle in American whites and Negroes. *Anat. Rec.* 64: 413-426.
- Bergman R.A., Thompson S.A., Afifi A.K., Saadeh F. (1988) *Compendium of Human Anatomic Variation*. Urban and Schwarzenberg, Munich.
- Blees G. (1968) A peculiar type of sternalis muscle. *Acta Morphol. Neerl. Scand.* 7: 69-72.
- Bradley F.M., Hoover H.C., Hulka C.A., Whitman G.J., McCarthy K.A., Hall D.A., Moore R., Kopans D.B. (1996) The sternalis muscle: an unusual normal finding seen on mammography. *AJR Am. J. Roentgenol.* 166: 33-36.
- Cabrollo B. (1604) *Alphabeton anatomikon hoc est anatomes elenchus accuratissimus, omnes humani corporis partes, ea qua solent secari methodo, delineans. Accessere osteologia, obseruationesque medicis iuxta ac chirurgis perutiles*. Jacob Jouet, Geneva.
- Clemente C.D. (1985) *Gray's Anatomy*. 30th ed., Lea and Febiger, Philadelphia. P. 520.
- Cunningham D.J. (1888). The musculus sternalis. *J. Anat. Physiol.* 22: 391-407.
- Futai K. (1931). On the sternalis of the living human. *Juzenkai Zasshi* 36: 399-405.
- Harish K., Gopinath K.S. (2003) Sternalis muscle: importance in surgery of the breast. *Surg. Radiol. Anat.* 25: 311-314.
- Kida M.Y., Kudoh H. (1991) Innervation of the sternalis muscle accompanied by congenital partial absence of the pectoralis major muscle, *Okajimas Folia Anat. Jpn.* 67: 449-455.
- Kumar H., Rath G., Sharma M., Kohli M., Rani B. (2003) Bilateral sternalis with unusual left sided presentation: a clinical perspective. *Yonsei Med. J.* 44: 719-722.
- Larsen W.J., ed (1997) *Human Embryology*. Churchill-Livingstone, Edinburgh.
- Morita M. (1944) Observations of the musculus sternalis and musculi pectorales in mammals and a morphological interpretation of the essence of the musculus sternalis, *Acta Anat. Jpn.* 22: 357-366.
- Novakov S.S., Yotova N.I., Petleshkova T.D., Muletarov S.M. (2008) Sternalis muscle - a riddle that still awaits an answer. *Folia Med. (Plovdiv)* 50: 63-66.
- O'Neill M.N., Folan-Curran J. (1998) Case report: bilateral sternalis muscles with a bilateral pectoralis major anomaly. *J. Anat.* 193: 289-292.
- Rao V.B., Rao G.R.K.F. (1954) The sternalis muscle. *Anat. Soc. India* 3: 49-51.
- Ruge G. (1905). *Der Hautrumpfmuskel der Säugetiere: der M. sternalis und der Achselbogen des Menschen*. *Morph. Jahrb.* 33: 379-531.
- Sadler T.W. (1995) *Langman's Essential Medical Embryology*. Lippincott Williams & Wilkins, Baltimore and Philadelphia. P. 37.
- Salmons S. (1995) Muscle. In: Williams P.L., Bannister L.H., Berry M., Collins P., Dyson M., Dussek J.E., Ferguson M.W.J., eds. *Gray's Anatomy*. 38<sup>th</sup> ed. Churchill-Livingstone, New York. P. 838.
- Schaeffer J.P. (1942) *Morris' Human Anatomy*. 10<sup>th</sup> edn. The Blackiston Company, Philadelphia. Pp. 437.
- Shah A.C. (1968) The sternalis muscle. *Indian J. Med. Sci.* 22: 46-47.
- Shen C.L., Chien C.H., Lee S.H. (1992). A Taiwanese with a pair of sternalis muscles. *Kaibogaku Zasshi* 67: 652-654.

- Testut L. (1884) *Les Anomalies musculaires chez l'homme , expliquées par l'anatomie comparée*. Masson, Paris.
- Turner W.M. (1867) On the musculus sternalis. *J. Anat. Physiol.* 1:246-253.
- Ura R. (1938) A personal interpretation of the origin and nature of the sternalis muscle. *Acta Anat. Jpn.* 7: 64-65.
- Williams P.L., Bannister L.H., Berry M.M., Collins P., Dyson M., Dussek J.E., Ferguson M.W.J., eds. (1995) *Gray's Anatomy*. 38th edn. Churchill-Livingstone, Edinburgh. P. 838.
- Yap S. (1921) Musculus sternalis in Filipinos, *Anat. Rec.* 21: 353-371.