

## The fascia: the forgotten structure

Stecco Carla<sup>1</sup>, Macchi Veronica<sup>1</sup>, Porzionato Andrea<sup>1</sup>, Duparc Fabrice<sup>2</sup>, De Caro Raffaele<sup>1</sup>

<sup>1</sup> Section of Anatomy, Department of Human Anatomy and Physiology, University of Padova, Padova, Italy

<sup>2</sup> Section of Anatomy, Faculté de Médecine Pharmacie, Rouen, France

Submitted March 4, 2011; accepted April 20, 2011

### Summary

This paper examines the main characteristics of the human fascial system, considered in its three-dimensional continuity.

To better understand the anatomy of the human fascial system, a simple diagram of the subcutaneous tissue must be borne in mind. From the skin to the deepest plane, we find the superficial fascia, dividing the subcutaneous tissue into two fibroadipose layers, superficial and deep, and the deep fascia, which envelops all the muscles of the body, showing different characteristics according to region. Under the deep fascia is the epimysium, occurring in the limbs and some regions of the trunk. Skin ligaments connect the superficial fascia to the skin and to the deep fascia, forming a three-dimensional network among the fat lobules.

The typical features of the superficial and deep fasciae and their relationships to nerves, vessels and muscles are reported here, highlighting the possible role of the deep fascia in proprioception and peripheral motor coordination. The main features of the fasciae with imaging techniques are also discussed.

This knowledge may contribute to clinicians' understanding of the myofascial system and the role which the deep fasciae may play in musculoskeletal dysfunctions.

### Key words

Fascia, aponeurosis; epimysium; connective tissue; hypodermis.

### Introduction

In 1987, Myers wrote: "the traditional approach that studies the muscles as independent units, has been a barrier to understand the bigger picture of fascial function". Indeed, the whole musculoskeletal system is usually studied only with respect to its bone and muscle components, the fasciae being traditionally relegated to the role of deftly holding 'parts' together. There has recently been a great increase in interest in both basic and applied research in fasciae, as evidenced by increasing numbers of papers in Pubmed (Schleip, 2009), great participation to congresses focusing on the fasciae, and many types of manual and alternative therapies involving the fascial system. It is increasingly evident that the fasciae may play important roles in venous return (Caggiati, 2000), dissipation of tensional stress concentrated at the sites of entheses (Benjamin et al., 2008), etiology of pain (Langevin et al., 2001; Langevin,

\*Corresponding author. E-mail: rdecaro@unipd.it; Phone: +39 049 8272327; Fax: +39 049 8272319.

This article derives from a presentation at the workshop "Anatomy and Sport" as part of the 64th meeting of the Italian Society of Anatomy and Histology (Taormina, September 15-18, 2010) and is published with the financial support of that Society.

2006), interactions among limb muscles (Huijing *et al.*, 1998; Huijing, 1999; Huijing and Baan, 2001a,b; Yucesoy *et al.*, 2006) and movement perception and coordination (Vleeming *et al.*, 1995, 1996; Stecco L., 1996, 2004; Stecco L. and Stecco C., 2009), due to their unique mechanical properties and rich innervation. Huijing *et al.* (2003) showed that only 70% of muscle tension transmission is directed through tendons, which thus definitely play a mechanical role, but 30% of muscle force is transmitted to the connective tissue surrounding muscles, highlighting the role of the deep fasciae in the peripheral coordination of agonist, antagonist and synergic muscles. The many functions of the fasciae include the roles of the ectoskeleton for muscle attachments and protective sheets for underlying structures (Wood Jones, 1944; Benjiamin, 2009). Lastly, recent studies have emphasized the continuity of the fascial system between regions, leading to presume its role as a body-wide proprioceptive/communicating organ (Langevin, 2006; Langevin *et al.*, 2006; Lindsay, 2008; Kassolik *et al.*, 2009).

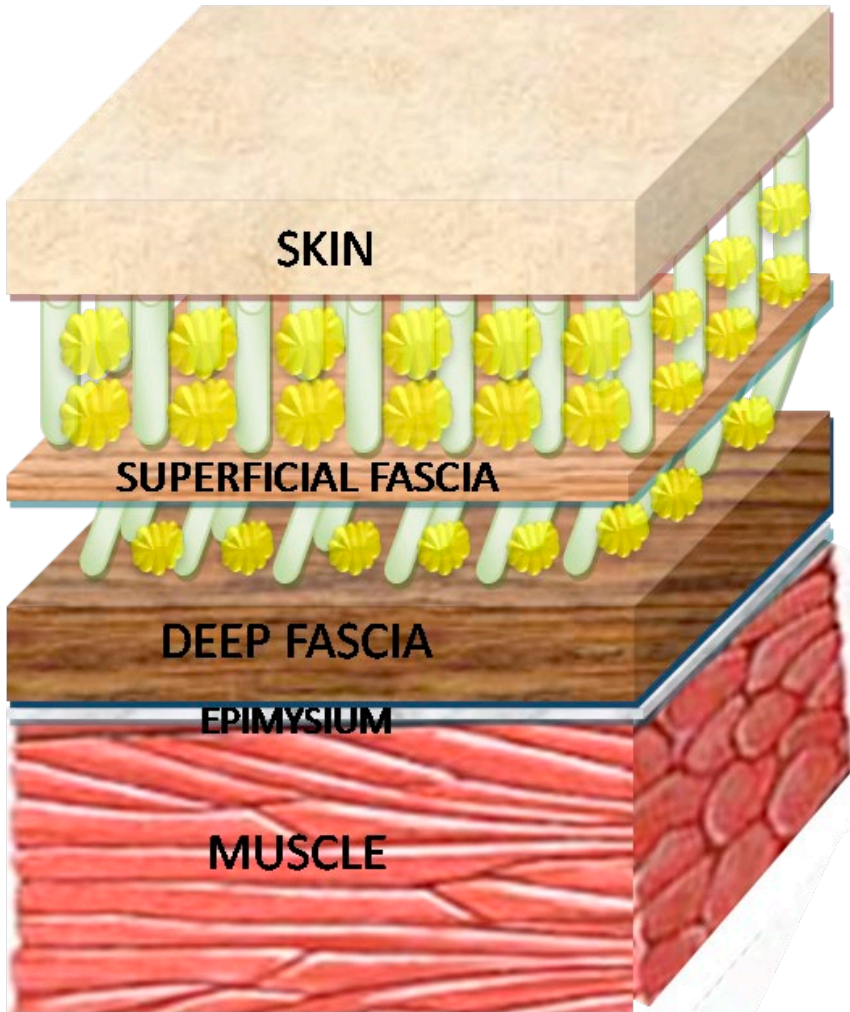
This ample list of functions partly also derives from the fact that the term 'fascia' has been applied to a large number of very different tissues, ranging from well-defined anatomical structures, such as the fascia lata, thoracolumbar fascia, plantar and palmar fasciae, and cervical and clavipectoral fasciae, to the loose packing tissues which surround all the moving structures within the body. In fact, according to the American Heritage Stedman's Medical Dictionary (2007), a fascia is "a sheet or band of fibrous connective tissue enveloping, separating, or binding together muscles, organs, and other soft structures of the body", so that only the well-defined fibrous connective tissue layers may appropriately be called "fascia", and it is consequently incorrect to use this term to mean all the connective tissue of the body. According to the above definition, from the skin to the muscular plane, there are usually three fundamental fibrous connective layers in the human body: superficial fascia, deep fascia, and epimysium, apart from all the visceral fasciae (Fig. 1). This distinction of the fascial layers is not always so clearly defined, since one or more layers sometimes disappear, or are strongly connected with each other, as in the palmar and plantar regions, where the adhesion of the superficial to the deep fascia forms a single connective layer called the palmar aponeurosis (Stecco C. *et al.*, 2009b) and plantar fascia/aponeurosis respectively (Natali *et al.*, 2010).

The aim of this review is to define the general structure of the fasciae of the human body. Better understanding of the fascial system can help both research and clinical practice, allowing easier exchange of information between different fields and authors. In addition, understanding the details of regional features of the fasciae and their dynamic anatomy may help to improve the results of all manual and physical therapies which affect the fascial system, and also of the various surgical operations which every day require to cut and suture the fasciae to create fascio-cutaneous flaps or to operate in deeper structures.

### **The superficial fascia (or membranous layer of the hypodermis)**

The superficial fascia is still an object of debate; some authors even admit the existence of a membranous layer separating the subcutaneous tissue into two sublayers; others exclude it; and yet others describe multiple such layers (Wendell-Smith, 1997). According to Abu-Hijleh *et al.* (2006), the superficial fascia can be identified

throughout the body, although its arrangement and thickness vary according to body region, body surface, and gender. It is thicker in the lower than in the upper extremities, on the posterior rather than the anterior aspect of the body, and in females more than in males. Our studies (Macchi et al., 2010; Lancerotto et al., 2011) have also revealed the constant presence of a membranous layer of connective tissue of variable thickness inside the subcutaneous tissue, dividing it into superficial (SAT) and deep adipose tissue (DAT). Retinacula connect the membranous layer (which we call superficial fascia) to the skin and to the deep fascia, forming a three-dimensional network between the fat lobules.

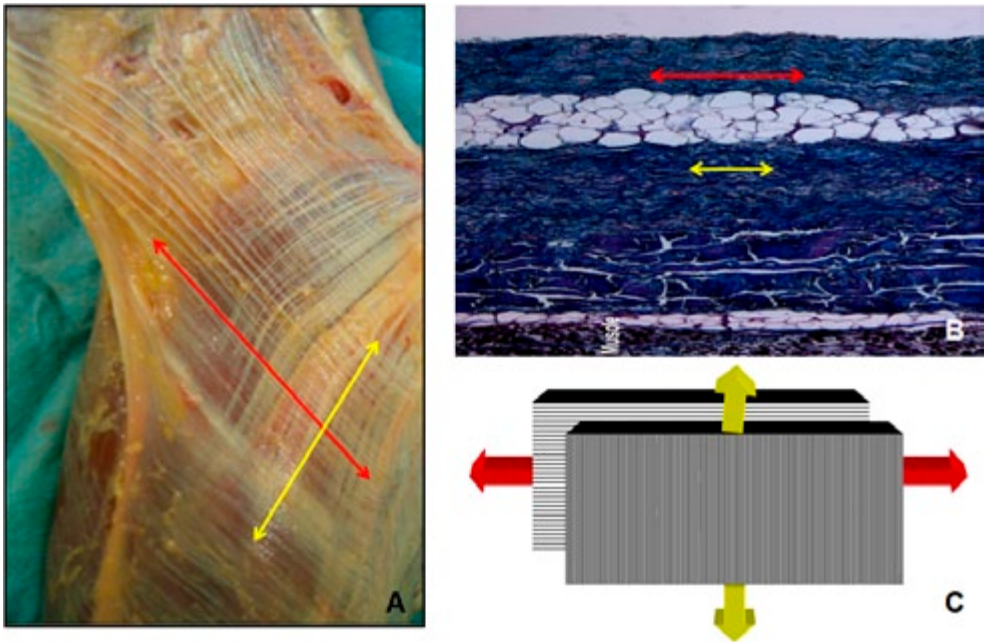


**Figure 1a** – Diagram showing basic pattern of organization of subcutaneous tissue and superficial and deep fasciae.

The two adipose layers show different histological features. The SAT is formed of large fat lobules encased between fibrous septa in a honeycomb-like structure, and presents nearly constant characteristics throughout. Its septa (*retinacula cutis superficialis*) appear to be well-defined, mostly oriented perpendicular to the surface and mechanically strong, anchoring the dermis to the deeper planes. The adipose lobules are organized in single to multiple layers, depending on fat content and the thickness of the SAT in the subject. The DAT has more oblique septa (*retinacula cutis profundus*), limited elastic properties, and a tendency toward displacement of adipose lobules. These elements may explain how the subcutaneous tissue slides over the deep fasciae.

The superficial fascia is formed of interwoven collagen fibers, loosely packed and mixed with abundant elastic fibers. Thicker in the trunk than in the limbs, in the latter it becomes thinner towards the extremities. The superficial fascia adheres to the deep fascia on bony prominences and at some ligamentous folds. In some regions, it subdivides, forming special compartments around subcutaneous major veins (Caggiati, 2000) and lymphatic vessels with fibrous septa extending to attach to the vessel wall.

Functionally, the superficial fascia may play a role in the integrity of the skin and support for subcutaneous structures, particularly veins, by ensuring their patency.



**Figure 1b** – **A**: macroscopic view of the deep fascia of the medial region of the elbow. Note fibrous bundle arrangement in overlapping layers. The main direction of the collagen fibres of the two layers are highlighted with the red and yellow arrows. **B**: histological view of the same fascia. The presence of loose connective tissue interposed between the two collagen layers permits local sliding, and so from a mechanical point of view the single layers could be considered independently. **C**: schematization of the behaviour of the deep fascia. The multilayer structure allows the deep fascia to have strong resistance to traction, even when it is exercised in different directions.

Muscular fibers can be found in the superficial fascia (Macchi et al., 2010), particularly in the neck (platysma muscle), face (superficial musculoaponeurotic system), anal region (external anal sphincter), scrotum (dartos) and areola. The superficial fascia may be viewed as the homolog of the cutaneous muscle layer (panniculus carnosus) found in other mammals. Many nerve fibers are visible inside the superficial fascia, and some authors suggest it participates to the esteroceptive system.

There are variations, according to body region and subject constitution, both in the content of adipose tissue of the superficial and deep adipose layers and in the thickness of the superficial fascia, so that using selected cadavers to demonstrate the layers may have played an important role in maintaining differing opinions among anatomists.

The superficial fascia and all the skin ligaments can easily be observed with computerized tomography (CT), magnetic resonance (MR) (particularly in T1-weighted sequences) and ultrasound. In axial images, the superficial fascia appears as a relatively hyperdense tortuous line between hypodense superficial and deep adipose tissue. In MR the superficial fascia appears as a thin continuous line, hypointense in T1- and T2-weighted sequences. No significant differences in the thickness of the superficial fascia have been shown between CT and MR (Macchi et al., 2007; Lancerotto et al., 2011; Mlosek et al. 2011).

## The deep fascia

The deep fascia is a fibrous membrane forming an intricate network which envelops and separates muscles, forms sheaths for nerves and vessels, strengthens ligaments around joints, and binds all the structures together into a firm compact mass. The deep fasciae envelop all the muscles of the body, but have different features according to region.

The deep fasciae of the limbs are commonly classified as a dense irregular connective tissue (Gerlach and Lierse, 1990; Standring et al., 2005; Young et al., 2006), although other authors describe a quite highly organized tissue, with different regional specializations (Bogduk and Macintosh, 1984; Geneser, 1986; Martini et al., 2004; Stecco C. et al., 2008a). The deep fasciae of the limbs are well-defined laminae of connective tissue with a mean thickness of 1 mm. In particular, according to our morphometric analysis, the fascia lata has a mean thickness of 944  $\mu\text{m}$  and the crural fascia 924  $\mu\text{m}$ , whereas the brachial fascia is thinner (700  $\mu\text{m}$ ) (Stecco A. et al., 2009b). They are normally easily separable from the underlying muscles, only being connected to them by some myofascial expansions, more evident around the joints. Under the deep fascia, the muscles are free to slide because of their epimysium. Loose connective tissue rich in hyaluronic acid lies between the epimysium and the deep fasciae (McCombe et al., 2001). The fasciae of the limbs are formed of two or three layers of parallel collagen fiber bundles, each layer having a mean thickness of 277  $\mu\text{m}$ . Adjacent layers show different orientations of the collagen fibers, creating an angle of 78° (Benetazzo et al., 2011). Each layer is separated from the next by a thin layer (mean thickness: 44  $\mu\text{m}$ ) of loose connective tissue which allows the various layers to glide over each other, so that, from a mechanical point of view, each layer may be considered independent and has a specific influence on the function of

the tissue. In addition as each single layer of the collagen fibers runs in one direction, the response of a layer differs if traction follows the direction of the collagen fibers or another direction but, together, all the layers have strong resistance to traction, even when exercised in different directions (Stecco C. *et al.*, 2009a; Natali *et al.*, 2010). The capacity of the various collagen layers to slide over each other may change in cases of overuse syndrome, trauma or surgery, all possible causes of myofascial pathologies.

Many researchers have found that some muscles have fascial insertions (Testut and Jacob, 1905; Chiarugi, 1975; Platzer, 1978; Huijing and Baan, 2001a,b; Standing *et al.*, 2005; Moore and Dalley, 2009; Stecco *et al.*, 2008b). The most famous expansion is certainly the *lacertus fibrosus*, an aponeurosis which originates from the biceps tendon and then merges with the antebrachial fascia. According to Marshall (2001), all fascial insertions provide an excellent illustration of how the thickness and strength of fasciae precisely mirror the forces generated by muscular action. Indeed, when these muscles contract, they not only move the bones but, thanks to the fascial expansions, they also stretch the deep fascia. The connections between muscles and deep fasciae are constant and have precise organization (Stecco C. *et al.*, 2008b; Stecco A. *et al.*, 2009a). So, according to the various movements, specific muscles are activated, stretching selective portions of the deep fascia by the action of specific myofascial expansions. This organization can be observed along all the limbs, indicating that the fasciae act like a transmission belt between two adjacent joints and also between synergic muscle groups, guaranteeing perceptive and directional continuity and probably representing the anatomical basis of myokinetic chains (Stecco L., 2004). Only the different, autonomous fibrous planes inside the deep fasciae allow the muscles to contract without opposing the action of other muscles inserted into the same fascia. If, due to trauma, surgery or overuse syndromes, the sliding system inside the aponeurotic fasciae changes, the contraction of a muscle probably also influences the insertions of the other muscles. The creation of an adhesion point also involves the formation of new lines of force inside the fasciae (Stecco A. *et al.*, 2011).

Several studies have reported that the deep fasciae of the limbs are under basal tension, perhaps due to stretching of the underlying muscles by muscular or tendinous insertions (Stecco C. *et al.*, 2008b, 2010a) or to the action of myofibroblasts which, according to Schleip *et al.* (2006, 2007), can be recognized inside the deep fasciae. Langevin *et al.* (2006) demonstrated that fibroblasts can change cell signaling, gene expression and cell-matrix adhesion according to mechanical load. Myofibroblasts certainly occur in Dupuytren's contracture, in congenital fascial dystrophy, "frozen shoulder", scars and other fascial diseases (Gabbiani, 2007; Benjamin, 2009) and probably cause the increase in fascial basal tension, for example, in chronic compartmental syndrome (McDonald and Bearcroft, 2010), influencing the biomechanics of the myofascial system.

The deep fasciae are reinforced around the joints by the retinacula, classically considered as isolated elements acting as pulleys and keeping tendons close to underlying bones during movements (Vesalio, 1543). Recent studies have shown that they are reinforcements of the deep fasciae and not separable from them (Abu-Hijleh and Harris, 2007; Stecco C. *et al.*, 2010b). The retinacula are considered important elements for joint stability (Umidon, 1963; Leardini and O'Connor, 2002), but they also play an important role in proprioception (Viladot *et al.*, 1984; Marconetto and Parino, 2003;

Pisani, 2004) and peripheral motor coordination (Stecco L., 2004). According to Stecco C. et al. (2010a,b), the retinacula are formed by the action of the muscles in the deep fasciae, thanks to myofascial expansions, which may create different types of lines of force inside the deep fasciae, particularly along the main axis of the limb or obliquely to it. Recent studies highlight the possible role of the retinacula in the alteration of proprioception and in periarticular pain. In particular, patellofemoral malalignment (Sanchis-Alfonso and Rosello-Sastre, 2000) and functional ankle instability (Stecco A. et al., 2008, 2011) may sometimes be associated with asymmetric tension/thickness or rupture of the retinacula.

Histological analysis shows that collagen volume is about 18% and elastic fiber volume less than 1% in the deep fasciae of the lower limb and slightly more in those of the upper limb, where they form an irregular mesh (Benetazzo et al, 2011). So, since the deep fasciae of the limbs are not very elastic, they can transmit perfectly the tensions created by the muscles even at great distances, passing over the various joints and segments (Maas and Sandercock, 2010; Purslow, 2010, Yucesoy, 2010). According to Klein et al. (1999), wrist and ankle retinacula also form three distinct layers: an inner sliding layer, with hyaluronic acid-secreting cells; a thick middle layer containing collagen bundles, fibroblasts, and interspersed elastin fibers; and an outer layer consisting of loose connective tissue containing vascular channels. A recent work (Stecco C. et al., 2011) has verified that also the deep fasciae of limbs contain hyaluronic acid-secreting cells. So, they could be considered as a joint capsule, providing both a smooth gliding surface and mechanical resistance to the transmission of force at a distance.

In the last few years, several studies have demonstrated the presence of many free, encapsulated nerve endings, particularly Ruffini and Pacini corpuscles, inside the deep fasciae (Stilwell, 1957; Yahia et al., 1992; Stecco C. et al., 2007), although differences exist according to the different regions; retinacula seem to be the most highly innervated structures. Analysis of the relationship between these nerve endings and the surrounding fibrous tissue shows that the corpuscle capsules and free nerve endings are closely connected to the surrounding collagen fibers, indicating that these nerve endings may be stretched, and thus activated, every time the surrounding deep fascia is stretched.

In the trunk, the same structure of the deep fasciae of the limbs can be recognized in the thoracolumbar fascia, rectal sheet and neck fasciae; the pectoral fascia and the fasciae of the deltoid, trapezius and gluteus maximus muscles show completely different features. This particularity is probably due to the different embryological development of these muscles and fasciae. Indeed, according to Sato and Hashimoto (1984) and Mihalache et al. (1996), the superficial layer of the muscles of the trunk develops inside the superficial layer of the fasciae, remaining firmly adherent to them thanks to many intramuscular septa. Many muscular fibers also originate from the inner aspect of the surrounding fascia. Our dissections also confirmed that these muscles are comprised within the superficial lamina of the deep fasciae and are not separable from them (Stecco A. et al., 2009b). In these muscles, no epimysium is recognizable between muscles and deep fasciae.

From a macroscopic point of view, the deep fasciae of the trunk are composed of very thin connective tissue layers with a mean thickness of 156  $\mu\text{m}$ , strongly adherent to the muscles. Histologically, they appear as thin laminae of collagen fibers, with

structure similar to a single layer of limb fasciae. Many elastic fibers (~15%) are present, forming an irregular mesh. Nerve fibers are found in all these fasciae, particularly numerous around vessels, but also distributed homogeneously throughout their fibrous components (Stecco A. *et al.*, 2009c).

From a mechanical point of view, the close relationship between fasciae and trunk muscles clearly implies that the role of the fasciae in movements cannot be separated from the actions of the muscles and that, every time a muscle contracts, selective spatial stretching of the corresponding fascia must also occur. For example, various portions of the fibers of the pectoralis major are activated according to the degree of shoulder joint movements, and thus different portions of the corresponding fascia are stretched. Consequently, specific patterns of intrafascial receptors are activated, according to the range of motion and also to the specific direction of movement. The deep fasciae of the trunk may therefore be presumed to play a proprioceptive role.

The deep fasciae of the limbs are clearly visible with CT, MR (particularly in T1-weighted sequences) and ultrasound imaging. In MR T1-weighted sequences, the aponeurotic fasciae of the limbs appear as low signal intensity lines, with a mean thickness of 0.9 mm, and the retinacula are clearly observable, even with their bone insertions (Numkarunarunrote *et al.*, 2007). The deep fascia was easily evaluable with the ultrasound. It appeared as a linear hyperechoic layer. In some regions also the fascial sublayers were easily recognizable. In particular the dense collagen layers within the fascia were represented by the white layers, while the layers of loose connective tissue were seen as the black layers. Some recent studies have reported possible alterations of the retinacula (Demondion *et al.*, 2010), particularly in ankle sprain outcomes (Stecco A. *et al.*, 2011), in that they sometimes show more intense signal ascribable to local edema and inflammation; in patellofemoral malalignment, the medial and lateral retinacula of the knee show different thicknesses and/or degrees of tension. Despite these data, the fascial system is usually not analysed, by either radiologists or surgeons, and only a few papers report the visualization of possible alterations of the fasciae.

## References

- Abu-Hijleh M.F., Roshier A.L., Al-Shboul Q., Dharap A.S., Harris P.F. (2006) The membranous layer of superficial fascia: evidence for its widespread distribution in the body. *Surg. Radiol. Anat.* 28: 606-619.
- Abu-Hijleh M.F., Harris P.F. (2007) Deep fascia on the dorsum of the ankle and foot: extensor retinacula revisited. *Clin. Anat.* 20: 186-195.
- American Heritage Medical Dictionary (2007) Houghton Mifflin Company.
- Benetazzo L., Bizzego A., De Caro R., Frigo G., Guidolin D., Stecco C. (2011) 3D reconstruction of the crural and thoracolumbar fasciae. *Surg. Radiol. Anat.* 33: 855-862.
- Benjamin M., Kaiser E., Milz S. (2008) Structure-function relationships in tendons: a review. *J. Anat.* 212: 211-228.
- Benjamin M. (2009) The fascia of the limbs and back – a review. *J. Anat.* 214: 1-18.
- Bogduk N., Macintosh J.E. (1984) The applied anatomy of the thoracolumbar fascia. *Spine* 9: 164-170.



- Caggiati A. (2000) Fascial relations and structure of the tributaries of the saphenous veins. *Surg. Radiol. Anat.* 22: 191-196.
- Chiarugi G. (1975) *Istituzioni di Anatomia dell'Uomo*, vol 1. Società Editrice Libreria, Milano.
- Demondion X., Canella C., Moraux A., Cohen M., Bry R., Cotten A. (2010) Retinacular disorders of the ankle and foot. *Semin. Musculoskelet. Radiol.* 14: 281-291.
- Gabbiani G. (2007) Evolution and clinical implications of the myofibroblast concept. In: Findley T.W., Schleip R.: *Fascia Research - Basic Science and Implications for Conventional and Complementary Health Care*; Urban and Fischer, Munich. Pp. 56-60.
- Geneser F. (1986) *Textbook of Histology*. Munksgaard Lea and Febiger, Copenhagen.
- Gerlach U.J., Lieser W. (1990) Functional construction of the superficial and deep fascia system of the lower limb in man. *Acta Anat.* 139: 11-25.
- Huijing P.A., Baan G.C., Rebel G.T. (1998) Non-myotendinous force transmission in rat extensor digitorum longus muscle. *J. Exp. Biol.* 201: 683-691.
- Huijing P.A. (1999) Muscular force transmission: a unified, dual or multiple system? A review and some explorative experimental results. *Arch. Physiol. Biochem.* 107: 292-311.
- Huijing P.A., Baan G.C. (2001a) Extramuscular myofascial force transmission within the rat anterior tibial compartment: proximo-distal differences in muscle force. *Acta Physiol. Scand.* 173: 297-311.
- Huijing P.A., Baan G.C. (2001b) Myofascial force transmission causes interaction between adjacent muscles and connective tissue: effects of blunt dissection and compartmental fasciotomy on length force characteristics of rat extensor digitorum longus muscle. *Arch. Physiol. Biochem.* 109: 97-109.
- Huijing P.A., Maas H., Baan G.C. (2003) Compartmental fasciotomy and isolating a muscle from neighboring muscles interfere with myofascial force transmission within the rat anterior crural compartment. *J. Morphol.* 256: 306-321.
- Kassolik K., Jaskólska A., Kisiel-Sajewicz K., Marusiak J., Kawczyński A., Jaskólski A. (2009) Tensegrity principle in massage demonstrated by electro- and mechanomyography. *J. Bodyw. Mov. Ther.* 13: 164-170.
- Klein D.M., Katzman B.M., Mesa J.A., Lipton J.F., Caligiuri D.A. (1999) Histology of the extensor retinaculum of the wrist and the ankle. *J. Hand Surg. Am.* 24: 799-802.
- Lancerotto L., Stecco C., Macchi V., Porzionato A., Stecco A., De Caro R. (2011) Layers of the abdominal wall: anatomical investigation of subcutaneous tissue and superficial fascia. *Surg. Radiol. Anat.* 33: 835-842.
- Langevin H.M., Churchill D.L., Cipolla M.J. (2001) Mechanical signalling through connective tissue: a mechanism for therapeutic effect of acupuncture. *FASEB J.* 15: 2275-2282.
- Langevin H.M. (2006a) Connective tissue: a body-wide signalling network? *Med. Hypotheses* 66: 1074-1077.
- Langevin H.M., Bouffard N.A., Badger G.J., Churchill D.L., Howe A.K. (2006b) Subcutaneous tissue fibroblast cytoskeletal remodeling induced by acupuncture: evidence for a mechanotransduction-based mechanism. *J. Cell. Physiol.* 207: 767-774.
- Leardini A., O'Connor J.J. (2002) A model for lever-arm length calculation of the flexor and extensor muscles at the ankle. *Gait Posture* 15: 220-229.

- Lindsay M. (2008) *Fascia: clinical applications for health and human performance*. Delmar Cengage Learning, New York.
- Maas H., Sandercock T.G. (2010) Force transmission between synergistic skeletal muscles through connective tissue linkages. *J. Biomed. Biotechnol.* 12: 575672.
- Macchi V., Tiengo C., Porzionato A., Stecco C., Galli S., Vigato E., Azzena B., Parenti A., De Caro R. (2007) Anatomico-radiological study of the superficial musculo-aponeurotic system of the face. *Ital. J. Anat. Embryol.* 112: 247-253.
- Macchi V., Tiengo C., Porzionato A., Stecco C., Vigato E., Parenti A., Azzena B., Weiglein A., Mazzoleni F., De Caro R. (2010) Histotopographic study of the fibroadipose connective cheek system. *Cells Tissues Organs.* 191: 47-56.
- Marconetto M., Parino E. (2003) Il retinacolo inferiore degli estensori: anatomia normale, anatomia funzionale, utilizzo nelle plastiche legamentose. *Chir. Piede* 27: 101-105.
- Marshall R. (2001) *Living anatomy: structure as the mirror of function*. Melbourne University Press, Melbourne.
- Martini F.H., Timmons M.J., Tallitsch R.B. (2004) *Anatomia Umana*. 2<sup>nd</sup> ed. Edizioni Scientifiche ed Universitarie, Napoli.
- McCombe D., Brown T., Slavin J., Morrison W.A. (2001) The histochemical structure of the deep fascia and its structural response to surgery. *J. Hand Surg. Br.* 26: 89-97.
- McDonald S., Bearcroft P. (2010) Compartment syndromes. *Semin. Musculoskelet. Radiol.* 14: 236-244.
- Mihalache G., Indrei A., Taranu T. (1996) The anterolateral structures of the neck and trunk. *Rev. Med. Chir. Soc. Med. Nat. Iasi* 100: 69-74.
- Mlosek R.K., Dębowska R.M., Lewandowski M., Malinowska S., Nowicki A., Eris I. (2011) Imaging of the skin and subcutaneous tissue using classical and high-frequency ultrasonographies in anti-cellulite therapy. *Skin Res. Technol.* 17: 461-468.
- Moore K.L., Dalley A.D. (2009) *Clinically oriented Anatomy*. 5th Ed. Lippincott Williams and Wilkins, Philadelphia.
- Myers T.W. (1987) *Anatomy Trains: myofascial meridians for manual and movement therapists*. Churchill Livingstone, Edinburgh.
- Numkarunarunrote N., Malik A., Aguiar R.O., Trudell D.J., Resnick D. (2007) Retinacula of the foot and ankle: MRI with anatomic correlation in cadavers. *Am. J. Roentgenol.* 188: W348-W354.
- Natali A.N., Pavan P.G., Stecco C. (2010) A constitutive model for the mechanical characterization of the plantar fascia. *Connect. Tissue Res.* 51: 337-346.
- Pisani G. (2004) *Trattato di chirurgia del piede*. Minerva medica, Torino.
- Platzer W. (1978) Locomotor system. In: Kahle W., Leonhardt H., Platzer W. *Color Atlas and Textbook of Human Anatomy*. 1<sup>st</sup> edn. Thieme, Stuttgart.
- Purslow P.P. (2010) Muscle fascia and force transmission. *J. Bodyw. Mov. Ther.* 14: 411-417.
- Sanchis-Alfonso V., Rosello-Sastre E. (2000) Immunohistochemical analysis for neural markers of the lateral retinaculum in patients with isolated symptomatic patellofemoral malalignment. A neuroanatomic basis for anterior knee pain in the active young patient. *Am. J. Sports Med.* 28: 725-731.
- Sato T., Hashimoto M. (1984) Morphological analysis of the fascial lamination of the trunk. *Bull. Tokyo Med. Dent. Univ.* 31: 21-32.

- Schleip R., Naylor I., Ursu D., Melzer W., Zorn A., Wilke H.J., Lehmann-Horn F., Klingler W. (2006) Passive muscle stiffness may be influenced by active contractility of intramuscular connective tissue. *Med. Hypotheses* 66: 66-71.
- Schleip R., Kingler W., Lehmann-Horn F. (2007) Fascia is able to contract in a smooth muscle-like manner and thereby influence musculoskeletal mechanics. In *Fascia Research. Basic Science and Implications for Conventional and Complementary Health Care* (eds. Findley T.W., Schleip R.). Urban and Fischer, Munich.
- Schleip R. (2009) Foreword. In: *Fascial Manipulation, practical part* (Stecco L., Stecco C.). Piccin, Padova.
- Standring S., Ellis H., Healy J., Johnson D., Williams A. (2005) *Gray's Anatomy*, 39<sup>th</sup> ed, Churchill Livingstone, London.
- Stecco A., Masiero S., Macchi V., Porzionato A., Stecco C., De Caro R., Ferraro C. (2008) Le basi anatomiche del danno propriocettivo negli esiti di distorsione di caviglia. *Eur. Med. Phys.* 44: S1-S5.
- Stecco A., Macchi V., Stecco C., Porzionato A., Day J.A., Delmas V., De Caro R. (2009a) Anatomical study of myofascial continuity in the anterior region of the upper limb. *J. Bodyw. Mov. Ther.* 13: 53-62.
- Stecco A., Macchi V., Masiero S., Porzionato A., Tiengo C., Stecco C., Delmas V., De Caro R. (2009b) Pectoral and femoral fasciae: common aspects and regional specializations. *Surg. Radiol. Anat.* 31: 35-42.
- Stecco A., Masiero S., Macchi V., Stecco C., Porzionato A., De Caro R. (2009c) The pectoral fascia: anatomical and histological study. *J. Bodyw. Mov. Ther.* 13: 255-261.
- Stecco A., Stecco C., Macchi V., Porzionato A., Ferraro C., Masiero S., De Caro R. (2011) RMI study and clinical correlations of ankle retinacula damage and outcomes of ankle sprain. *Surg. Radiol. Anat.* 33: 881-890.
- Stecco C., Gagey O., Belloni A., Pozzuoli A., Porzionato A., Macchi V., Aldegheri R., De Caro R., Delmas V. (2007) Anatomy of the deep fascia of the upper limb. Second part: study of innervation. *Morphologie* 91: 38-43.
- Stecco C., Porzionato A., Lancerotto L., Stecco A., Macchi V., Day J.A., De Caro R. (2008a) Histological study of the deep fasciae of the limbs. *J. Bodyw. Mov. Ther.* 12: 225-230.
- Stecco C., Porzionato A., Macchi V., Stecco A., Vigato E., Parenti A., Delmas V., Aldegheri R., De Caro R. (2008b) The expansions of the pectoral girdle muscles onto the brachial fascia: morphological aspects and spatial disposition. *Cells Tissues Organs* 188: 320-329.
- Stecco C., Pavan P.G., Porzionato A., Macchi V., Lancerotto L., Carniel E.L., Natali A.N., De Caro R. (2009a) Mechanics of crural fascia: from anatomy to constitutive modelling. *Surg. Radiol. Anat.* 31: 523-529.
- Stecco C., Lancerotto L., Porzionato A., Macchi V., Tiengo C., Parenti A., Sanudo J.R., De Caro R. (2009b) The palmaris longus muscle and its relations with the antebrachial fascia and the palmar aponeurosis. *Clin. Anat.* 22: 221-229.
- Stecco C., Macchi V., Porzionato A., Morra A., Delmas V., De Caro R. (2010a) The ankle retinacula: morphological evidence of the proprioceptive role of the fascial system. *Cells Tissues Organs* 192: 200-210.
- Stecco C., Macchi V., Lancerotto L., Tiengo C., Porzionato A., De Caro R. (2010b) Comparison of transverse carpal ligament and flexor retinaculum terminology for the wrist. *J. Hand Surg. Am.* 35: 746-753.

- Stecco C., Stern R., Porzionato A., Macchi V., Masiero S., Stecco A., De Caro R. (2011) Hyaluronan within fascia in the etiology of myofascial pain. *Surg. Radiol. Anat.* 33: 891-896.
- Stecco L. (1996) *La manipolazione neuroconnettivale*, Marrapese, Roma.
- Stecco L. (2004) *Fascial Manipulation for Musculoskeletal Pain*. Piccin, Padova.
- Stecco L., Stecco C. (2009) *Fascial Manipulation: Practical Part*. Piccin, Padova.
- Stilwell D. (1954) Regional variations in the innervation of deep fasciae and aponeuroses. *Anat. Rec.* 23: 94-104.
- Testut J.L., Jacob O. (1905) *Précis d'anatomie topographique avec applications medico-chirurgicales*. Gaston Doin et Cie, Paris.
- Umidon M. (1963) Architecture, topography and morphogenesis of the peroneal retinacula and the lateral annular ligament of the tarsus in man. *Chir. Organi Mov.* 52: 305-317.
- Vesalio A. (1543) *De Humani Corporis Fabrica*. Ex officina Joannis Oporini, Basel.
- Viladot A., Lorenzo J.C., Salazar J., Rodríguez A. (1984) The subtalar joint: embryology and morphology. *Foot Ankle* 5: 54-66.
- Vleeming A., Pool-Goudzwaard A.L., Stoecart R., van Wingerden J.P., Snijders C.J. (1995) The posterior layer of the thoracolumbar fascia. Its function in load transfer from spine to legs. *Spine* 20: 753-758.
- Vleeming A., Pool-Goudzwaard A.L., Hammudoghlu D., Stoecart R., Snijders C.J., Mens J.M. (1996) The function of the long dorsal sacroiliac ligament: its implication for understanding low back pain. *Spine* 21: 556-562.
- Yahia H., Rhalmi S., Newman N. (1992) Sensory innervation of human thoracolumbar fascia, an immunohistochemical study. *Acta Orthop. Scand.* 63:195-197.
- Young B., Lowe J.S., Stevens A., Heath J.W. (2006) *Wheater's functional histology. A text and Colour Atlas*. 5th ed. Elsevier ed., Philadelphia.
- Yucesoy C.A., Maas H., Koopman B., Grootenboer H.J., Huijing P.A. (2006) Mechanisms causing effects of muscle position on proximo-distal muscle force differences in extra-muscular myofascial force transmission. *Med. Engr. Physics* 28: 214-226.
- Yucesoy C.A. (2010) Epimuscular myofascial force transmission implies novel principles for muscular mechanics. *Exerc. Sport Sci. Rev.* 38: 128-134.
- Wendell-Smith C.P. (1997) Fascia: an illustrative problem in international terminology. *Surg. Radiol. Anat.* 5: 273-277.
- Wood Jones F. (1944) *Structure and Function as Seen in the Foot*. Baillière, Tindall and Cox, London.