

Research Article: Basic and Applied Anatomy

Accessory muscles around the superior radioulnar joint: a morphological study

George K. Paraskevas* and Orestis Ioannidis

Department of Anatomy, Medical School, Aristotle University of Thessaloniki, Greece

Submitted October 2, 2010; accepted November 10, 2010

Summary

During anatomical dissections on 36 human elbow joints, we observed the presence of three muscles around the superior radioulnar joint usually neglected by the classical anatomical literature, the lateral tensor muscle of the annular ligament (with an incidence of 16.6%), the medial tensor muscle of the annular ligament (11.1%) and the accessory supinator muscle (16.6%). We could not establish any association between the subject handedness and the sidedness of these aberrant muscles, neither we found a predominance in sidedness or in gender. Furthermore, we did not notice any significant predominance related to the occupation and specifically to heavy labor occupations. On the contrary we found these muscles to be more common in non-laborers, which supports the assumption that these variants constitute rather genetic than epigenetic traits. The knowledge of such anatomical variants facilitate the surgeon operating in the elbow region to better interpret supernumerary muscular bundles in the operative field.

Key words

Accessory muscles, annular ligament, elbow joint, superior radioulnar joint, supinator muscle.

Introduction

A variety in the muscles located in the elbow region is reported in the anatomical literature, such as the presence of epitrochleoanconeus muscle (Toldt, 1928), a variability in teres pronator (Adachi and Hasebe, 1928) and palmaris longus (Paraskevas et al., 2008), or a duplication of extensor carpi radialis brevis (Calori, 1868). Nevertheless, very few data have been provided concerning the aberrant muscles situated in the deepest portion of the elbow fossa, in close proximity to the superior radioulnar joint. Such muscles are the lateral tensor muscle of the annular ligament, the medial tensor muscle of annular ligament and the accessory supinator muscle, which have been described comprehensively by Grüber (1865). A more detailed description of these muscles has been made by Hast and Perkins (1986).

The objective of this study is to provide more precise information regarding the morphology and incidence of these small muscles as well as their possible correlation to gender, sidedness, subject handedness and occupation on heavy manual work, in order to familiarize the surgeon operating in the elbow region with anatomical variants of such elements.

* Corresponding author. Phone: +30 2310 999330, E-mail: g_paraskevas@yahoo.gr.

Materials and methods

For this study, 36 formalin-fixed elbow joints, belonging to 18 cadavers (9 males and 9 females) used for educational purposes, were utilized. Written informed consent was obtained from the cadavers' next of kin for the publication of the article and accompanying images. We studied extensively the morphology and the possible presence of supernumerary muscular fascicles in the area of superior radioulnar joint. In order to achieve this goal, we dissected carefully the anterior and lateral muscles of the forearm in the region of the cubital fossa, paying special attention to the annular and the lateral collateral ligaments of the elbow joint as well as to the supinator muscle. Additionally, we classified our specimens according to the occupation when alive, into laborers and non-laborers, on the basis of data derived from their medical history. It is worth mentioning that five male cadavers were from laborers in heavy manual work conditions during their life. Moreover, the handedness of the specimens was documented in their medical history. Specifically, 12 specimens were right handed and 6 specimens were left handed.

Two independent investigators recorded the presence of distinct accessory muscular bundles near the proximal end of the radius, as anatomical structures different from the classically recorded muscles of the region. The contradiction between the two investigators, regarding these accessory muscles' definition and identification, was less than 5%. No cadaver showed signs of pathological conditions, trauma or previous surgical procedures in their upper limbs. Comparisons between various parameters were analyzed using the chi-square test. The level of significance was set at $p < 0.05$.

Results

We noticed the presence of three relatively unknown muscular fascicles around the annular ligament of the elbow joint, as follows. 1) Lateral tensor muscle of the annular ligament. It originated from the superior portion of the supinator ridge of the ulna, proceeded circularly around the lateral aspect of the radial neck and finally inserted into the anterior aspect of the annular ligament and the elbow joint capsule just proximal to the annular ligament (Fig. 1). That muscle was present in three out of 18 cadavers, thus had a frequency of 16.6%. 2) Medial tensor muscle of the annular ligament. It arose from the anterior aspect of the annular ligament and the adjacent part of elbow capsular ligament and proceeded around the neck of the radius to insert into the medial surface of the radial neck just above the bicipital tuberosity (Fig. 1). It was identified in two out of 18 cadavers, thus had a frequency of 11.1%. 3) Accessory supinator muscle. That muscle originated from the lateral border of the ulnar tuberosity. It was directed laterally and inferiorly and finally inserted just above the bicipital tuberosity (Fig. 2). The muscle was present in three out of 18 cadavers, thus had a frequency of 16.6%.

There was neither predominance of gender ($p = 0.443$) nor of sidedness ($p = 1$) on the aberrant muscles frequency (Tab. 1). We concluded that the presence of these small muscles was statistically more common in non laborers than in laborers ($p = 0.043$) (Tab. 1). Furthermore, we could not find any statistically significant association between the subject handedness and the sidedness of the aberrant muscles ($p = 0.096$) (Tab. 2).

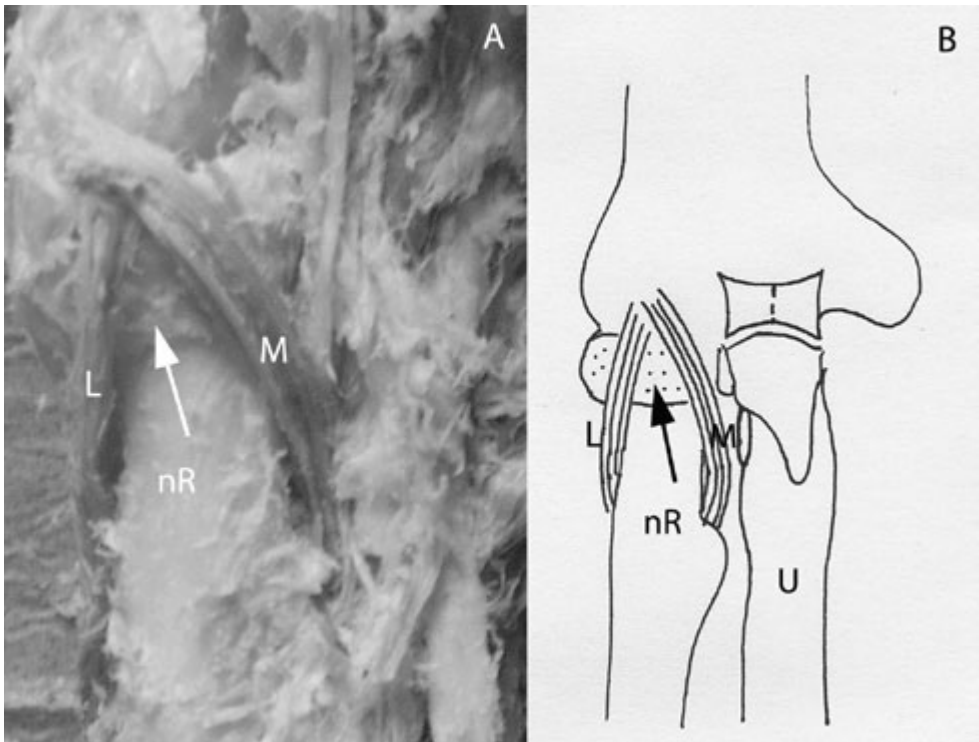


Figure 1 – Demonstration (A) and scheme (B) of the lateral and medial tensor muscles of the annular ligament in a cadaveric right elbow joint. L: lateral tensor muscle of the annular ligament, M: medial tensor muscle of the annular ligament, Arrow: annular ligament, nR: neck of radius, U: ulna.

Discussion

Very few reports exist in the anatomical literature regarding the presence of aberrant muscles located in the deep portion of the elbow region around the superior radioulnar joint. The first comprehensive description of supernumerary muscular fascicles around the superior radioulnar joint was made by Grüber (1865), who described these muscular fascicles as supinator muscle variants, naming them “musculi tensores proprii ligamenti radii”. Sklavounos (1926) reported that a muscular bundle of the supinator muscle inserts into the annular ligament of the radius or the bicipital tuberosity. Frohse and Frankel (1908) referred to these muscles with the note that they did not know whether such muscles constitute variants or usual anatomical findings. Savas (1961) claimed that sometimes the supinator muscle receives a muscular bundle originated from the annular ligament, called the “tensor muscle of annular ligament”. Basmajian (1971) stated that a portion of the supinator muscle constantly arises from the annular ligament of the radius, thus constituting likely the accessory supinator muscle studied in the present work. Bergman et al. (1988), in their significant comprehensive anatomical textbook “Compendium of human anatomic variation”, displayed the so

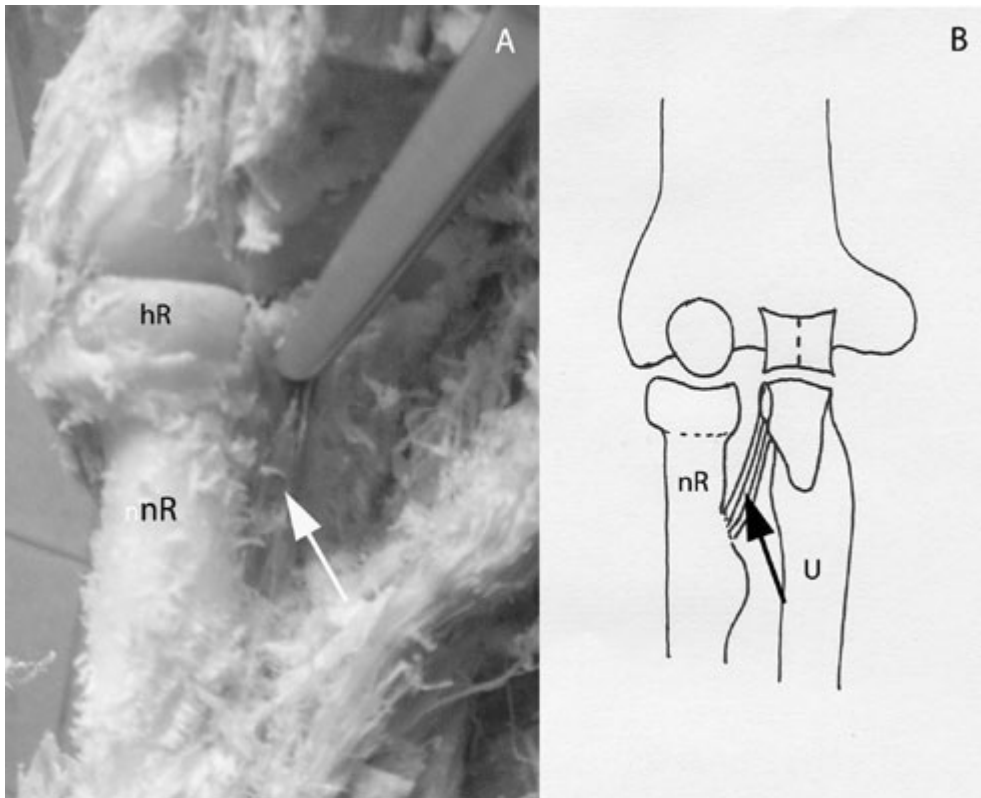


Figure 2 – Demonstration (A) and scheme (B) of the accessory supinator muscle. hR: head of radius, nR: neck of radius, Arrow: accessory supinator muscle, U: ulna.

called “anterior and posterior tensor muscles of the annular ligament” as described by Grüber in 1865. Other authors referred that the supinator muscle is subject to frequent variation by which small parts of it often receive individual names (Williams et al., 1989). Bozkurt et al. (2005), in a cadaveric study, observed that the tendinous superficial portion of supinator muscle was fused with the annular ligament, thus resembling the medial tensor muscle of the annular ligament.

The most important contribution to the study of these muscles has been made by Hast and Perkins (1986), who considered these muscles as constantly appearing anatomical elements neglected in the classical anatomical textbooks. Their study displayed a muscle on the anterolateral side of the annular ligament, a muscle on the anteromedial side of the annular ligament and a muscle located just posterior to the biceps tendon, which were called “lateral and medial tensor muscle of the annular ligament of radius” and “accessory supinator muscle”, respectively. Specifically these authors found that the average length of the “lateral tensor muscle” was 27 mm, the average width 6 mm and the average thickness 1.4 mm, whilst the incidence was 68%. The “medial tensor muscle” was found with an average of 31 mm length, 8 mm

Table 1 – Incidence of the accessory muscles correlated with the superior radioulnar joint. The incidence rates are indicated in brackets.

	Males	Side	Females	Side	Ratio to total number of cadavers	Ratio to total number of elbow joints	Laborers
Lateral tensor muscle of the annular ligament	2/9 (22.2%)	1 right 1 left	1/9 (11.1%)	1 left	3/18 (16.6%)	3/36 (8.3%)	0/5 (0%)
Medial tensor muscle of the annular ligament	1/9 (11.1%)	1 left	1/9 (11.1%)	1 right	2/18 (11.1%)	2/36 (5.5%)	0/5 (0%)
Accessory supinator muscle	3/9 (33.3%)	2 right 1 left	1/9 (11.1%)	1 left	3/18 (16.6%)	4/36 (11.1%)	1/5 (20%)

Table 2 – Correlation of subject handedness and accessory muscle sidedness.

Handedness	Sidedness	
	Right	Left
Right	1	4
Left	3	1

width and 1.8 mm thickness, its incidence being 20%. The “accessory supinator muscle” measured an average of 29 mm length, 8 mm width and 1.4 mm thickness. It was found in 39% cases (Hast and Perkins, 1986).

On the contrary, we found lower incidences concerning these accessory muscles, that are 16.6%, 11.1% and 16.6% for the lateral tensor, the medial tensor muscle of the annular ligament of the radius and the accessory supinator muscle, respectively. This may be possibly related to the smaller sample of cadaveric specimens, the different technique of cadavers’ preservation and the different method of elbow joint preparation as well. In our study there was neither predominance of the gender, nor of the sidedness on the aberrant muscles incidence. We were not able to find any significant association between sidedness of aberrant muscles and subject handedness. Moreover, we concluded that the presence of these aberrant muscles was statistically more common in non-laborers than in laborers. The two latter remarks support the assumption that these muscles constitute rather genetic than epigenetic traits.

Hast and Perkins (1986) suggested, without conducting any prior electrophysiologic study, that the lateral tensor muscle tracts the annular ligament laterally during supination, while the medial tensor muscle tracts the same ligament medially during supination as well, whilst accessory supinator muscle facilitates supination. Taking into consideration Martin's (1959) observation that the anterior part of the annular ligament is under tension during supination and that such an effect depends upon the shape of the head and neck of the radius, we assume that these accessory muscles alter the tension of the anterior part of the annular ligament with respect to various forms of head and neck of the radius. It remains to search further for the likely co-existence of these muscles with specific types of radius head and neck shapes.

Certainly further investigation should be done on the basis of kinematic and electromyographic studies on living subjects, to come to conclusion regarding the precise action of such muscles. The accurate awareness of these small muscles should be potentially helpful for surgeons dealing with the elbow region, as well for radiologists during interpretation of MRI findings concerning the area of superior radioulnar joint.

Declaration of interest. The authors report no conflicts of interest. The authors alone are responsible for the content and writing of the paper.

References

- Adachi B., Hasebe K. (1928) *Das Arteriensystem der Japaner*. Kaiserlich-japanische Universität zu Kyoto in commission by Maruzen Co, Kyoto and Tokyo.
- Basmajian J.V. (1971) *Grant's Method of Anatomy*. 8th ed. Williams and Wilkins Co, Baltimore, p. 148.
- Bergman R.A., Thompson S.A., Afifi A.K., Saaseh F.A. (1988) *Compendium of Human Anatomic Variation: Text, Atlas and World Literature*. Urban and Schwarzenberg, Munich, p. 296.
- Bozkurt M., Acar H.I., Apaydin N., Leblebicioglu G., Elhan A., Tekdemir I., Tonuk E. (2005) The annular ligament: an anatomical study. *Am. J. Sports Med.* 33: 114-118.
- Calori L. (1868) *Delle anatomie piu importanti di ossa, vasi, nervi e muscoli occorse nell'ultimo biennio facendo anatomia del corpo umano*. *Mem. R. Acad. Sci. Instit. Bologna.* 8: 417-482.
- Frohse F., Frankel M. (1908) Die Muskeln des menschlichen Armes. In: von Møllendorff W. (ed.) *Handbuch der Anatomie des Menschen*. Bd. 2, Abt 2, Teil 2. Jena, Gustav Fischer, p. 169.
- Grüber W. (1865) Die eigenen Spanner des Ringbandes des Radius - Musculi tensori proprii ligamenti radii – bei dem Menschen. *Arch. Anat. Physiol. Wissenschaftl. Med.*, p. 377-391.
- Hast M.H., Perkins R.E. (1986) Secondary tensor and supinator muscles of the human proximal radio-ulnar joint. *J. Anat.* 146: 45-51.
- Martin B.F. (1959) The annular ligament of the superior radio-ulnar joint. *J. Anat.* 52: 473-482.
- Paraskevas G., Tzaveas A., Natsis K., Kitsoulis P., Spyridakis I. (2008) Failure of palmaris longus muscle duplication and its clinical application. *Folia Morphol.* 67: 150-153.

-
- Savas A. (1961) Human Anatomy. Vol. 2. Spyropoulou, Athens, p. 703.
- Sklavounos G. (1926) Human's Anatomy. Vol. 1, 3rd edn. Tarousopoulou, Athens, p. 637.
- Toldt C. (1928) An Atlas of Human Anatomy for Students and Physicians. Vol. 1, 2nd edn. Macmillan Co, New York.
- Williams P., Warmick R., Dyson M., Bannister L. (1989) Gray's Anatomy. 37th edn. Churchill Livingstone, Edinburgh, p. 624.